

# Dressler's like pericarditis with pericardial effusion is the presenting feature of infective endocarditis

Biswajit Majumder<sup>1</sup>, Sharmistha Chatterjee<sup>2</sup>, Rakesh Sarkar<sup>1</sup>, Pritam Kumar Chatterjee<sup>1</sup>

<sup>1</sup>Department of Cardiology, R. G. Kar Medical College and Hospital, Kolkata, India.

<sup>2</sup>Department of Biochemistry, College of Medicine and Sagor Dutta Hospital, Kolkata, India.

**Corresponding Author:** Biswajit Majumder

Department of cardiology, RG KAR Medical College and Hospital, Kolkata, India.

**Email:** majumderbiswajit1972@gmail.com

## Abstract

**Summary:** Infective Endocarditis (IE) being primarily the disease of valves and endocardium may occasionally be complicated with pericardial involvement in the form of pericarditis and pericardial effusion (PE). Pericarditis may be observed incidentally at the time of diagnosing IE and rarely does it remain the presenting feature of IE. The pericardial effusion may be attributed to ruptured aortic abscess extending into the pericardial space, autoimmune reaction, renal failure, HIV and congestive heart failure (CHF). Here we are presenting a 42 year old male having IE with vegetation in both mitral and aortic valve along with large sterile pericardial effusion was treated successfully by the medical therapy alone with favorable outcome. IE presenting with large exudative pericardial effusion being treated without any surgical intervention with substantial resolution of effusion has not been reported so far in medical literature.

**Key words:** Infective endocarditis; Dressler's; pericarditis; pericardial effusion.

DOI: <http://dx.doi.org/10.3126/njh.v15i1.19716>

## Introduction

Bacterial Endocarditis is a complex disease sometimes presenting like systemic disease beyond its affection of mere cardiac valves.<sup>1</sup> Rarely it may be complicated by pericarditis with pericardial effusion and very unusually large pericardial effusion. However, data are conspicuous regarding the occurrence and evaluation of pericardial effusion in background of infective endocarditis.

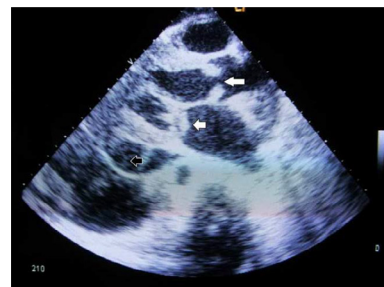
Here we present a case of 42 year old male presenting with pericarditis with large sterile pericardial effusion in association with both mitral and aortic valve vegetation with positive *Staphylococcus aureus* in blood culture although in absence of proved infective agent of pericardial fluid and treated successfully by medical management.

## Case report

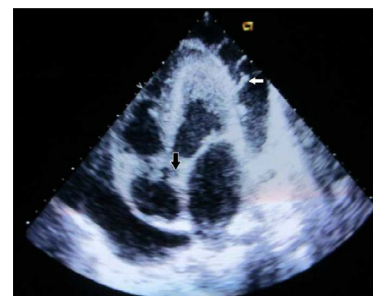
A 42 year old male patient was referred to our Cardiology OPD from Medicine Department with precordial pain for last 3 days preceded by fever for last 7 days along with the shortness of breath and dry cough for last 7 days. Chest pain was pleuritic in nature and associated with change of posture.

At the time of admission in our department, patient was having high grade fever with tachycardia (pulse-120/min), BP-104/50mmHg, tachypnea (RR-30/min) and mild pallor. On auscultation, a harsh triphasic pericardial rub throughout the precordium, along with early diastolic murmur aortic area, a systolic murmur of grade 4 and a mid-diastolic murmur with rumbling quality in mitral area were found. There was coarse bilateral crepitation on chest. The Chest X-Ray was showing gross cardiomegaly with evidence of pulmonary hypertension and pulmonary oedema. Electrocardiogram was suggestive of sinus tachycardia, features of left atrial enlargement and electrical alternans. On echocardiography there was dilated Left Ventricular and Left Atrial cavity (left ventricular end diastolic diameter 60mm, left atrial diameter 46mm and left ventricular ejection fraction around 65%), Mean gradient across mitral valve was 14mmHg, severe Mitral Regurgitation and severe Aortic Regurgitation with moderate Aortic Stenosis with one large sized

vegetation of 12x8mm in mitral [Fig.1] and two such attached to aortic valves the larger of which measuring 11x10mm [Fig.2]. There was a large pericardial effusion measuring fluid width of 22mm posteriorly [Fig.1], 14mm antero-lateral and 12mm along inferior surface [Fig.2].



**Fig 1:** 2D Echo-parasternal long axis view showing vegetation in aortic and mitral valve position (as shown by white arrowheads) & pockets of pericardial effusion along posterior wall (as shown by black arrowhead)



**Fig 2:** 2D Echo-apical four chamber view showing strands in the anterolateral pockets of pericardial effusion (denoted by white arrowhead) & vegetation in the aortic valve position (denoted by black arrowhead)

Blood report showed Total Leukocyte Count-16,000/

cmm, Hemoglobin-6.5gm%, platelet 1,20,000/cmm. Liver Function Test and renal function test were within normal limit. Methicillin resistant Staphylococcus aureus was positive in blood culture. Pericardial fluid was containing high protein content (4gm/dl) and white blood cell count 500/cmm predominantly lymphocytes but did not reveal any infective etiology of bacterial or fungal culture or by PCR analysis. No rising titre of ASO was noted. Serum ANA, Anti ds-DNA, ANCA and anti-CCP all came to be negative. Sputum for acid fast bacilli and blood for HIV were negative.

Patient was initially treated with intravenous ceftriaxone and amikacin and after blood culture report, it was replaced by intravenous vancomycin and continued for 4 weeks. Patient symptomatically improved with treatment with complete resolution of pericardial effusion after one month and reduction of the vegetation size. No aspirin or colchicines were used. In next 6 months follow up patient has been doing well and does not have any recurrence of symptom.

### Discussion:

Annual incidence of IE is 4–10 per 100000 population, and it is slightly more common in men; despite sophisticated diagnostic and therapeutic techniques, mortality remains high, at 1/100000 per year.<sup>2,3</sup> Though infective endocarditis is not a very common cause for fever in community, people who are having some congenital heart disease with either cyanotic disease or shunt lesion and regurgitant valve lesion are prone to develop the disease. Rarely IE involves the pericardium in the form of pericarditis and pericardial effusion, particularly a large one or cardiac tamponade being a very uncommon finding<sup>4</sup>.

The pericardial effusion receives less attention than other findings such as location, size, or mobility of vegetation, leaflet perforation and severity of valve regurgitation<sup>4</sup> The cause of PE in IE may be rupture of periannular abscess into pericardial space, fistula formation, suppurative pericarditis by direct extension of organism, renal failure, CHF, autoimmune etiology or relapse of rheumatic fever and HIV per se etc<sup>5</sup>. As far as the literature goes it has been noted that aortic valve involvement in IE is commonly associated with large pericardial effusion in presence of Staph aureus infection detected in blood culture and pericardial fluid whereas right sided valve involvement is mostly responsible for mild to moderate pericardial effusion<sup>4,5</sup>.

In our patient, the pericardial effusion was disproportionately large and exudative as opposing that of CHF although no organism was detected in pericardial fluid. There was no evidence of fistulous communication in between aorta and intrapericardial space i.e. neither rupture sinus of Valsalva into intrapericardial space nor any periannular abscess extension in pericardial cavity. The normal renal function test rules out the possibility of pericardial effusion secondary to renal failure in this situation. The autoimmune markers and ASO titre dynamics essentially exclude the concomitant connective tissue disorder like Rheumatoid Arthritis and Systemic Lupus Erythematosus and relapse of Rheumatic Fever respectively.<sup>6</sup>

Hence some possibility of Dressler's syndrome like autoimmune pericardial effusion is considered excluding all other etiology in our case. Very few case reports are there in literature where some idiopathic pericardial effusion with bacterial infective endocarditis was suspected to be autoimmune in nature like Dressler syndrome<sup>7,8</sup>.

The unique characteristics in our case is the involvement of

both mitral and aortic valve having large sized infective vegetation along with large exudative pericardial effusion which was sterile in nature was treated by medical management (Intravenous antibiotics and heart failure therapy) successfully without any invasive/surgical intervention with substantial subjective and objective improvement of patient.

### Conclusion:

Though pericardial effusion in infective endocarditis is mostly due to direct extension of the abscess into the pericardial space, in rare instances, the effusion may be due to a Dressler's like autoimmune process which may completely subside with medical therapy.

### References:

1. Alexandra Sousa et al. An atypical presentation of infective endocarditis, Portuguese Journal of Cardiology. 2012;31[12]:829-832. <https://doi.org/10.1016/j.repc.2012.04.015>
2. Fonager K, Lindberg J, Thulstrup AM. Incidence and short-term prognosis of infective endocarditis in Denmark, 1980–1997. *Scand J Infect Dis.* 2003; 35:27–30. <https://doi.org/10.1080/0036554021000026993>
3. Walpot J, Blok W, van Zwienen J. Incidence and complication rate of infective endocarditis in the Dutch region of Walcheren: a 3-year retrospective study. *Acta Cardiol.* 2006; 61:175-81. <https://doi.org/10.2143/AC.61.2.2014331>
4. Miyake, M., C. Izumi, K. Kuwano, G. Honjo and H. Matsutani, 2010. Cardiac tamponade during transesophageal echocardiography in a patient with infective endocarditis. *J. Echocardiography*, 8: 25-27. <https://doi.org/10.1007/s12574-009-0023-3>
5. Regueiro A et al Risk factors for pericardial effusion in native valve infective endocarditis and its influence on outcome, *Am J Cardiol.* 2013 Nov 15;112[10]:1646-51. doi: 10.1016/j.amjcard.2013.07.024. Epub 2013 Sep 19. <https://doi.org/10.1016/j.amjcard.2013.07.024>
6. M.A. Hamza, L. Allam. Libman-Sacks endocarditis, and other echocardiographic findings in systemic lupus erythematosus: Case report. Available online 30 June 2012; 2012 Egyptian Society of Cardiology.
7. Ribeiro P, Shapiro L, Nihoyannopoulos P, Gonzalez A, Oakley CM. Pericarditis in infective endocarditis. *Eur Heart J.* 1985 Nov;6[11]:975-8. <https://doi.org/10.1093/oxfordjournals.eurheartj.a061797>
8. Chang et al, Infective Endocarditis of the Aortic Valve Complicated by Massive Pericardial Effusion and Rupture of a Sinus of Valsalva into the Right Atrium. *Journal of the American Society of Echocardiography* . 2004;17:910-2. <https://doi.org/10.1016/j.echo.2004.04.016>

### Acknowledgments:

We are grateful to Dr. K. K. Mitra, Head of the Dept, Cardiology, R.G.Kar MCH and Dr. Jayitri Mazumdar, Senior Resident in dept of Pediatrics, Calcutta National Medical College for their technical support and patronizing the case for the publication

**Cite this article as:** Biswajit Majumder, Sharmistha Chatterjee, Rakesh Sarkar, et.al. Dressler's like pericarditis with pericardial effusion is the presenting feature of infective endocarditis. *Nepalese Heart Journal* 2017;12(2): 43-44. <http://dx.doi.org/10.3126/njh.v15i1.19716>