

## Case Report

# Conjunctival Kaposi's sarcoma as the initial manifestation of acquired immunodeficiency syndrome

Rodriguez CI, Cordova JM  
Plaza Mar Caspio, 4 28821- Coslada, Madrid, Spain

### Abstract

**Introduction:** Kaposi's sarcoma is a common neoplasm in patients with acquired immunodeficiency syndrome (AIDS). Its presentation as an initial manifestation of AIDS is very rare. **Objective:** To report a rare case with Kaposi's sarcoma as an initial manifestation of AIDS. **Case:** We report the case of a 37-year-old man who was a parenteral drug addict, HIV seropositive and was not under any treatment with a conjunctival lesion which was diagnosed as Kaposi's sarcoma after surgical resection. Conjunctival Kaposi's sarcoma is present frequently in HIV patients and lesions may be mistaken with other conjunctival lesions.

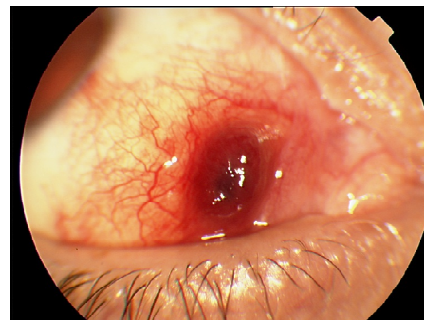
**Keywords:** Kaposi's sarcoma, conjunctival neoplasm, AIDS

### Introduction

Kaposi's sarcoma (KS) is a common neoplasm in patients with acquired immunodeficiency syndrome (AIDS) (Shuler et al, 1989). Its presentation as an initial manifestation of AIDS is very rare.

To date, there have been reported four cases of conjunctival KS as the first manifestation of AIDS (Hummer et al, 1993; Kurumety et al, 1995; Schmid et al; 2003; Curtis et al 2005).

A 37-year-old man presented with a conjunctival mass of one month duration. He was a parenteral drug-addict and was HIV seropositive and was not under any treatment for his illness. On examination, the best-corrected visual acuity was 20/20 in the right eye and 20/200 in the left (amblyopic). The slit lamp examination revealed a nodular, painful, red mass with a small depression at the center in the bulbar conjunctiva (Fig 1). The cornea, anterior chamber, iris, lens and retina were normal in both the eyes.



**Figure 1:** Red, nodular conjunctival mass

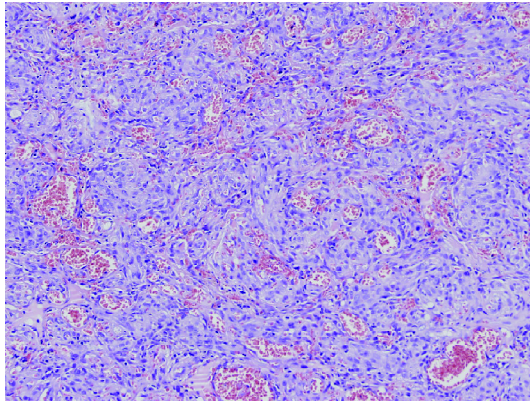
The first differential diagnoses included capillary haemangioma, pyogenic granuloma and Kaposi's sarcoma.

His CD4 count at the time of presentation was 135  $\mu$ l and the viral load was 8700. He had no other AIDS-related findings of any illnesses.

Surgical resection of the ocular lesion was carried out with care because of a possible HIV infection. We included a Tenon capsule with a 2 mm safe margin.

Histopathology showed the morphology of KS with proliferating spindle cells and numerous vascular

slits, surrounded by a single layer of endothelium (Figure 2).



**Figure 2:** Proliferating spindle cells and numerous vascular slits surrounded by a single layer of endothelium.

At follow-up 26 months later, there was no evidence of tumour recurrence.

### Discussion

Ocular involvement in developed AIDS is seen in 20 % of patients and 7 % can have conjunctival lesions (Shuler et al, 1989). KS related with AIDS in ophthalmic practice is found rarely as the first clinical manifestation.

In other studies, ocular involvement is seen in 70 % of AIDS patients. It mainly presents as cotton-wool spots, cytomegalovirus chorio-retinitis and KS in the eyelids and conjunctivae (Kurumety et al, 1995). The conjunctival lesions are more frequently found in the inferior fornix (Shuler et al, 1989).

Lesions can be clinically confused with pyogenic granuloma, subconjunctival haemorrhage, cavernous haemangioma, conjunctival cysts, inflamed pinguecula or bacillary angiomatosis from *Bartonella henselae* infection.

Current studies suggest that Kaposi's sarcoma is not a true tumour but a dys-regulation of an inflammatory response. It is associated with infection by human herpes virus 8, and the lesion's growth depends on numerous cytokines and growth factors, including the *tat* gene from the HIV genome (Antman

et al, 2000; Minoda et al, 2006).

There are several treatment modalities available for patients with Kaposi's sarcoma, including chemotherapy, immunotherapy, radiation therapy, cryotherapy and excision (Brun et al, 1997).

Heimann et al reported a case of regression after treatment with 5 mg/day bleomycin injections intramuscularly on three consecutive days every two weeks (Heimann et al; 1997).

Hummer published a case of regression with subconjunctival injection of 0.5 ml of 3 million IU of interferon  $\alpha$ -2<sup>a</sup> (Hummer et al, 1993). However, Shuler (1989) considers that treatment may be unnecessary and observation would be appropriate because of the slow growing of Kaposi's sarcoma.

### Conclusion

Conjunctival Kaposi's sarcoma can be the first clinical manifestation in HIV patients and lesions may be mistaken with other conjunctival lesions. We suggest that the ophthalmologists consider KS among the differential diagnoses of ocular neoplasms in HIV patients.

### References

- Antman K, Chang Y. Kaposi's's sarcoma. *N Engl J Med* 2000; 342(14):1027-38.
- Brun SC, Jakobiec FA. Kaposi's's sarcoma of the ocular adnexa. *Int Ophthalm Clin* 1997; 37(4):25-38
- Curtis TH, Durairaj VD. Conjunctival Kaposi's Sarcoma as the initial presentation of human immunodeficiency virus infection. *Ophthalm Plast Reconstr Surg* 2005; 21(4):314-5.
- Heimann H, Kreusel KM, Foerster MH, Husak R, Orfanos CE. Regression of conjunctival Kaposi's sarcoma under chemotherapy with bleomycin. *Br J Ophthalmol* 1997; 81(11):1019-20.
- Hummer J, Gass JD, Huang AJ. Conjunctival Kaposi's sarcoma treated with interferon alpha-2a. *Am J Ophthalmol* 1993; 15:116:502-3.



Kurumety UR, Lustbader JM. Kaposi's sarcoma of the bulbar conjunctiva as an initial clinical manifestation of acquired immunodeficiency syndrome. Arch Ophthalmol 1995; 113 (8):978.

Minoda H, Usui N, Sata T, Katano H, Serizawa H, Okada S. Human herpesvirus-8 in Kaposi's sarcoma of the conjunctiva in a patient with AIDS. Jpn J Ophthalmol 2006; 50 (1):7-11.

Schmid K, Wild T, Bolz M, Horvat R, Jurecka

W, Zehermayer M. Kaposi's sarcoma of the conjunctiva leads to a diagnosis of acquired immunodeficiency syndrome. Acta Ophthalmol Scand 2003; 81(4):411-3.

Shuler JD, Holland GN, Miles SA, Millar BJ, Grossman I. Kaposi's Sarcoma of the Conjunctiva and Eyelids associated with the acquired immunodeficiency syndrome. Arch Ophthalmol 1989;107(6):858-62.

**Source of support: nil. Conflict of interest: none**