

Case report

Use of amniotic membrane and autologous serum eye drops in Mooren's ulcer

Lavaju P¹, Sharma M¹, Sharma A², Chettri S³

¹Departments of Ophthalmology and ³Obstetrics and Gynecology

BP Koirala Institute of Health Sciences, Dharan, Nepal

²Biratnagar Eye Hospital, Biratnagar, Nepal

Abstract

Introduction: The management of Mooren's ulcer can be a challenge for clinicians. **Objective:** To report a case of Mooren's ulcer treated with amniotic membrane transplantation supplemented with autologous serum eye drops. **Case report:** A 22-year-old male presented with history of pain, redness, watering and diminution of vision of the right eye for one year. Examination of his eyes revealed the best corrected visual acuity (BCVA) of 6/60 and 6/6 in his right and left eyes respectively. Slit-lamp examination of the right eye showed a peripheral ulcer extending from 2'0 to 11'0 clock positions with peripheral thinning and the features suggestive of Mooren's ulcer. The condition did not improve with topical steroids and cyclosporine A eye drops. Therefore, 360 degree conjunctival peritomy with cauterization of the base was performed. Since there was no obvious improvement, the amniotic membrane transplantation was done with supplementation of autologous serum eye drops 20% four times a day. The patient showed symptomatic improvement in a week. There was cessation of the progression of the ulcer and decreased vascularization. One month later, a small corneal perforation was noted and was managed well with cyanoacrylate glue and bandage contact lens application. At nine months of follow up, the patient was symptomatically better, the ulcer had healed, the vascularization had decreased and the anterior chamber was well formed. **Conclusion:** Amniotic membrane transplantation showed to be promising in treatment of Mooren's ulcer refractory to immunosuppressive therapy. Addition of autologous serum eye drops seems to be an effective supplementary therapy.

Key words: Mooren's ulcer, amniotic membrane transplantation, autologous serum eye drops, peripheral corneal ulcer

Introduction

Mooren's ulcer is a chronic peripheral ulcerative keratitis which can progress circumferentially and centrally without any associated scleritis. The aetiology of Mooren's ulcer remains uncertain. An autoimmune mechanism has been postulated. The

ulcer poorly responds to conventional treatment. Various treatment modalities have been proposed for its management in the literature. Use of amniotic membrane and autologous serum eye drops have been reported to be effective where conservative management fails (Chen et al, 2004; Mavranakas et al, 2007).

We report a case of unilateral Mooren's ulcer that was unresponsive to conservative treatment but

Received on: 09.05.2012 Accepted on: 12.11.2012

Address for correspondence: Dr Poonam Lavaju, MD
Associate Professor, Department of Ophthalmology, BP
Koirala Institute of Ophthalmology, Dharan-18, Sunsari, Nepal.
Tel: +977-25-521017
E-mail: drpoonamlavaju@yahoo.com

responded well to amniotic membrane transplantation and autologous serum eye drops.

Case report

A 22-year-old male presented with history of pain, redness, watering and diminution of vision of the right eye for a one-year duration. There was no history of trauma in the right eye. He had been receiving topical antibiotics and steroid eye drops q.i.d. in the right eye for one year.

On examination, the BCVA OD was 6/60 and that of OS 6/6. The examination of the right eye revealed a ciliary congestion. There was a presence of a soft contact lens in place which on removal showed a peripheral corneal ulcer extending from 2 O'clock to 11 O'clock positions with rolled out edges of the ulcer with superficial vascularisation. At 7 O'clock position, there was presence of an adherent leucoma suggestive of a previous perforation. The anterior chamber was quiet. Other findings were within normal limits (Figure 1). The examination of the left eye was normal (Figure 2).

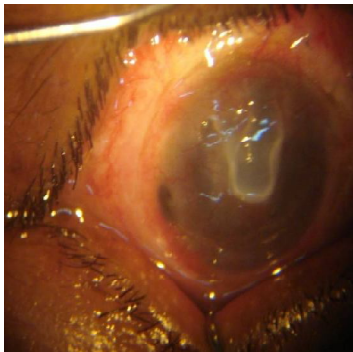


Figure 1: Photograph of the right eye showing peripheral ulcer with island of cornea left.

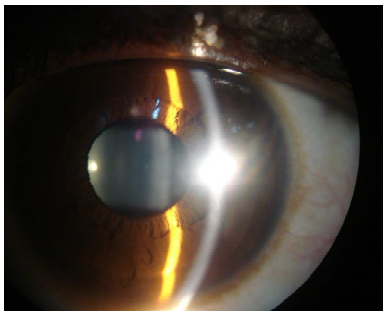


Figure 2: Photograph of the left eye

The laboratory investigations carried out showed: Hb - 12.4 mg/d, TC - 12,200/mm³, ESR - 22mm in the first hour, platelets - 3,66,000/mm³. Anti-nuclear antibody- 0.96, VDRL test – non-reactive, CXRay – normal, Random blood sugar- 89 mg/dl and the Mantoux test - normal. The ultrasonography B scan of the posterior segment of OD was normal.

On the basis of the clinical findings and laboratory investigations, Mooren's ulcer of the right eye was considered as a diagnosis of exclusion. The patient was commenced on 0.05 % cyclosporine A eye drops b.d, 1% atropine eye drops t.d.s, tear substitute, and oral steroids. Since no significant improvement was seen even after a week, 360 degree conjunctival peritomy with cauterization of the base was carried out. There was, however, no remarkable improvement. Therefore, the amniotic membrane transplantation was performed followed post-operatively by the autologous serum eye drops 20% four times a day (Figure 3). There was no progression of the ulcer and the vascularization was found to be decreased within a week after initiation of the treatment.

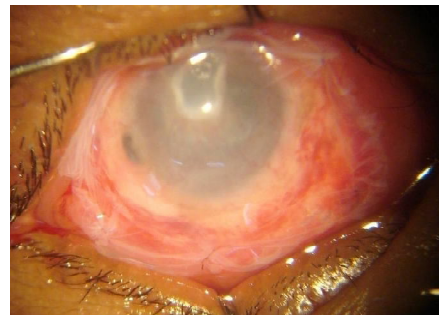


Figure 3: Intra- operative photograph showing placement of fresh amniotic membrane

At one month follow up, except for a perforation noted at 12 O'clock position the ulcer was static in the right eye (Figure 4). A bandage contact lens was applied after application of cyanoacrylate glue (Figure 5, 6). At nine months of follow up, the patient was symptomatically better, the ulcer had healed, the vascularization had decreased and the anterior chamber was well formed (Figure 7).

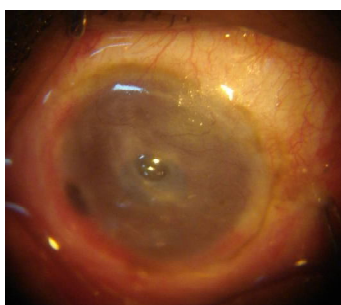

Figure 4: Photograph at one month follow-up showing perforation at 12 o'clock position and shallow anterior chamber.

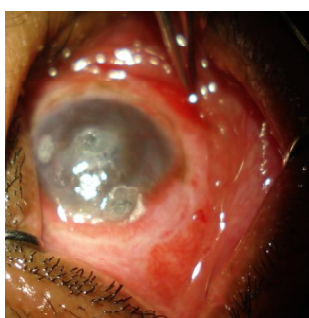

Figure 5: Intraoperative photograph showing application of cyanoacrylate glue and bandage contact lens

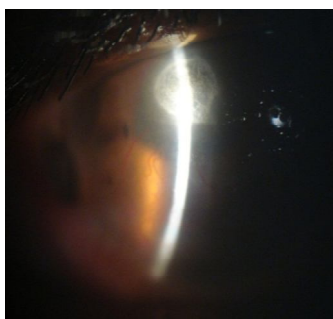


Figure 6: The photograph showing formed anterior chamber next after application of cyanoacrylate glue and bandage contact lens

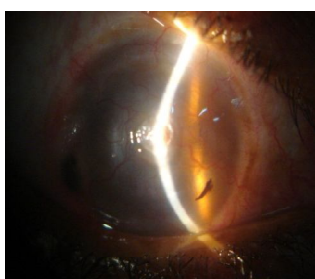


Figure 7: The photograph at nine months follow up showing decreased vascularization and healed ulcer

Discussion

Mooren's ulcer is an idiopathic non-infective, progressive, painful ulcerative keratitis that initially affects the peripheral cornea and may spread circumferentially and then centrally. Its clinical course is variable. Treatment of Mooren's ulcer is very challenging because of its poor response to any conventional therapy. Various treatment modalities have been described in the literature. The results of treatment, however, are usually not satisfactory.

A stepwise approach has been proposed for the management of Mooren's ulcer. Recent studies have postulated Mooren's ulcer to be an autoimmune disease directed against a specific target molecule in the corneal stroma, probably triggered in genetically susceptible individuals by one of several possible provocateurs (Gottsch et al, 1999; Taylor et al, 2000).

Immunosuppressive therapy has been shown to be increasingly successful in patients unresponsive to conventional treatment. Conjunctival recession and excision was shown to be an effective temporary surgical treatment because it decreased the exposure of corneal stroma antigen to systemic circulation (Chen et al, 2004).

In our case, the ulcer was refractory to conservative treatment, even with the use of topical 0.05% cyclosporine A. He underwent a 360 degree conjunctival peritomy which too was not very effective. Ultimately, he underwent amniotic membrane transplantation, after which the inflammatory blood vessels regressed and there was cessation in progression of the ulceration.

Amniotic membrane (AM) has been used in ophthalmology for repairing corneal perforation or descemetocoeles, corneal ulcers and persistent epithelial defects (Solomon et al, 2002).

Besides its several advantages, such as wound-healing promotion and anti-inflammatory effects, the AM can be a biologic substrate membrane. The AM transplantation has been reported to be useful in treating Mooren's ulcer. Following its use the inflammatory symptoms are reduced in most cases,



and recurrent ulcers are not observed (Kubo et al, 2001; Spelsberg et al, 2007).

Because of its various properties and the presence of useful substrates, autologous serum has been tried in the treatment of Mooren's ulcer.

Mavrakarnas et al (2007) used 20% autologous serum eye drops in a 67-year-old man who did not respond to the initial treatment (AM, corticosteroid and cyclosporin therapy). Re-epithelialization occurred and the corneal deficit improved after the introduction of autologous serum eye drops. So, he concluded that autologous serum seemed to be an effective supplementary therapy in Mooren's ulcer by providing enhanced conditions for epithelial healing and by modulating the corneal inflammatory and immune response (Mavrakarnas et al, 2007)

In another study, three patients with unilateral Mooren's ulcer in different stages of the disease, which deteriorated despite high-dose systemic cyclosporin A or with topical cyclosporin A 2%, were treated with AMT. Improvement was observed in all the patients. Due to the anti-inflammatory potential of amniotic membrane, coverage by AM seems to trigger a therapeutic turnaround in cases of Mooren's ulcer which do not heal with intensive immunosuppressive regimens alone (Spelsberg & Sundmacher, 2007).

In a prospective, non-comparative case series of 10 eyes in eight patients with Mooren's ulcer, failure to conservative therapy with antibiotics and topical steroids, of five with recurrent ulcer were treated with single and multi-layered amniotic membrane transplantation. On an average follow-up of 10 months, the ulcer improved. It was concluded that the amniotic membrane transplantation may be considered an effective procedure for severe cases of Mooren's ulcer instead of conjunctival resection or lamellar keratoplasty (Chau, 2006).

Our patient did not respond to the initial treatment, but re-epithelialization occurred and the corneal deficit improved after the amniotic membrane transplantation and the administration of autologous serum eye drops.

Conclusion

Amniotic membrane transplantation and simultaneous administration of autologous serum eye drops have shown to be promising in treating the Mooren's ulcer refractory to immunosuppressive therapy. A large series of cases is required to prove the efficacy of this combination.

References

- Chau HTM (2006). Amniotic membrane transplant heals Mooren's ulcers. *Cornea/External Disease. Ocular Surgery News U.S. edition.* <http://www.healio.com/ophthalmology/cornea-external-disease/news/print/ocular-surgery-news/%7Bff1e8769-74a6-4ea1-bb6c-4ca601c0e5e4%7D/amniotic-membrane-transplant-heals-moorens-ulcers> (Accessed on 03.04.2012).
- Chen K H, Hus W M, Liang C K (2004). Relapsing Mooren's ulcer after amniotic membrane transplantation combined with conjunctival auto-grafting. *Ophthalmology*; 111: 792–795.
- Kubo M, Sonoda Y, Muramatsu R, Usui M (2001). Immunogenicity of human amniotic membrane in experimental xenotransplantation. *Invest Ophthalmol Vis Sci*; 42:1539–46.
- Gottsch JD, Li Q, Ashraf F, et al (1999). Cytokine-induced calgranulin C expression in keratocytes. *Clin Immunol*; 91:34–40.
- Mavrakarnas NA, Dosso R K (2007). Autologous serum application in the treatment of Mooren's ulcer. *Klin Monatsbl Augenheilkd*; 224: 300–302.
- Solomon A, Meller D, Prabhasawat P et al (2002). Amniotic membrane grafts for non-traumatic corneal perforations, descemetocelles and deep ulcers. *Ophthalmology*; 109:694–703.
- Spelsberg H, Sundmacher R (2007). Amniotic membrane transplantation and high-dose systemic cyclosporine A for mooren's ulcer. *Klin Monatsbl Augenheilkd*; 224: 135–139.
- Taylor CJ, Smith SI, Morgan CH, et al (2000). HLA and Mooren's ulceration. *Br J Ophthalmol*; 84:72–5.

Source of support: nil. Conflict of interest: none declared