

## Case report

# Monocanalicular repair using angiocatheter tube as a stent in a young patient in a rural setup

Tathe S, Dhaytadak P

<sup>1</sup>Department of Ophthalmology, Pravara Institute of Medical Sciences and Rural Medical College, Loni, Ahmednagar, Maharashtra, India

---

### Abstract

**Introduction:** Ocular injuries commonly involve the lacrimal system. **Case:** A 14-year-old male had an eyelid injury with a canalicular tear. An angiocatheter tube was used as a stent for canalicular reconstruction. The focus of this report is on the method used, as well as the material for the repair in a rural hospital. **Conclusion:** Angiocatheter tube can be a suitable alternative to silicone tube for canalicular repair.

**Key-words:** canalicular reconstruction, angiocatheter tube

---

### Introduction

Injuries to the eye resulting in lid tears or lacerations also involve the canalicular system in many cases. These types of injuries are more common in children and young adults (Herzum, 2001; Reifler, 1991 and Naik, 2008). This Canalicular system laceration need urgent primary microsurgical repair along with stenting to maintain its patency (Struck, 2009). Out of the various methods available, the most commonly advocated were by using a pigtail probe or with a bicanalicular stent and silicone tubes. However, monocanalicular involvement needs a different approach for its repair. Since these stents are expensive and their use require much surgical experience, a suitable and/or cheaper alternative would be useful in cases where the stent is not available. Here, we present a case report of canalicular reconstruction using an angiocatheter tube as a stent in a young patient which had a satisfactory outcome.

### Case report

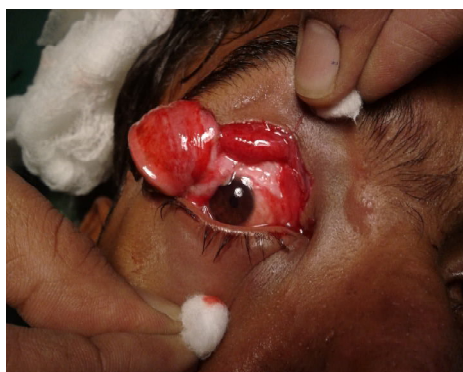A 14-year-old male sustained trauma to the right eye by an iron rod while playing. On examination, there was a right upper eyelid avulsion involving the medial 2/3rd of the lid and canaliculus (Figure 1). The punctum was intact. The anterior segment was normal without any intraocular involvement. A meticulous microscopic repair was done under general anaesthesia. The torn edges of the lid were identified. The superior canaliculus was probed with Bowman's lacrimal probe. A 26G angiocatheter was used to cannulate the torn canaliculus through the upper punctum. The stellate of the angiocatheter was withdrawn; the plastic tube was left in situ and cut near the punctum parallel to the lid margin to prevent post-operative irritation (Figure 2 a,b). A fixation suture was passed through the tube and the eyelid skin with a 4/0 prolene to prevent its extrusion. The levator palpebrae superioris and orbicularis oculi muscle fibers were identified and sutured with 6/0 vicryl and the skin with 5/0 silk.

The eye was patched and bandaged. The tube was left in situ and the wound was seen to be well approximated on the postoperative day 1. The patient was discharged on postoperative day 4 with

---

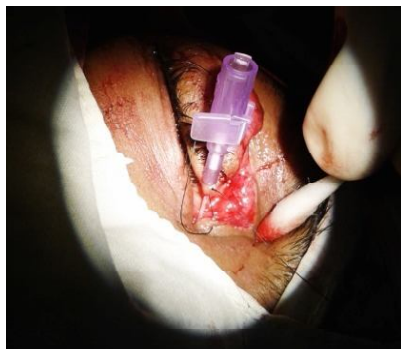
Received on: 24.05.2012 Accepted on: 12.10.2012  
Address for correspondence: Dr Sandeep Tathe, Department of Ophthalmology, Pravara Institute of Medical Sciences and Rural Medical College, Loni 413736. District: Ahmednagar, Maharashtra, India  
Tel: +91-9823531826  
E-mail: sandeepatathe21@gmail.com

systemic as well as local antibiotic coverage. On the first follow up on postoperative day 10, the tube was in situ (Figure 3). In the 12th week after the surgery, the tube was removed. The patient had a patent canaliculus on syringing, with mild traumatic ptosis. He had no complaint of watering.

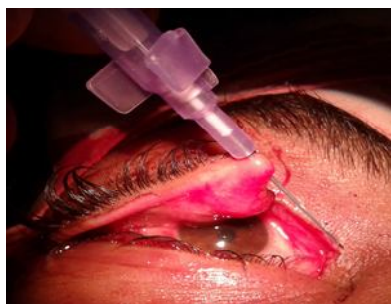

**Figure 1:** RE upper lid avulsion involving canaliculus

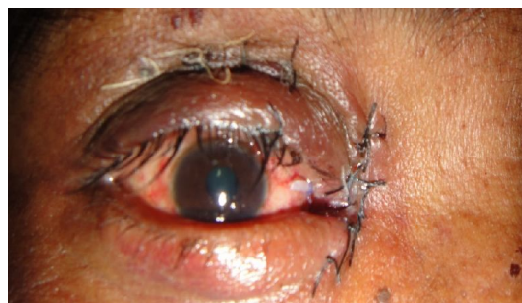**Figure 2: Intraoperative photographs showing**



**Figure 2(a):** 26G Angiocatheter cannula with sharp end of the needle, was passed through the cut ends



**Figure 2 (b):** Stellate removed, cut ends of the canaliculus were approximated



**Figure 3:** Post operative (Day 10) photograph-tube in situ (arrow).

### Discussion

Lid tears are commonly associated with involvement of the lacrimal drainage system. The upper canaliculus is often lacerated as it is in a particularly vulnerable location (Wulc, 1991).

In canicular anastomosis, the key to the success is stenting of the lacerated canaliculus. It supports the canicular alignment which is a prerequisite for mucosal healing and, thus, maintains its patency after surgery.

Epiphora is reported to be more common when no canicular stent is placed at the time of surgical repair. Controversy still exists regarding the repair of a single-lacerated canaliculus. However, considering the predominance of the younger population and the long term morbidity in the form of eyelid malposition, epiphora, ocular irritation, dermatitis, infection like dacryocystitis, it may be prudent to repair all canicular lacerations even if a single canaliculus is involved (Herzum 2001; Reifler, 1991 & Naik 2008).

Over the last few years, various surgical techniques and stents have been described for the repair of canicular lacerations, which are expensive and require much surgical experience (Reifler 1991 and Naik, 2008). Since the angiocatheter tube is easily available, cheap, biocompatible and well tolerated by patients with satisfactory outcome after surgery, as in our case, it can be an efficient alternative to the silicon tube.

Early repair and intubation with stents are crucial in achieving a good success rate after the



reconstruction of the lacrimal drainage system. Intubation of the canaliculus is crucial for the prevention of stenosis, and repair of the lacrimal drainage system should be performed (Ani Sreedhar MS 2011). There is no consensus regarding the exact duration for which the canaliculus should remain stented to achieve long-term patency (Romano PE 1986). Conlon and associates (1994) designed an animal model to study the histology of canalicular lacerations following intubation, and concluded that the optimum time for removal of the tube was 12 weeks.

The use of angiocatheter tube for canalicular injury achieved anatomical as well as functional success in our patient. Extrusion of the angiocatheter tube occurs within one month, necessitating close initial follow-up.

### Conclusion

The use of an angiocatheter tube as a stent is a simple, efficient, inexpensive and feasible alternative to the use of a silicon tube in the repair of canalicular lacerations in a rural setting.

### References

Conlon MR, Smith KD, Cadera W, Shum D, Allen LH (1994). An animal model studying

reconstruction techniques and histopathological changes in repair of canalicular lacerations. *Can J Ophthalmol*; 29:3– 8.

Herzum H, Holle P, Hintschich C (2001). Eyelid injuries: epidemiological aspects. *Ophthalmology*; 98:1079–1082.

Naik M, Kelapure A (2008). Management of canalicular lacerations: epidemiological aspects and experience with mini-monoka monocanicular stent. *Am J Ophthalmol*; 145:375–380.

Reifler DM (1991). Management of canalicular laceration. *Surv Ophthalmol*; 36:113–132.

Romano PE (1986). Single silicone intubation for repair of single canaliculus laceration. *Ann Ophthalmol*; 18:112–113.

Sreedhar A, Varghese TA (Dec.2011) Canalicular tear repair. *Kerala Journal of Ophthalmology*; 23 (4) : 342-344.

Struck HG (2009). Lacrimal system lacerations and their surgical repair. *Ophthalmology*; 106(3):223-8.

Wulc AE, Arterberry JF (1991). The pathogenesis of canalicular laceration. *Ophthalmology*; 98:1243–1249.

Source of support: nil. Conflict of interest: none declared