

Original articles

Indications for destructive ocular surgeries in Nigeria

Monsudi KF¹, Ayanniyi AA², Balarabe AH¹

¹Department of Ophthalmology, Federal Medical Centre, Birnin Kebbi, Nigeria.

²Department of Ophthalmology, College of Health Sciences, University of Abuja, Nigeria

Abstract

Introduction: Destructive ocular surgery (DOS) means eye loss. An audit of its indications would be useful in reducing its incidence. **Objective:** To determine indications for destructive ocular surgeries. **Materials and methods:** The case records (files) of all the patients who had DOS in a tertiary health facility in Nigeria from January 2004 to December 2011 were reviewed retrospectively. The information extracted include the bio data, indication for DOS, type of surgery performed and history of the use of traditional eye medications (TEM) and willingness to use an artificial eye (AE). **Results:** Thirty-seven patients had DOS. The mean age of the patients was 35.51 years (SD 21.6) and the male to female ratio was 2.1:1. Evisceration was the commonest DOS performed, in 30 eyes (81.1 %). The most common indication for DOS was intraocular infection, in 15 eyes (40.5 %), followed, among others, by trauma in 13 (35.1 %) and malignant ocular tumours in 4 (10.8 %). There was association between age and indication for DOS ($P = 0.032$). Many patients, 15 (40.5%), used TEM and most, 34 (91.9%), refused an artificial eye (AE) after surgery. **Conclusions:** The most common indication for DOS in this study was intraocular infection. Evisceration was the commonest destructive eye surgery offered.

Key-words: evisceration, enucleation, exenteration, ocular infections, traditional eye medication

Introduction

Destructive ocular surgeries (DOS) have been carried out from time immemorial and still remain a common ophthalmic procedure in most of the eye clinics worldwide. There are three types of DOS including evisceration, enucleation and exenteration.

Evisceration is the removal of the intraocular contents with or without the cornea being preserved but the sclera, optic nerve and orbital fat are preserved. Enucleation is the removal of the eyeball and optic nerve, leaving the orbital contents in place. Exenteration is the removal of the orbital contents, including the eyeball, orbital fat, extraocular muscles, and orbital bone (Etebu and Adio, 2008; André et al, 2011). The indication for these destructive

surgeries varies. Exenteration is mainly reserved for life threatening tumours (Chinda et al, 2011). Enucleation and evisceration are both useful in treating painful blind eye caused by intraocular infection and glaucoma (André et al, 2011; Chinda et al, 2011).

Before surgery, the surgeon should consider visual potential and patient psychology (Moshfeghi, 2000). The DOS is a dead end procedure with far reaching implications. Summarily, the globe is lost with its main function (vision). DOS have economic and psychological effects on the patients, their relatives and the community. Therefore, eye surgeons should holistically, especially psychologically and emotionally, prepare both patients and their relatives before the surgery.

The objective of this study was to determine the indications for DOS in our health facility with the

Received on: 18.05.2012

Accepted on: 16.11.2012

Address for correspondence: Dr Abdulkabir Ayansiji

Ayanniyi, Department of Ophthalmology,

College of Health Sciences, University of Abuja, P.M.B 117,

Abuja, Nigeria

E-mail: kfmshood@yahoo.com



view that it would be useful in planning strategies (including public health education) to reduce avoidable eye losses and associated challenges following DOS.

Materials and methods

This was a retrospective study over a period of eight years (January 2004 - December 2011) carried out in the eye unit of the Federal Medical Centre, Birnin Kebbi, Nigeria. The case records (files) of all the patients who had undergone DOS within this period were retrieved. The following information was extracted: patient’s demographic data, ocular examination findings, causes of DOS, type of surgery performed, history of the use of Traditional Eye Medications (TEM) and the willingness to use ocular prosthesis. **Statistics:** Data was double entered and analyzed by SPSS 16.0 (2006 Statistical Package for the Social Sciences, Chicago, Illinois, USA). Analysis was done using simple frequency proportions and Chi square was used to test the association between age and indication for

DOS, occupation and indication for DOS. A $P < 0.05$ was considered as statistically significant. The ethical approval to carry out this study was granted by Research Ethics Committee, Federal Medical Centre, Birnin Kebbi, Nigeria.

Results

A total of 37 patients had had DOS within the period under review. There were 27 males and 10 females with the M: F of 2.1:1. The distribution of patients by DOS included 30 (81.1%) evisceration, 4 (10.8%) enucleation and 3 (8.1%) exenteration. A major challenge following the DOS was an anophthalmic socket.

The DOS cut across different age groups with the highest occurrence (9, 24.3%) in the first decade of life (Table1). The indications for DOS included trauma (Figure 2), the commonest, (6, 16.5 %) in the first decade of life, and intraocular infection, the major cause in (7, 18.9 %) in the fifth decade of life (41 - 50 years) (Table 1).

Table 1: Frequency distribution of indications by age

Age (years)	Indication of ocular destructive surgery						Total (%)
	Trauma	IT	ET	II	PBE	Staphyloma	
0-10	6	2	0	0	0	1	9 (24.4)
11-20	2	0	0	0	0	1	3 (8.1)
21-30	2	0	0	2	0	0	4 (10.8)
31-40	1	0	0	1	2	1	5 (13.5)
41-50	0	1	0	7	0	0	8 (21.6)
51-60	2	0	1	1	0	0	4 (10.8)
61-70	0	0	0	3	0	0	3 (8.1)
71-80	0	0	0	1	0	0	1 (2.7)
Total (%)	13 (35.1)	3 (8.1)	1 (2.7)	15 (40.6)	2 (5.4)	3 (8.1)	37 (100)

IT, intraocular tumour; ET, extraocular tumour; II, intraocular infection; PBE, painful blind eye

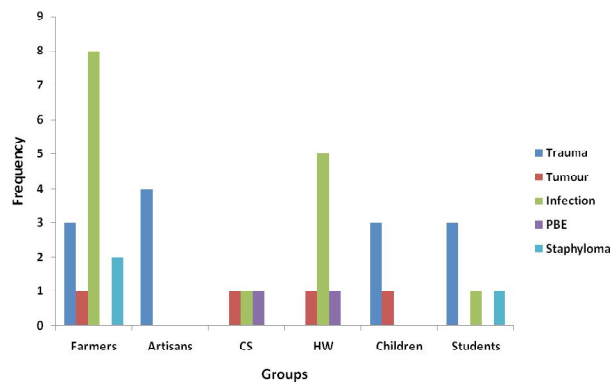


Figure 1: Indications for destructive surgeries by groups of the patients

CS, civil servants; HW, housewives; PBE, painful blind eye

Intraocular infections were found more in farmers followed by housewives (Figure 1). Histopathological evaluation was not routinely performed except in cases with suspected neoplasm. There was a histological confirmation of the cases of retinoblastoma who underwent surgery (n = 2). The histopathology report of two cases of suspected squamous cell carcinoma in an adult was not found in the case notes. There was an association between age and indications for DOS ($P = 0.032$).



Many patients (15, 40.5%) used traditional eye medication (TEM) before presenting at the hospital and most (34, 91.9%) of them refused to use artificial eye (AE) after the DOS.

Discussion

The mean age of our patients was 36.69 years, which is similar to the previous studies in Africa on DOS (Etebu and Adio, 2008; André et al, 2011; Epee et al., 2008 ; Gyasi et al, 2009). However, Bodunde et al (2005) in Nigeria reported the mean age of 29.69 ± 16.93 years among their patients. The male preponderance in our study was similar to that of other studies (Etebu and Adio, 2008; André et al, 2011; Epee et al, 2008 ; Gyasi et al, 2009; *Bodunde et al*, 2005). The most affected age group was 0 - 10 years similar to that of other studies in Cameroon (André et al., 2011) and China (Cheng et al, 2008). While the age group 0 - 10 years as the most affected (André et al, 2011; Cheng et al, 2008; Adeoye and Onakpoya, 2007) can be regarded as the first peak for DOS, a second peak among the middle-aged group or among the elderly is not rare (André et al, 2011; Cheng et al, 2008).

The commonest cause of DOS in our study was intraocular infections followed by trauma. Epee et al (2008) in their study on 32 cases of ocular mutilating surgery in Yaoundé, as well as Gyasi et al (2009) in a series of 337 eyes, reported the leading roles of infection and trauma. Trauma (43.4%) and orbito-ocular tumour (30.4%) were the leading causes of 92 DOS in Ile- Ife. In Nigeria, Bodunde et al (2005) reported trauma in 14 (48.28 %) followed by panophthalmitis in 6 (20.69 %) and malignant tumours in 4 (13.79 %) to be the most common indications for eye removal, while Chindal et al (2011) reported tumours to be responsible for the majority of DOS in their eye unit (31%) followed by endophthalmitis/panophthalmitis (30%). The high prevalence of intraocular infections as indication for DOS could be related to the practice of using harmful ocular traditional eye medication (TEM) by the rural population and self-medication among city dwellers (André et al, 2011). Intraocular

infection as an indication of DOS was common among farmers. This might be due to the use of TEM among this group. The use of TEM by the farmers has also been reported to influence the incidence of infection-related destructive procedures (Nwosu, 2005). Evisceration was the most performed destructive eye surgery in our study, which is similar to other studies (Etebu and Adio, 2008; André et al, 2011; Chinda et al, 2011; Epee et al, 2008; *Bodunde et al*, 2005; Nwosu, 2005).

Intraocular infections were more common in farmers but there was no association between occupation and indication for destructive eye surgery ($P= 0.079$). However, other factors apart from the use of TEM may predispose farmers to intraocular infections. The majority (91.9%) of the patients refused AE after surgery, indicating poor acceptance among the populace. This might be due to the religious and socio-cultural beliefs. However, this should be a subject of another study.

Conclusion

Intraocular infection and trauma were common indications for destructive ocular surgery in our study. Many patients use TEM before presenting at the hospital. We recommend supervision of children at play and public health education on harmful effect of TEM.

References

- Adeoye AO, Onakpoya OH (2007). Indication for eye removal in Ile-Ife, Nigeria. *Afr J Med Med Sci*; 36:371-5.
- André OE, Viola AD, Koki G, Oumarou A, Bella AL, Côme EM (2011). Indications for destructive eye surgeries at the Yaounde Gynaeco-Obstetric and Paediatric Hospital. *Clin Ophthalmol*; 5: 561–565.
- Bodunde OT, Ajibode HA, Awodein OG (2005). Destructive eye surgeries in Sagamu. *Nigerian Medical Practitioner*; 48:47-49
- Cheng GY, Li B, Li LQ, Gao R, Ren J, Xu XL, et al (2008). Review of 1375 enucleations in



the TongRen Eye Centre, Beijing. *Eye*; 22:1404–1409.

Chinda D, Abah ER, Rafindadi AL, Samail E (2011). Changing trend in the causes of destructive eye surgery at Guinness Ophthalmic Unit, Ahmadu Bello University Teaching Hospital, Kaduna, Nigeria. *Ann Nigerian Med*; 4:62-5.

Epee E, Moukouri NE, Kamegni G (2008). Ocular mutilating surgery: a case study of 32 patients operated at the university teaching hospital. *Rev Afr Chir Spec*; 002:23–28.

Etebu EN, Adio AO (2008). Indications for removal of the eye at a tertiary hospital in south-southern Nigeria. *East Afr J Ophthalmol*; 19–22.

Gyasi ME, Amoaku WM, Adjuik M (2009). Causes and incidence of destructive eye procedures in north-eastern Ghana. *Ghana Med J*;43:122–126.

Moshfeghi DM, Moshfeghi AA, Finger PT (2000). Enucleation. *Surv Ophthalmol*;44: 277–30

Nwosu SN (2005). Destructive ophthalmic surgical procedures in Onitsha, Nigeria. *Niger Postgrad Med J*; 12:53–56.

Source of support: nil. Conflict of interest: none declared