

Beauty of Black and White: Autofluorescence-aided Differentiation of Serpiginous Choroiditis from Tubercular Serpiginous-Like Choroiditis

Anadi Khatri, MD^{1,2,3,*}, Shanti Gurung, MD⁴, Ranju Kharel Sitaula, MD⁵, Sweta Singh, MD⁶, Anh N.T. Tran, BA¹, Amir Akhavanrezayat, MD¹, Zheng Xian Thng, MBBS, MMed1,⁷ Eunice You, MD, MSc^{1,8,9}, Albert John Bromeo, MD,¹⁰ Ngoc T.T. Than, MD¹, Muna Kharel², Ankur Sudhir Gupta, MD¹, Tanya Jain, MD^{1,11}, S. Saeed Mohammadi, MD¹, Christopher Chi Mong Or, MD¹, Vahid Bazajoo, MD¹, Woong-Sun Yoo, MD^{1,12}, Eli Pradhan¹³, Saraswati Khadka Thapa¹⁴, Gyanendra Lamichhane¹⁴, Rupesh Agrawal, MD^{15,16,17}, Quan Dong Nguyen, MD, MSc¹

¹Spencer Center for Vision Research, Byers Eye Institute, Stanford University School of Medicine, Palo Alto, California, USA, ²Birat Eye Hospital, Biratnagar, Nepal, ³Birat Medical College and Teaching Hospital, Biratnagar, Nepal, ⁴Birtamode Eye Hospital, Nepal, ⁵B. P. Koirala Lions Centre for Ophthalmic Studies, Maharajgunj, Kathmandu, Nepal, ⁶Dristi Eye Care Centre, Birtamode, Nepal, ⁷Department of Ophthalmology, National Healthcare Group Eye Institute, Tan Tock Seng Hospital, Singapore, ⁸Department of Ophthalmology, Hôpital du Saint-Sacrement, CHU de Québec – Université Laval, Quebec City, Canada., ⁹Nuffield Department of Primary Care Health, Oxford University, Oxford, England., ¹⁰Asian Eye Institute, Makati, Philippines, ¹¹Dr. Shroff's Charity Eye Hospital, India, ¹²Department of Ophthalmology, Gyeongsang National University Hospital, Jinju, S. Korea, ¹³Department of Retina, Tilganga Institute of Ophthalmology, Kathmandu, Nepal, ¹⁴Lumbini Eye Institute and Research Center, Lumbini, Nepal, ¹⁵Department of Ophthalmology, National Healthcare Group Eye Institute, Tan Tock Seng Hospital, Singapore, ¹⁶Department of Ophthalmology and Visual Sciences, Academic Clinical Program, Duke-NUS Medical School, Singapore, Singapore, ¹⁷Moorfields Eye Hospital, NHS Foundation Trust, London, UK

Conflict of Interest : Nil

Received : 12.10.2023

Financial Interest : Nil

Accepted : 27.12.2023

Corresponding Author

Anadi Khatri, MD
Research Scholar and Instructor in Retina and Uvea
Spencer Center for Vision Research, Byers Eye Institute
Stanford University School of Medicine
Palo Alto, California, USA
E-mail: anadikc@stanford.edu



Access this article online

Website: www.nepjol.info/index.php/NEPJO

DOI: <https://doi.org/10.3126/nepjoph.v16i1.76996>

Copyright © 2024 Nepal Ophthalmic Society

ISSN: 2072-6805, E-ISSN: 2091-0320



This work is licensed under a Creative Commons Attribution-NonCommercial-NoDerivatives 4.0 International License (CC BY-NC-ND).

ABSTRACT

Introduction: FAF is non-invasive, and important adjunctive tool to evaluate the progression of lesions in patients with SC. FAF can even help distinguish probable etiology by specific pattern recognition. The current index study analyzed and reported the strength of specific patterns to be more representative of SC or TB SLC.

Objective: To characterize fundus autofluorescence (FAF) images for differentiating serpiginous choroiditis (SC) from tubercular serpiginous-like choroiditis (TB SLC).

Methodology: The index study is a retrospective comparative analysis of FAF images of 25 consecutive patients, 11 with TB SLC and 14 with SC. The diagnosis of SC was made based on the clinical appearance and FAF findings, while TB SLC was additionally considered in patients with positive laboratory investigations and/or radiological tests for tuberculosis (TB) exposure or infection and therapeutic response to anti-tubercular therapy. The characteristic features evaluated on FAF images were centrality, multifocality, and parapapillary involvement of the lesion with or without extension.

Result: Twenty-five patients (13 males, 12 females) with a mean age of 46.2 (SD 10.08) years were enrolled in the study. SC lesions were more central ($\rho=0.92$) and confluent ($\rho=0.774$). Parapapillary involvement was found to be associated with SC ($\rho=0.690$), and with extensions of the lesions along the arcades or the macular region, the association increased ($\rho=0.786$). Multifocality with peripheral lesions was negatively associated with SC ($\rho=-0.831$).

Conclusion: Centrally involving lesions with confluency on FAF is strongly associated with SC. Parapapillary involvement alone is considered characteristic for SC, but the current study has demonstrated that extension of this lesion along the arcades or the macular region is even more characteristic for SC.

Key words: Choroid; choroiditis; fundus autofluorescence; serpiginous; tuberculosis; uveitis.

INTRODUCTION

Serpiginous choroiditis (SC) is a rare clinical entity and accounts for less than 5% of cases of posterior uveitis. It causes a geographical pattern of choroiditis with outer retina and retinal pigment epithelium atrophy, extending from the parapapillary choroidal region and spreading centrifugally.^(Bacin F et al, 1983; Lim WK et al, 2005) It is typically bilateral with no familial or ethnic predilection in otherwise healthy, middle-aged individuals. ^(Abu el-Asrar AM, 1995) The pathogenesis of SC is unclear, but based on limited histopathological studies, the favorable response to immunosuppressive

agents, and a lack of association with systemic or ocular infectious diseases, autoimmune-driven inflammation is thought to be underlying cause.^(Cordero-Coma et al, 2008)

Diagnosis of the SC is mainly done by considering the history, clinical findings with support from ocular imaging and laboratory investigation. The tests usually include fluorescein angiography (FA), indocyanine green angiography (ICG) and fundus autofluorescence (FAF). ^(Nazari Khanamiri H et al, 2013; Vasconcelos-Santos DV et al, 2010) FA typically shows early hypo fluorescence with late leakage at the edges of the lesions if they are in the process of expanding

due to the disease being active. ICG usually demonstrates hypocyanescent areas from early to late frames.

FAF is a minimally invasive tool for assessing disease progress and activity is demonstrated by a hypoautofluorescent halo surrounding the edges of a hyperautofluorescent lesion. (Yeh S et al, 2010) Treatment of SC typically consists of steroids, anti-metabolites and biologics and its response is also considered as one of the key indicators to be followed for purpose of proper diagnosis.

This is important as patients, particularly those from Mycobacterium tuberculosis (TB) - endemic regions, have presented with fundus findings similar to SC. (Rupesh Agrawal et al, 2018; Vasconcelos-Santos DV et al, 2010) Microbiological investigations in such patients have yielded mycobacterial DNA via polymerase chain reaction. However, this does not hold true in all the cases and the debate speculations over whether the serpiginous lesions are due to direct insult by the TB microorganism or secondary to a hypersensitivity reaction to the infection still persists. (Deb AK, Kaliaperumal S et al, 2014; Gupta V et al, 2007; Gupta A et al, 2010)

Other reports have been published on the utility of interferon-gamma release assay (IGRA) to rule out TB as a possible etiological agent in posterior uveitis. IGRA (QTB-Plus) has a pooled sensitivity and specificity of over 95% but is still limited in its ability to distinguish between latent and active TB and/or predict risk of progression from latent to active phase. Therefore, there should still be a high index of suspicion even in patients with negative IGRA

if the clinical history, findings and pattern of inflammation are otherwise suggestive of ocular tuberculosis.

Various clinical features and clues can help in distinguishing between SC and TB SLC. One of the most important clinical features of TB SLC is that it is associated with more vitritis compared to autoimmune SC.¹⁰ Patients with TB SLC have more multifocal lesions involving the periphery.¹⁰ In contrast, SC lesions are larger compared to TB SLC and is more likely to have lesions extending from the optic nerve head. (Chisholm IH et al, 1976) Most of the time, the lesions and their extent may not be clearly visible, and hence multimodal imaging techniques can be a useful ancillary investigation. (Carreño E et al, 2012; Gupta V et al, 2003) FA as mentioned above, does help in distinguishing between an active and an inactive lesion, but there are no specific angiographic features to differentiate between SC and TB SLC. (Nazari Khanamiri H et al, 2013; Vasconcelos-Santos DV et al, 2010)

FAF however being less invasive, has been studied to provide characteristic features which could help differentiating between TB SLC and SC. (Yeh S et al, 2010) Homogenous hypofluorescence corresponding to RPE loss is more suggestive of SC compared to the variegated pattern and stippled hyperautofluorescence of tuberculous disease that have been reported in the literature. (Arantes TE et al, 2011; Cardillo Piccolino F et al, 2009; Carreño E et al, 2012; Vasconcelos-Santos DV et al, 2010; Yeh S et al, 2010) However, it remains challenging to differentiate between TB SLC and SC as these patterns are not consistent and may overlap depending upon the stage, severity, or duration of the disease. For instance, the lesions are

hyperautofluorescent during the acute stage, increasing in autofluorescence with advancing borders and ultimately decreasing during healing. (Gupta A et al, 2014) At any of these stages, the disease may present with mixed patterns.

The aim of the current index study was to analyze the images of patients diagnosed with SC and TB SLC to ascertain the specific FAF features characterizing these two pathologies.

METHODS

A retrospective study was conducted at a tertiary eye care center in Nepal with the assistance of national and international expertise for the analysis of the images and data. This study included data of patients with autoimmune SC and TB SLC diagnosed from July 2021 to April 2022. Comparative analysis of FAF images of 25 patients (11 with TB SLC and 14 SC) was performed.

Data and image retrieval of patients who had a diagnosis of SC or TB SLC and had received antitubercular treatment (ATT), steroids, or immunosuppressive agents was performed. The index study followed the tenets of the Declaration of Helsinki and was ethically approved by the institute.

All patients had at least one year of follow-up and medical records with details of ophthalmic examinations, including color fundus photographs and FAF images. The image acquisition protocol consisted of mydriasis with tropicamide 1% eyedrops and acquisition of single 45° field color images

centered on the macula for each eye using the Zeiss Visucam 524 fundus camera (Carl Zeiss Meditec AG, Jena, Germany).

The diagnosis for SC was done on the basis of clinical findings, imaging and laboratory investigations – like native TB reports and also the response of the disease to IMT.

The criteria for tubercular uveitis (TBU) was adopted from the international classification of ocular TB (Gupta A et al, 2015) as the presence of any one of the following clinical signs which are highly suggestive of TB such as presence of choroidal granulomas, broad-based posterior synechiae, retinal vasculitis or TB-SLC with documentation of a positive tuberculin skin test or a positive QuantiFERON-TB Gold test and response to ATT. All patients received investigations to exclude other potential diagnoses including multifocal chorioretinitis, acute posterior multifocal placoid pigment epitheliopathy, toxoplasmosis, etc.

Image analysis was done by two expert readers with consensus by discussion in the event of disagreement. Interim feedback was sought after the first 10 images were graded by the two readers which served as a pilot test of the grading process to assess feasibility and adherence to prespecified grading guidelines. No difficulties were encountered and all images were included in the final analysis.

Lesion patterns evaluated using FAF images were classified on 1) centrality, 2) multifocality, and 3) parapapillary involvement with or without extension (Figure 1 and Figure 2).

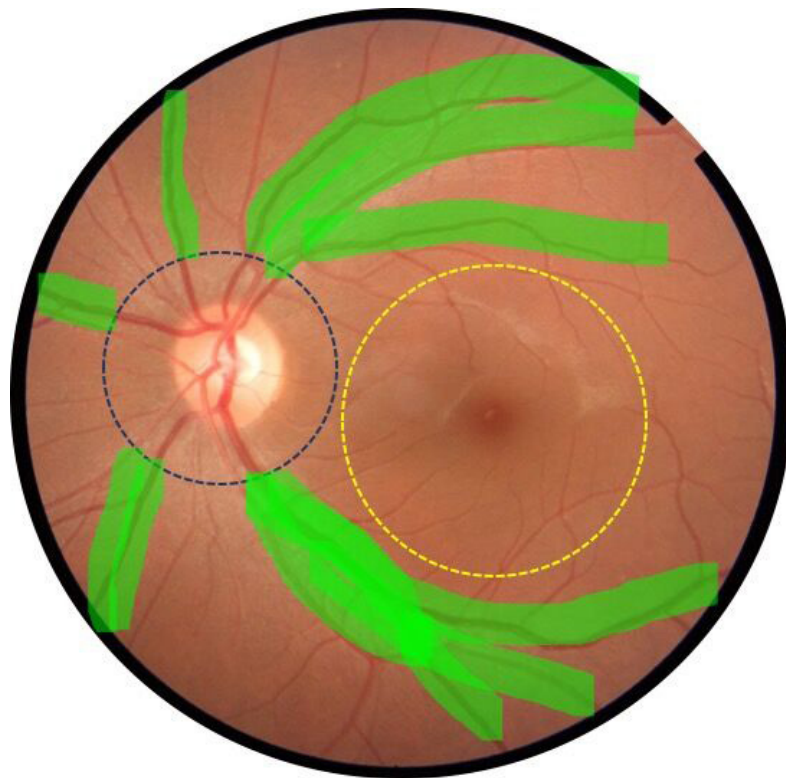


Figure 1 : Reference image depicting definitions of terminologies used.

The terms “central” and “peripheral” are designated with respect to a 45-degree fundus photo centered on the macula (yellow-dotted circle in Figure 1).

1. Centrality- Any lesion which occupies at least 50 percent of the area/region delineated by the yellow dotted circle in the figure is considered central. Also designated as the area centralis, the area roughly corresponds to the macular area with a diameter of 5.5mm.
2. Peripheral – Any lesion which does not fall within the area defined for centrality will be considered as a peripheral lesion.
3. Parapapillary- Any lesion involving the optic disc margin and in which at least 50 percent of the lesion falls within one-disc diameter of the optic nerve head could be considered parapapillary (red-dotted circle in Figure 1).
4. With or without extension – Any lesion fulfilling the criteria for parapapillary localization with development of similar lesions mostly confluent with the primary lesion and extending along the vascular arcades (highlighted in green in Figure 1) will be considered extended lesions.
5. Multifocal: Any lesion that is separated by areas of normal tissue which can help identify them as two individual separate lesions will be considered multifocal (green dotted circle in Figure 2).

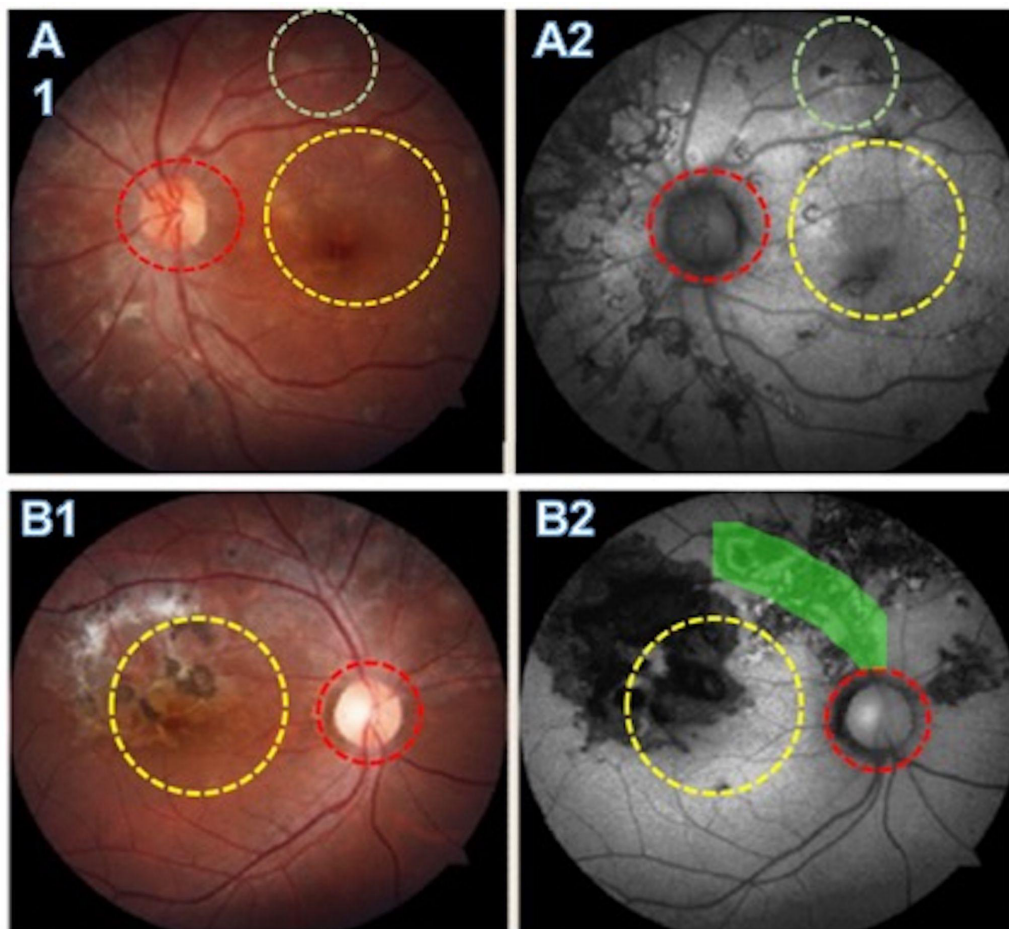


Figure 2: Non -central multifocal lesions with parapapillary sparing and absence of extensions as depicted on color fundus photography (A1) and autofluorescence (A2). Central lesion with presence of a confluent parapapillary lesion (B1) with extension along the superotemporal arcade and the nasal quadrants (B2).

Statistics

Statistical analyses were done using SPSS software version 20.0 (IBM Corp., Armonk, N.Y., USA). Pearson's Correlation Coefficient (ρ [rho]) was used to measure the strength of each pattern of SC and the following interpretation was adopted.(Karl Pearson ,1895; Rogers and Nicewander, 1988)

- 0 indicates a linear relationship.
- +1 indicates a perfect positive linear relationship.
- 1 indicates a perfect negative linear relationship.
- Values between 0 and 0.3 (0 and -0.3) indicate a weak positive (negative) linear relationship via a shaky linear rule.
- Values between 0.3 and 0.7 (-0.3 and -0.7) indicate a moderate positive (negative) linear relationship via a fuzzy-firm linear rule.
- Values between 0.7 and 1.0 (-0.7 and -1.0) indicate a strong positive (negative) linear relationship via a firm linear rule.

RESULTS

The medical records and images of twenty-five (25) patients (13 males, 12 females) with a mean age of 46.2 ± 10.08 years were analyzed. A total of 14 (56%) were diagnosed as SC and 11 (44%) as TB SLC patients. There was no gender predilection for either of the pathologies. The ocular involvement in SC was more likely to be bilateral (57.2%) compared to TB SLC (45.5%) (Table 1).

SC lesions demonstrated a stronger predilection for central distribution ($\rho=0.921$) followed

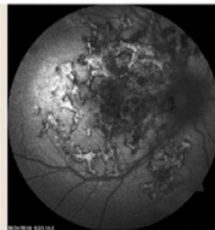
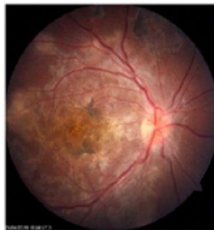
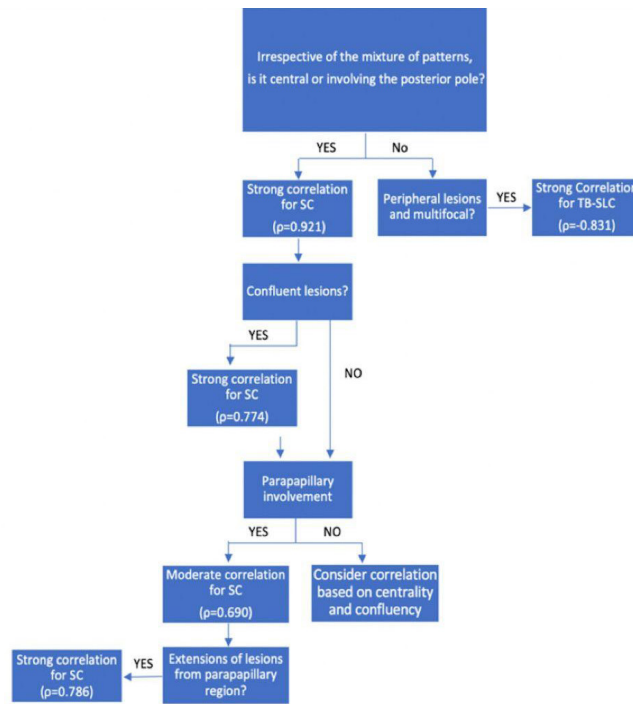
by confluent lesions ($\rho=0.774$). Parapapillary involvement alone had a correlation of $\rho=0.690$, indicating a moderately positive relationship, but if the lesions had extensions along the arcades or had contiguity around the macular region, the correlation increased to $\rho=0.786$, indicating a strong positive relationship for SC (Figure 3 and Figure 4). Multifocality with peripheral lesions negatively correlated with SC ($\rho=-0.831$) and most of these lesions were found to be associated with cases diagnosed as TB SLC (Table 2).

Table 1: Demographics and inflammation pattern of serpiginous choroiditis (SC) and tubercular serpiginous-like choroiditis (TB SLC).

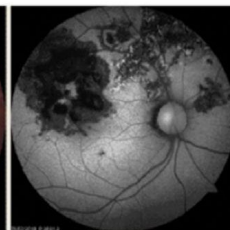
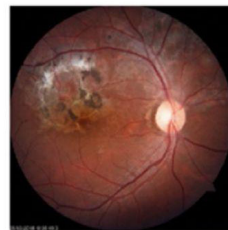	Serpiginous Choroiditis	Tubercular Serpiginous-like Choroiditis
Number of patients	14	11
Male	6	7
Female	8	4
Bilateral involvement	8	5
Pattern		
Central	14	1
Para papillary involvement	11	1
Para papillary involvement with extension	11	0
Multifocality with peripheral lesions	14	3

Table 2: Lesion pattern and their correlation strength towards serpiginous choroiditis (SC)

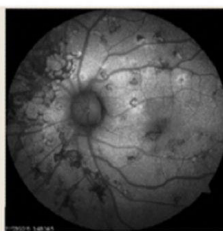
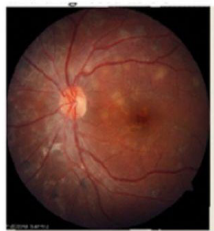Pattern	Correlation ((ρ))	Interpretation
Central	+ 0.92	Strongly positive
Parapapillary involvement	+0.69	Moderately positive
Parapapillary involvement with extensions	+0.79	Strongly positive
Confluency	+0.77	Moderately positive
Multifocality with peripheral lesions	-0.83	Strongly negative
Diagnostics		
Chest X ray findings	-0.49	Moderately negative



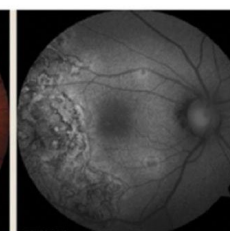
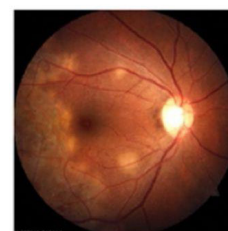Central, parapapillary involvement with extensions along the vascular arcade. The lesions are not multifocal. Patterns suggestive of SC and clinical and laboratory investigations also supported the diagnosis as SC.



Central involving (at least 50 percent of the area) with parapapillary lesions with extensions along the vascular arcade. Laboratory investigations and clinical features suggestive of SC.



Peripheral, (less than 50 percent of the central area involved), no parapapillary involvement. Multifocal in nature. Patient had history of tuberculosis and was Gold QuantiFERON positive. Diagnosed, treated and responded well to anti-tubercular therapy.



Peripheral, (Central sparing), no parapapillary involvement. Not distinctly multifocal. Patient had history of tuberculosis in family and was Gold QuantiFERON positive. Responded well to anti-tubercular therapy.

* SC: Serpiginous Choroiditis, TB-SLC : Tubercular Serpiginous- like choroiditis.

Figure 3: Algorithm in favor of Serpiginous Choroiditis (SC) with correlation strength of each pattern. Images and pattern are also depicted to illustrate the difference in the lesion pattern between SC and Tuberculous serpiginous-like choroiditis (TB SLC). Only features with strong positive or negative correlation have been taken into account.

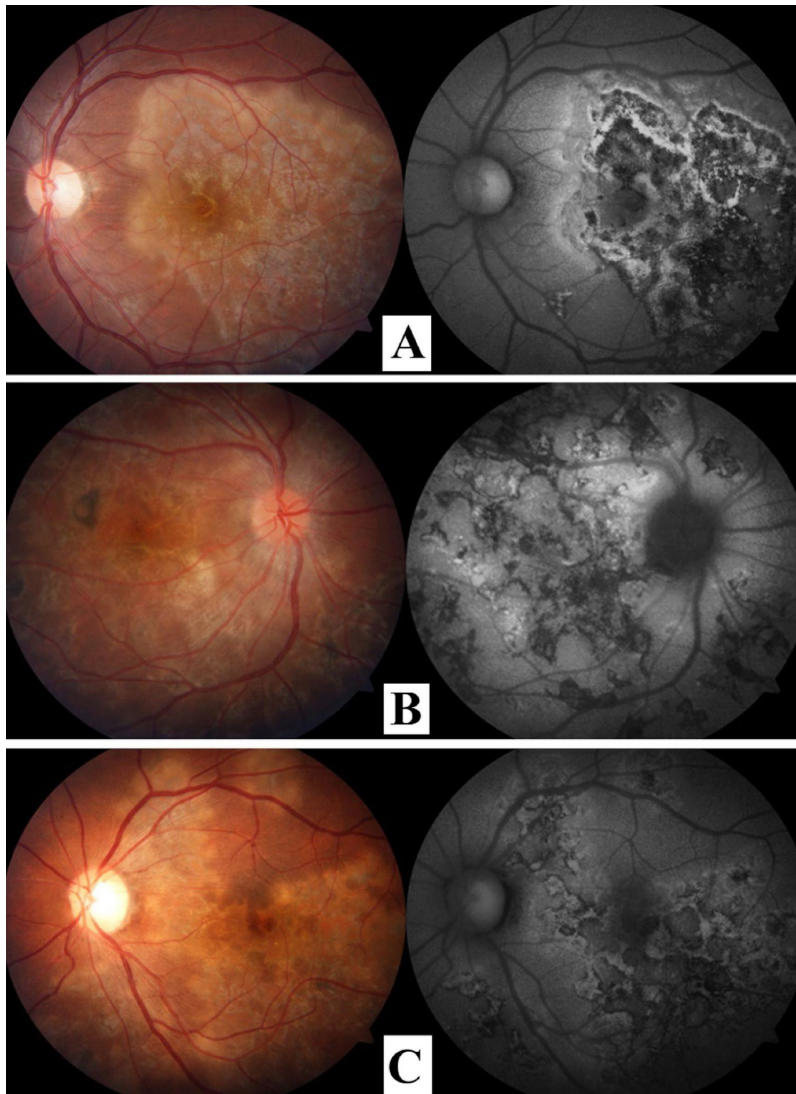


Figure 4: Serpiginous Choroiditis (SC) with varied patterns. (A) Central involvement ($\rho=0.921$) and confluency ($\rho=0.774$) without involvement of parapapillary region. (B) Central involvement ($\rho=0.921$), and involvement of the parapapillary region with extension towards the macula ($\rho=0.786$). Note some multifocal lesions but other features outweigh it in terms of strength of correlation. (C) Central involvement ($\rho=0.921$), confluency ($\rho=0.774$), and involvement of the parapapillary region with extensions ($\rho=0.786$).

DISCUSSION

SC is a diverse clinical entity in ophthalmology. (Bacin et al, 1983; Cordero-Coma et al, 2008; Vasconcelos-Santos DV et al, 2010; Yeh S et al. 2010) Similarly, the spectrum of patterns

on autofluorescence of SC is also diverse, although multiple studies have been conducted illustrating the FAF patterns of different stages of SC, disease activity, as well as of the possible variants. (Cardillo Piccolino F et al, 2009; Gupta A et al, 2014; Yeh S et al. 2010) To the

best of our knowledge, this is the first study to evaluate the images and patterns described in the literature to assess if a certain pattern has a relatively stronger correlation for either SC or TB SLC.

It is well reported in the literature that SC may manifest with variable features, although a creeping pattern of choroiditis, central/posterior pole involvement, and extension of the lesions from the parapapillary area are the most commonly encountered ones. (Gupta V et al, 2007; Gupta A, et al, 2010; Vasconcelos-Santos DV et al) Patients with TB SLC, however, are more likely to have multifocal scattered highly pigmented lesions with posterior vitreous cells. (Gupta V et al, 2007; Gupta V et al, 2003; Vasconcelos-Santos DV et al, 2010)

Our study found that if the distribution of the lesion was more central/around the posterior pole, it was more representative of SC even if other features were present. The findings of this study are consistent with the literature. (Arantes TE et al, 2011; Gupta A et al, 2010; Gupta A et al, 2014; Yeh S et al, 2010) Parapapillary involvement is also widely described in the literature and this finding has also been thought to be indicative of SC. (Bacin F et al, 1983; Cordero-Coma et al, 2008; Gupta A et al, 2010; Gupta V et al, 2003) Our study supported this finding and also proposed that this pattern, along with extension of lesions from the parapapillary region, were more suggestive of SC. Furthermore, multifocality with peripheral lesions is often thought to be associated with a tuberculous origin. (Deb AK, Kaliaperumal S et al, 2014; Gupta A et al, 2010; Gupta V et al, 2003; Vasconcelos-Santos DV et al, 2010) The majority of our cases with multifocal lesions

were tuberculous in etiology and our analyses also indicated that if such lesions were present, it was much less likely that the lesions were of SC.

We do recognize some of the limitations of the study which are the small sample size and lack of multinational involvement. Image analysis were done by consensus of two expert readers. Another major limitation is related to the 'gold standard' for diagnosis for serpiginous. We have masked to help minimize the bias but if the readers have a preexisting knowledge of certain FAF features that are used to define the disease entity as in SC, one would expect a higher likelihood that the defined features/areas of involvement would show correlation/statistical significance. With the ever-increasing application of artificial intelligence systems in ophthalmology, use of machine learning would be beneficial to analyze these or perhaps even larger data set in the future for more unbiased results.

CONCLUSION

It is well established that FAF is an easy, non-invasive, and very important adjunctive tool to evaluate the progression of lesions in patients with SC. FAF can even help to distinguish the probable etiology by specific pattern recognition. The current index study analyzed and reported the strength of specific patterns to be more representative of SC or TB SLC. The study concluded that SC is characterized by central involvement and by the confluent nature of the lesions. Parapapillary involvement along with extension of the lesions, along the arcades or in contiguity with the macular region is more representative of SC, while multifocal

scattered pigmented chorioretinal lesions with the presence of posterior vitreous cells are more suggestive of TB SLC.

ACKNOWLEDGEMENTS

We acknowledge several national and international ophthalmologists who shared their personal experience to complete this manuscript. We would also like to acknowledge and extend our sincere gratitude to Mr. Suresh Sharma and Mr. Mahesh Aryal for their unconditional and extensive assistance with technical support and clinical images.

Ethical Clearance

The research has been approved by the ethics committee and the Institutional Review Board of Lumbini Eye Institute and Research Centre, Lumbini, Nepal, and adheres to the tenets of the Declaration of Helsinki (IRB Approval Number: 2057). Written consent was received from all the participants.



REFERENCES

-
- Abu el-Asrar AM. Serpiginous (geographical) choroiditis. *Int Ophthalmol Clin.* 1995;35 (2):87–91., n.d.
- Arantes TE, Matos K, Garcia CR, et al. Fundus autofluorescence and spectral domain optical coherence tomography in recurrent serpiginous choroiditis: case report. *Ocul Immunol Inflamm* 2011;19(1):39–41., n.d.
- Bacin F, Larmande J, Boulmier A, Juliar G. Serpiginous choroiditis and placoid epitheliopathy. *Bull Soc Ophthalmol Fr.* 1983; 83:1153-62, n.d.
- Cardillo Piccolino F, Grosso A, Savini E. Fundus autofluorescence in serpiginous choroiditis. *Graefes Arch Clin Exp Ophthalmol* 2009;247(2):179–85, n.d.
- Carreño E, Portero A, Herreras JM, López MI. Assesment of fundus autofluorescence in serpiginous and serpiginous-like choroidopathy. *Eye (Lond).* 2012;26(9):1232–1236. doi:10.1038/eye.2012.121, n.d.
- Chisholm IH, Gass JD, Hutton WL. The late stage of serpiginous (geographic) choroiditis. *Am J Ophthalmol* 1976;82(3):343–51, n.d.
- Cordero-Coma M, Benito MF, Hernández AM, Antolin SCR, Ruíz JM. Serpiginous choroiditis. *Ophthalmology* 2008;115 (9) 1633, n.d.
- Deb AK, Kaliaperumal S, Rao VA, Sengupta S. Relationship between systemic hypertension, perfusion pressure and glaucoma: A comparative study in an adult Indian population. *Indian Journal of Ophthalmology.* 2014;62(9):917-922. doi:10.4103/0301-4738.143927., n.d.
- Gupta V, Gupta A, Rao NA. Intraocular tuberculosis—an update. *Surv Ophthalmol* 2007;52 (6) 561- 587, n.d.
- Gupta A, Bansal R, Gupta V, et al. Ocular signs predictive of tubercular uveitis. *Am J Ophthalmol* 2010;149:562–70, n.d.
- Gupta A, Biswas J. Fundus autofluorescence imaging to document evolution, progression and healing pattern of serpiginous choroiditis. *Oman J Ophthalmol.* 2014;7(2):100–101. doi:10.4103/0974-620X.137175, n.d.
-



-
- Gupta A, Sharma A, Bansal R, Sharma K. Classification of intraocular tuberculosis. *Ocul Immunol Inflamm.* 2015; 23: 7–13., n.d.
- Gupta V, Gupta A, Arora S, Bambery P, Dogra MR, Agarwal A. Presumed tubercular serpiginouslike choroiditis: clinical presentations and management. *Ophthalmology.* 2003;110 (9):1744–1749., n.d.
- Karl Pearson (20 June 1895) “Notes on regression and inheritance in the case of two parents,” *Proceedings of the Royal Society of London*, 58 : 240–242., n.d.
- Lim WK, Buggage RR, Nussenblatt RB. Serpiginous choroiditis. *Surv Ophthalmol.* 2005;50(3):231-24415850812, n.d.
- Nazari Khanamiri H, Rao NA. Serpiginous choroiditis and infectious multifocal serpiginoid choroiditis. *Surv Ophthalmol.* 2013;58(3):203–232. doi:10.1016/j.survophthal.2012.08.008, n.d.
- Rogers and Nicewander (1988). “Thirteen Ways to Look at the Correlation Coefficient” (PDF). *The American Statistician.* 42 (1): 59–66. doi:10.2307/2685263. JSTOR 2685263., n.d.
- Rupesh Agrawal, Dinesh Visva Gunasekeran, Dhananjay Rajee, Aniruddha Agarwal, Quan Dong Nguyen, Onn Min Kon, Carlos Pavesio, Vishali Gupta, for the Collaborative Ocular Tuberculosis Study Group; Global Variations and Challenges With Tubercular Uveitis in the Collaborative Ocular Tuberculosis Study. *Invest. Ophthalmol. Vis. Sci.* 2018;59(10):4162-4171. doi: 10.1167/iovs.18-24102., n.d.
- Vasconcelos-Santos DV, Rao PK, Davies JB, Sohn EH, Rao NA. Clinical features of tuberculous serpiginouslike choroiditis in contrast to classic serpiginous choroiditis. *Arch Ophthalmol.* 2010;128(7):853-85820625045, n.d.
- Yeh S, Forooghian F, Wong WT, et al. Fundus autofluorescence imaging of the white dot syndromes. *Arch Ophthalmol* 2010;128(1):46–56, n.d.
-