

Case report

Choroidal metastases as the sole initial presentation of metastatic lung cancer: Case report and review of literature

Salah S¹, Khader J², Yousef Y³, Salem A², Al-Hussaini M⁴, Al-Asady R⁵

¹Department of Internal medicine/ Medical Oncology, ²Department of Radiation Oncology,

³Department of Surgery/Ophthalmology, ⁴Department of Pathology and Laboratory

Medicine, ⁵Department of Radiology

King Hussein Cancer Center, Al-Jubeiha, Amman 11941, Jordan

Abstract

Background: Choroidal metastasis as an initial presenting feature of metastatic lung cancer is exceedingly rare. External beam radiotherapy (EBRT) is an effective and widely accepted therapeutic modality. However, data addressing the effectiveness of other treatment strategies is limited. Herein, we present a patient with choroidal metastases secondary to lung cancer and review the relevant literature.

Case report: A 25-year-old male presented with deterioration of vision. His evaluation revealed bilateral choroidal metastasis secondary to adenocarcinoma of the lung. Unfortunately, his vision continued to deteriorate despite treatment with EBRT and chemotherapy.

Conclusion: Metastatic lung cancer can manifest with choroidal metastasis as an initial presentation.

Key-words: Choroid, lung cancer, metastasis, radiation therapy

Introduction

Choroidal metastasis as an initial presenting feature of metastatic lung cancer is exceedingly rare (Fernandes et al, 2006). Furthermore, available literature about effective treatment strategies is limited. We intend to present an extremely rare clinical scenario; a young male patient with bilateral choroidal metastases from lung cancer, and review the relevant literature in an attempt to highlight the epidemiological features, pathological characters, therapeutic regimens and disease outcomes of this poorly understood disease entity.

Case presentation

A 25-year-old man presented with decreased vision in the right eye for two weeks. He acknowledged smoking one pack of cigarettes daily for four years. Ophthalmic examination revealed his best corrected visual acuity to be 20/200 in the right eye and 20/20 in the left eye. Results of slit lamp examination were unremarkable. Funduscopy examination of the right eye showed an ill-defined, yellow-white elevated lesion in the choroid more than 10 times the disc diameter, involving the macula and the inferior edge of the fovea with associated serous retinal detachment (Fig. 1A). Funduscopy examination of his left eye showed an ill-defined, yellow-white elevated lesion in the choroid more than 5 times the disc diameter in size, nasal to the disc (Fig. 1B). Fluorescein angiography of his right eye revealed early hypofluorescence and late phase

Received on: 21.12.2011

Accepted on: 04.04.2012

Address for correspondence: Samer Salah, MD,
Department of Internal Medicine/ Medical Oncology, King
Hussein Cancer Center, Al-Jubeiha, Amman 11941, Jordan,
Tel: 00962799615458 Facsimile: + (962-6) 535-3001
E-mail: ssalah@khcc.jo

showed hyperfluorescence from the surface of his choroidal tumor associated with accumulated sub-retinal fluid. A B-scan ultrasound revealed a dome shaped, elevated choroidal lesion with moderate internal reflectivity.

The remaining physical examination was normal except for two hard subcutaneous nodules on his chest. In a search for primary malignancy, imaging studies were done, and showed left lung hilar mass, multiple liver metastasis, and widespread bone metastasis (Fig. 2).

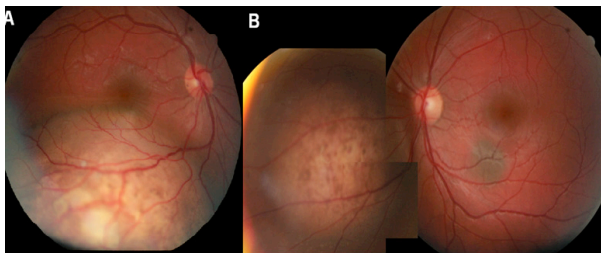


Figure 1: A- Right eye fundus examination showed a yellow-white elevated lesion in the choroid, inferiorly located involving the macula with associated serous retinal detachment. B- Left eye funduscopy revealed a choroidal metastasis at the nasal edge of the optic disc.

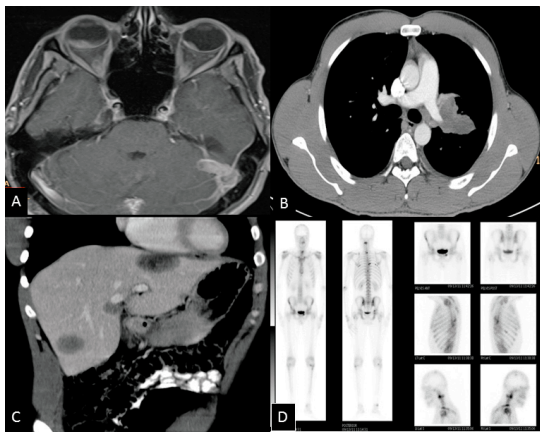


Figure 2: A- Orbit MRI axial, T1 WI's post contrast image showing soft tissue nodular lesions in the posterior parts of the eye globes mainly at the right side, demonstrating homogeneous contrast enhancement. B- Enhanced CT scan of the chest; mediastinal window shows left hilar soft tissue mass encasing the left main pulmonary artery. C- CT scan through the liver shows multiple hypodense liver lesions represent metastases. D- Bone scan demonstrates multiple active bone lesions represent metastases.

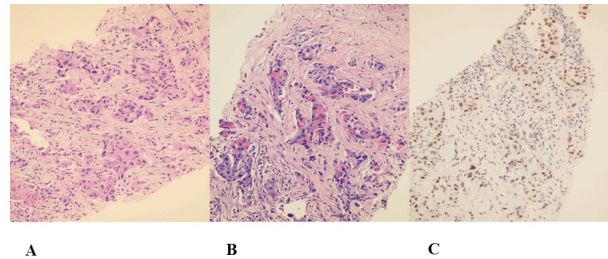


Figure 3: Microscopic examination of the biopsy from lung mass. A- Sheets of tumor cells with acidophilic cytoplasm are seen (H&E X20). B- Mucicarmine stain highlighted intra-cytoplasmic mucin (X20). C- Positive nuclear staining with TTF-1 (X20).

A computed axial tomography (CT) scan guided lung biopsy as well as biopsy of the skin nodules was performed. The tumor showed proliferation of groups of cells within markedly desmoplastic stroma (Fig. 3 A). The cells contained intra-cytoplasmic vacuoles that stained positive with mucicarmine stain (Fig.3B) consistent with adenocarcinoma. Immunohistochemistry positivity for TTF-1 antibody was demonstrated (Fig. 3 C). Occasional tumor cells were positive for Cytokeratin 5/6 and P63. The overall features were consistent with moderately differentiated adenocarcinoma of lung origin.

The patient was initiated on chemotherapy with cisplatin and docetaxel, and EBRT to both orbits. Unfortunately, the patient continued to experience rapid deterioration of vision in the right eye (visual acuity dropped from 20/200 to counting fingers at 1 meter) and the left eye (visual acuity dropped from 20/20 to 20/200). Fundoscopic examination showed right total serous retinal detachment (RD) and left nasal and inferior serous RD involving the macula. He received EBRT as 30Gy/10Fx over two weeks to both orbits via a pair of parallel-opposed beams. Following completion of radiotherapy, follow-up ophthalmic evaluation (clinical and ultrasonic) showed stability in the size of choroidal lesions in both eyes but no regression of serous RD. Systemic steroids and posterior subtenon steroid injections were applied as treatment for serous retinal detachment. Following the second cycle of chemotherapy, imaging studies revealed significant progression of lung mass and liver lesions.

Discussion

The choroid is a rare site of involvement by metastatic carcinomas. Godtfredsen (1944) reported only six patients (0.07%) in a survey that included 8,712 patients with malignancy. Furthermore, choroidal involvement typically occurs late in the course of metastatic cancer (Fernando et al, 2005). Following breast neoplasm, lung cancer is the second most common cancer to metastasize to the choroid (Fernandes et al, 2006). Post mortem examination of donated eyes of patients with carcinomas showed a 6.1 % frequency of eye involvement in patients dying of lung cancer, however; only 2.7 % of all lung cancer patients in that series had gross metastasis while the remaining had only microscopic metastasis (BabakEliassi-Rad et al, 1996). This finding suggests that most patients die when the choroidal metastasis is at a microscopic stage and before developing visual symptoms, which explains the rarity of this site of metastasis as a presenting feature.

Characteristics of the 30 reported cases and their metastatic lung cancer are outlined in table 1.

Our patient of age 25 years is the youngest reported case of choroidal metastases secondary to lung cancer. Nineteen patients (61%) had accompanying retinal detachment at their initial ophthalmologic evaluation. Most patients had multi-organ metastases, with the brain, liver and bone as the most common metastatic sites.

Choroidal metastasis can be distinguished from primary choroidal melanoma by clinical characteristics; typical choroidal metastasis is more often in the plateau-shaped than in the dome-shaped; yellow-white or mottled in color and associated with subretinal fluid and retinal detachment. FFA characterized by mottled hyperfluorescence in early stage while leakage in late stages and B-scan ultrasonography usually shows moderate reflectivity, mostly no biopsy is needed unless extensive staging work up had failed to reveal the primary or other metastatic sites (Zhang et al, 2009).

EBRT is effective in treating and palliating patients with asymptomatic and symptomatic choroidal metastases. Doses in the range of 3000 to 4000cGy delivered via conventional fractionation are well tolerated and result in visual stabilization or improvement in up to 85% of cases (Wiegel et al, 2002; Amer et al, 2004; Dobrowsky, 1988; Rosset, 1998; Bottke et al, 2000). A unilateral radiation portal is appropriate in patients presenting with unilateral choroidal metastasis (Wiegel et al, 1999). However, it should be noted that patients included in these studies had a diagnosis of metastatic breast cancer and only a few presented with choroidal involvement secondary to a lung neoplasm.

The effectiveness of chemotherapy as a single modality in treating choroidal metastasis is not widely reported in the literature, however; a study in patients with breast cancer and choroidal metastasis concluded that systemic chemotherapy is as effective as radiotherapy as all six patients treated with systemic chemotherapy alone showed regression of their choroidal metastasis (Letson et al, 1982). Additionally, of the 30 reported cases we reviewed, 14 patients were treated with chemotherapy without additional EBRT, it was worthy to notice that 6 out of the 14 patients had complete resolution, and additional 4 patients had partial regression of the choroidal metastasis.

Although the available level of evidence supporting chemotherapy as a single modality in treating choroidal metastasis is limited, it can be a reasonable alternative when external beam radiotherapy is not readily available.

Among our reviewed cases, all patients who received EBRT had also received chemotherapy, either concurrently or sequentially. Unfortunately, due to the paucity of data, it was difficult to derive firm conclusions about how these two modalities should best be integrated.

Choroidal metastasis is usually associated with widespread multi-organ metastases, and carries an extremely poor prognosis with survival counted in few months. In the extremely rare event when the



choroid is the only metastatic site, enucleation of the affected eye may carry the advantages of confirming the pathological diagnosis, palliating intractable pain and most importantly, offering a chance for long term survival. O'Connell et al (1990) reported a patient who remained alive and free of recurrence 4 years following eye enucleation.

Conclusion

Choroidal metastasis as an initial presentation of metastatic lung cancer is exceedingly rare. Though the EBRT and systemic chemotherapy are reported to be effective treatment options associated with clinical and objective visual responses, our patient did not improve with the regime.

Acknowledgement

We are grateful to Alice Haddadin and Lubna Al-Useily from the King Hussein Cancer Center Medical Library for assistance.

References

Amer R, Pe'er J, Chowers I, Anteby I. Treatment options in the management of choroidal metastases (2004). *Ophthalmologica*; 218(6):372-7.

Babak Eliassi-Rad, Daniel M Albert, W Richard Green (1996). Frequency of ocular metastases in patients dying of cancer in eye bank populations. *Br J of Ophthalmol*; 80: 125-128.

Bottke D, Wiegel T, Kreusel KM, Bornfeld N, Schaller G, Hinkelbein W (2000). Radiotherapy of Choroidal Metastases in Patients with Disseminated Cancer. *Onkologie*; 23(6):572-575.

Dobrowsky W (1988). Treatment of choroid metastases. *Br J Radiol*; 61(722):140-2.

Fernandes BF, Fernandes LH, Burnier MN Jr (2006). Choroidal mass as the presenting sign of

small cell lung cancer. *Can J Ophthalmol*; 41:605-8.

Fernando A, Fernandez CF, Garcia RA (2005). Optical coherence tomography. Characteristics of choroidal metastasis. *Ophthalmol*; 122:1612-1619.

Godtfredsen E (1944). On the frequency of secondary carcinomas in the choroid. *Acta Ophthalmol*; 22:394 - 400.

Letson AD, Davidorf FH, Bruce RA Jr (1982). Chemotherapy for treatment of choroidal metastases from breast carcinoma. *Am J Ophthalmol*; 93(1):102-6.

O'Connell ME, Henk JM, Whitelocke RA, Fisher C (1990). Solitary choroidal metastasis in bronchial carcinoma. *Clin Oncol (R Coll Radiol)*; 2(3):177-9.

Rosset A, Zografos L, Coucke P, Monney M, Mirimanoff RO (1998). Radiotherapy of choroidal metastases. *Radiother Oncol*; 46(3):263-8.

Wiegel T, Bottke D, Kreusel KM, Schmidt S, Bornfeld N, Foerster MH, Hinkelbein W (2002). German Cancer Society. External beam radiotherapy of choroidal metastases - final results of a prospective study of the German Cancer Society (ARO 95-08). *Radiother Oncol*; 64(1):13-8.

Wiegel T, Kreusel KM, Schmidt S, Bornfeld N, Foerster MH, Hinkelbein W (1999). Radiotherapy of unilateral choroidal metastasis: unilateral irradiation or bilateral irradiation for sterilization of suspected contralateral disease? *Radiother Oncol*; 53(2):139-41.

Zhang HR, Ma ZZ, Feng Y, Guo T (2009). Clinical characteristics of choroidal metastasis. *Zhonghua Yan Ke Za Zhi*; 45(4):301-8.

Source of support: nil. Conflict of interest: none