

## Case report

# Melanocytoma of the optic disc – a case report

Sharma H, Puri L R  
Sagarmatha Choudhary Eye Hospital, Lahan, Siraha, Nepal

### Abstract

**Introduction:** Melanocytoma of the optic disc is a benign lesion. **Objective:** To describe a case of optic disc melanocytoma **Case:** A 48-year old lady presented with gradual visual impairment associated with a floater. The right eye fundus examination showed a mass uniformly dark black in colour on the optic disc. The mass completely obscured the fluorescence on fluorescein angiography and was thus differentiated from malignant melanoma. **Conclusion:** Optic disc melanocytoma can present with visual impairment and a floater. Fluorescein angiography can be useful to differentiate between malignant melanoma and melanocytoma.

**Keywords:** Optic disk melanocytoma, diminution of vision, fluorescein angiography

### Introduction

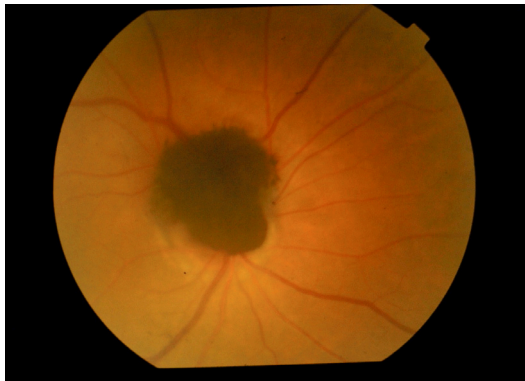
Melanocytoma is also known as magnocellular nevus. It is a benign, stationary heavily pigmented tumor that may develop wherever uveal melanocytes are present and most commonly occur on or adjacent to the optic disc with little potential for growth (Zimmerman, 1962). They are typically unilateral and rarely undergo a malignant transformation. Melanocytomas are classically asymptomatic lesions causing no appreciable change in the visual acuity except in the case of malignant transformation, extensive necrosis, or large size. At early stages, malignant melanomas can mimic a melanocytoma, thereby causing diagnostic difficulty. Considering its rarity and the diagnostic dilemma, we report a case of optic disc melanocytoma to describe its clinical features and the method of its diagnosis.

### Case report

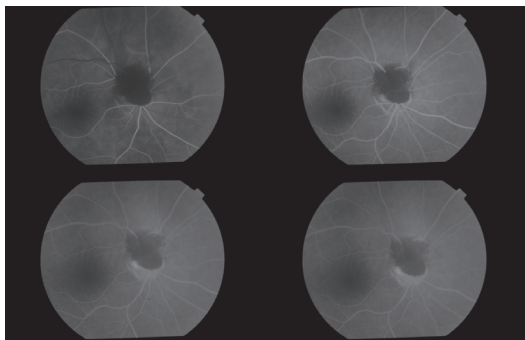
A 48-year old, dark skinned, female patient presented with gradual progressive diminution of vision associated with floaters in right eye. Her

distant visual acuity was 6/60 in the right eye and 6/24 in the left eye. The slit-lamp bio-microscopy revealed a normal anterior segment except for immature senile cataracts in both eyes. General and systemic examination revealed no abnormalities. Her right eye fundus showed a uniformly black, raised mass sitting on the optic disc, occupying the superior two thirds. It extended into the adjacent retina for one disc diameter in the supero-temporal quadrant (Figure – 1). The surface was smooth and the course of the blood vessels over it was undisturbed.

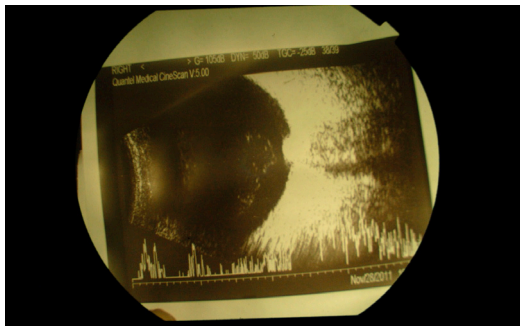
The remaining portion of the posterior segment was normal. No abnormality was detected in the left eye. Intraocular pressure was 10 mmHg in both eyes. Upon examination with fluorescein angiography, the mass was found to completely the underlying disc and choroidal fluorescence (Figure - 2). The B-scan ultrasonography (Figure-3) showed a round elevated lesion with high internal reflection. The Goldmann perimetry showed an enlargement of the blind spot ( Figure-4).



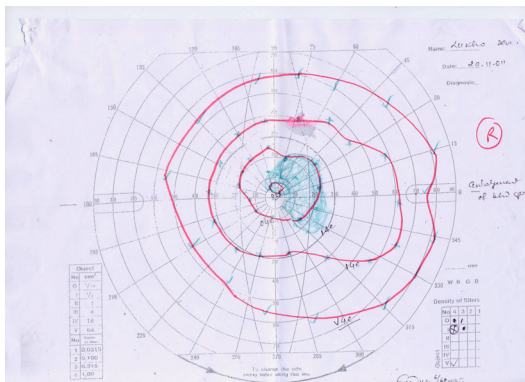
**Fig 1**



**Fig 2**



**Fig 3**



**Fig 4**

## Discussion

Melanocytoma is a special type of nevus that can occur anywhere these types of cells are present, including the iris, ciliary body, and the optic disc. The lamina cribrosa of the optic nerve head, with its population of melanocytes, is the origin of these pigmented lesions on the optic nerve (Riedly et al, 1985).

Melanocytoma of the optic disc is more rare than melanocytoma of the uvea. Ophthalmoscopically, it appears uniformly black with fibrillate margins due to infiltration into the adjacent retina. Some patients have afferent papillary defects and nerve fibre bundle defects, possibly due to nerve fibre layer compression. Histopathologically, the tumor cells are round or slightly polyhedral with distinct borders and small, round, normochromic nuclei. Melanocytoma commonly involves the inferotemporal aspect of the optic disc but, in this patient, it was located superiorly. On examination, the diagnosis strongly favoured was melanocytoma for the following reasons: a) Dark skinned female individual: melanocytoma is more common in blacks and those with dark complexions. b) Normal visual acuity: Malignant melanoma that involves the optic disc usually produces a profound diminution of vision with disc oedema, retinal haemorrhages, and retinal detachment. Vision in our patient was reduced due to cataracts, though some may be attributed to the melanocytoma. c) The mass was dark black with uniform pigmentation: Malignant melanoma usually presents with less pigmentation pattern. d) Fluorescein angiography showed a blocked fluorescence characteristic of the melanocytoma, unlike alternating areas of hyper-fluorescence and hypo-fluorescence which are present in malignant melanoma.

In a case of melanocytoma, Zimmerman et al (1962) reported the occurrence of a sudden decrease in vision with papillitis and retinal haemorrhages due to ischemic necrosis. Malignant melanoma was suspected and the eye was enucleated. Such incidences have occurred in the

past. For example, Reidy et al ( 1985) observed one a melanocytoma of the optic disc which was followed for 17 years, and suddenly transformed into a malignant melanoma.

A sudden decrease in vision or increase in size should be viewed with caution as an indication of transformation into malignant melanoma. Other factors, such as like acute vascular change, necrosis or a haematoma in a melanocytoma, though rare, should be carefully monitored. It may be difficult to distinguish between a melanocytoma and a malignant melanoma in early stages, when the ultrasonic examination is not helpful and fluorescein angiography can be misleading. Therefore, it is essential to maintain close, continuous observations and perform serial colour the importance of close continuous observations and serial colour fundus photography at every visit, so as to monitor the size and the rate of growth of the tumour and to guard against malignant transformation.

The role of spectral-domain optical coherence tomography has also been described as a useful

tool in diagnosing and monitoring the optic disc melanocytoma (Punjabi OS, 2011).

### Conclusion

Melanocytoma of the optic disc can present with visual diminution and floaters. The condition can be differentiated from malignant melanoma by the fundus fluorescein angiography.

### References

Punjabi OS, Lin CF, Chung HS, Gill MK (2011). Melanocytoma of the optic disc associated with visual field defects: clinical features and imaging characteristics. *Ophthalmic Surg Lasers Imaging*;42 :e75-80. Online 2011 Aug 11.

Reidy JJ, Apple DJ, Steinmetz RL (1985). Melanocytoma: nomenclature, pathogenesis, natural history and treatment, *Surg Ophthalmol*; 29: 319-327.

Zimmerman LE, Garron LK (1962). Melanocytoma of the optic disc. *Int Ophthalmol Clinic*; 2:431.

Source of support: nil. Conflict of interest: none