

## Case report

### Tuberculous dacryoadenitis in a child

Chakraborti C, Biswas R, Mondal M, Muknopadhy U, Datta J  
Department of Ophthalmology, Calcutta National Medical College and Hospital  
Kolkata - 700014, India

#### Abstract

**Background:** Orbital tuberculosis is rare even in endemic areas. The disease may involve soft tissue, lacrimal gland, or the periosteum or bones of the orbital wall.

**Case:** We present an Indian girl, who presented with a slowly growing left-sided superotemporal orbital mass, with no significant previous medical history. The swelling turned to an abscess and burst spontaneously giving rise to a discharging sinus. The discharge was negative for any organism on Gram and Giemsa staining. A tuberculin skin test was strongly positive. Incisional biopsy showed caseating granuloma and Langhan's giant cells suggestive of tubercular aetiology. The patient responded well to tuberculous chemotherapy.

**Conclusion:** Although tuberculous dacryoadenitis is a very rare manifestation of tuberculosis, still the possibility should be entertained in a slowly growing mass of the lacrimal gland, especially in developing countries where the prevalence of tuberculosis is high.

**Key words:** Tuberculosis, lacrimal gland, histopathology

#### Introduction

Tuberculous dacryoadenitis is an uncommon clinical entity with the diagnosis usually made on the basis of histopathological examination of the lacrimal gland (Bansal et al 2006). Malignancy, developmental anomalies, and nontuberculous infections are the common orbital lesions noted in children (Oakhill et al 1982). Orbital tuberculosis is relatively more common in children, girls more likely to be affected than boys. The disease is usually unilateral and slowly progressive. The left orbit is more commonly involved than the right (Sen et al 1980). We report

a case of a 10-year old girl with tubercular dacryoadenitis presenting clinically as a slow growing left lacrimal gland swelling.

#### Case report

A 10-year-old Indian girl presented to the eye OPD with a slowly-progressive swelling of the left upper eyelid of three months duration. This was associated with mild pain. She had received several courses of oral antibiotics from private practitioners prior to reporting to our hospital. There were no known systemic disease, loss of appetite or loss of weight, exposure to tuberculosis. Her unaided visual acuity was 6/6 in both eyes. The left eye examination showed lateral ptosis with an S-shaped deformity of the lid [Fig.1]. A firm, non-tender mass was palpated in the supero-temporal orbit. There was no associated discharge or redness, and the mass was not warm or fluctuant. The extraocular

Received on: 12.01.2011 Accepted on: 29.05.2011  
**Address for correspondence:** Dr Chandana Chakraborti, MD  
Assistant Professor, Department of Ophthalmology  
Calcutta National Medical College,  
Sundari Mohan Avenue, Kolkata 700014  
A/1/1, Pearl Apartment  
50B, Kailas Bose Street  
Kolkata 700006  
Tel: +91-98301 58243, 9830082545, Fax: +91-33-22843582  
E-mail: cchakoptha@yahoo.com

movements were restricted in up-gaze. The bulbar conjunctiva was slightly injected temporally and there was no proptosis of the left eyeball. On everting the left upper lid a prominent lacrimal gland was seen. The pupils were equal in diameter and reactive to light. Dilated funduscopy was normal. The right eye examination was unremarkable. The general physical examination detected a left cervical lymphadenopathy. The patient refused hospital admission and was investigated at the OPD. The patient came back to us after one week with a discharging sinus over the swelling (Fig 2).

A blood test demonstrated Hb-10.4 gm/dl, leucocytes - 6500cells/cu mm, ESR 50 mm in 1<sup>st</sup> hour. The tuberculin skin test was strongly positive (14/14 mm). The Sputum was negative for acid-fast bacilli and culture for tuberculosis. The Chest X-ray showed a calcified lesion in the left hilum. The discharge was sent for smear and culture / sensitivity and the result was negative. A CT of the brain and orbit revealed a soft tissue mass at the antero-lateral aspect of the left orbit (Fig. 3a, Fig. 3b). The CT- guided FNAC was inconclusive, showing benign spindle and epithelial cells. Incisional biopsy was done to confirm the diagnosis and showed a granuloma composed of epithelioid cells, Langhan's giant cells, and caseous necrosis (Fig.4). The clinical diagnosis of tuberculous dacryoadenitis was made on the basis of the strongly-positive tuberculin skin test and the caseating granulomatous lesions in the specimen. The patient was started on an anti-tubercular regimen consisting of INH 5 mg/kg/day, rifampicin 10 mg/kg/day, pyrazinamide 25 mg/kg/day and ethambutol 20 mg/kg/day once daily for two months, followed by INH and rifampicin once daily in the same doses for the following four months. Resolution of the eye swelling occurred within a month.

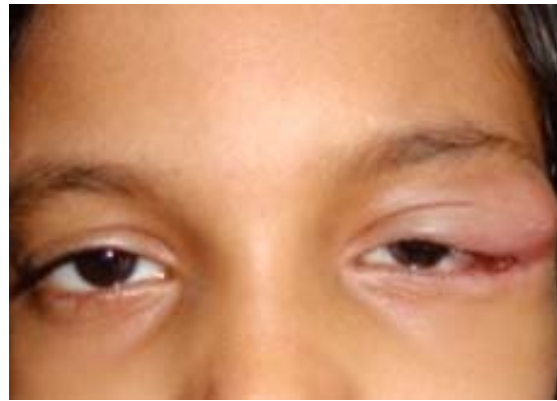

Fig-1: S-shaped deformity of the left upper eyelid

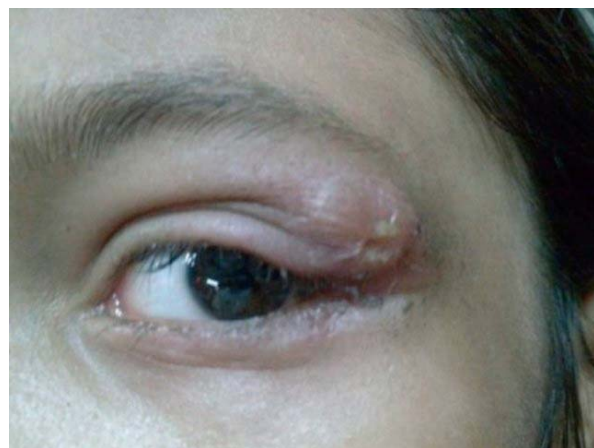

Fig-2: Discharging sinus

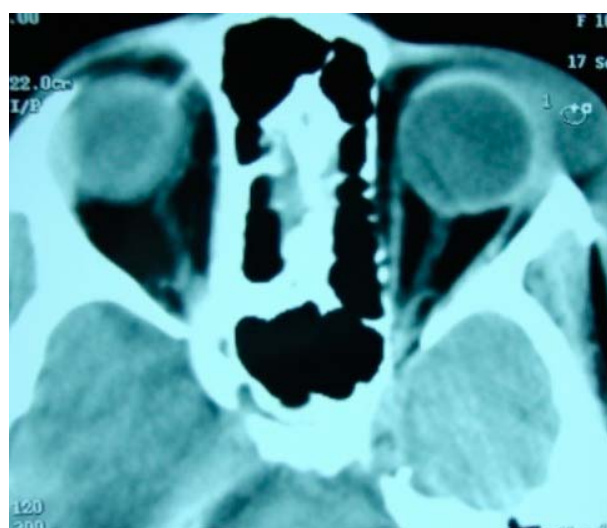

Fig-3a

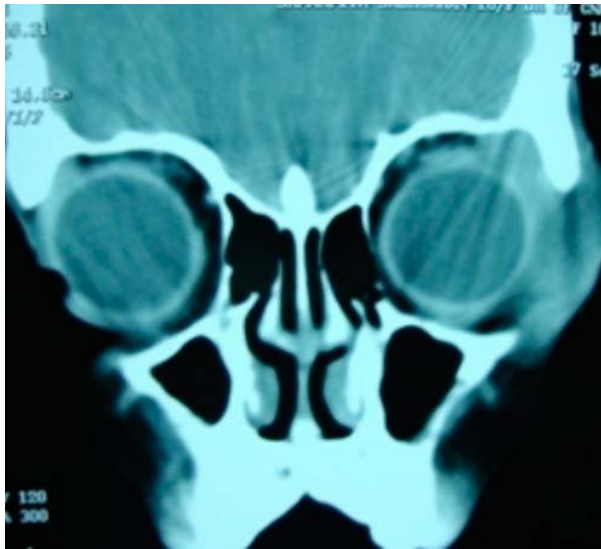


Fig-3b

Fig-3a & 3b: Soft tissue mass at antero-lateral aspect of orbit

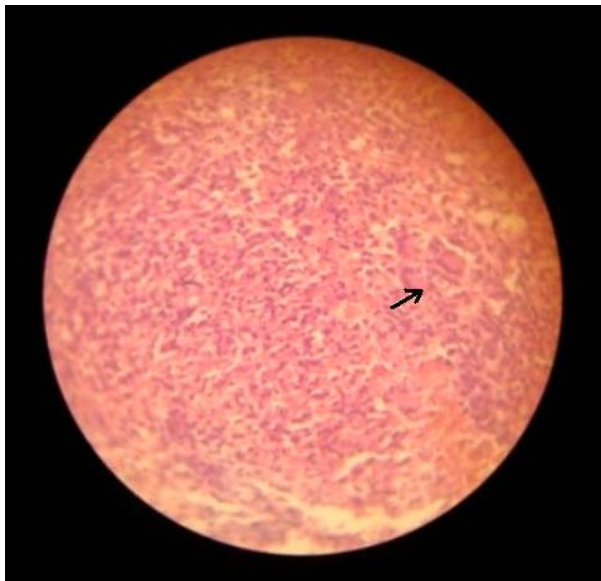

Fig-4: Tubercular granuloma

## Discussion

Tuberculous dacryoadenitis was first described by Abadie in 1881. Helm and Holland reviewed 43 patients with histological evidence of orbital tuberculosis and found lacrimal gland involvement in only 8 (14 %) patients (Bansal et al 2006). Van

Assen et al (2002) reported tubercular dacryoadenitis in a 4-year-old Somalian female. Agrawal et al (1977) found only one case of lacrimal gland involvement out of 14 cases of orbital tuberculosis in India, during a period of 5 years. Schmoll et al (2009) reported a 14-year-old Scottish teenager with tubercular dacryoadenitis with a rapidly- enlarging orbital mass. Isolated involvement of the lacrimal gland has also been described (Mortada et al 1971). It may be seen either in the form of lacrimal gland enlargement or abscesses. Two histological types of dacryoadenitis can be distinguished, the sclerotic and the caseous type, the latter being extremely rare (Van Assen et al 2002). Madhukar et al (1991) reported tubercular dacryoadenitis with abscess formation in a 17-year-old girl.

The chronic inflammatory lesions involving the orbit are usually of unknown aetiology. Clinically, these lesions may be mistaken for neoplasm and may simulate a pseudo tumour. Most of these inflammatory reactions are non-granulomatous. Truly granulomatous lesions rarely involve the orbit and tubercular involvement is particularly very rare (Suneetha et al 2000). The presenting symptoms of tuberculous dacryoadenitis are usually a painless swelling of the eyelid, mimicking a benign, mixed tumour of the lacrimal gland. There may be periostitis of the orbit. It is mostly found years after the resolving of a pulmonary or lymph node tuberculosis (Van Assen et al 2002).

Pyogenic bacteria such as staphylococcus aureus and streptococci are the most common causes of acute dacryoadenitis; however, in such cases, the presentation is more fulminant, the symptoms are of shorter duration and the patient is usually systemically toxic. Nevertheless, suspicion of this organism must be entertained as the treatment is different from that of a tubercular aetiology. Chronic infections of the lacrimal gland occur in tuberculosis, syphilis, leprosy and schistosomiasis (Van Assen et al 2002).

The spread of *M. tuberculosis* to the lacrimal gland is thought to be mainly haematogenous. Spread to

the lacrimal gland also occurs directly from primary conjunctival tuberculosis (Bansal et al 2006). Involvement of the lateral wall of the orbit suggests a haematogenous source of infection (Narula et al 2010). The acid-fast bacilli may lie dormant in the lacrimal gland and become reactivated later when the body's resistance decreases (Bansal et al 2006). In our patient, the lacrimal gland involvement was probably of haematogenous origin.

Isolation of *M.tuberculosis* is required for the definitive diagnosis, but positive culture from lacrimal gland secretions or from fine needle aspirations are extremely rare.

We believe that the differential diagnosis in patients with enlargement of the lacrimal apparatus should also include tuberculous dacryoadenitis, especially when originating from endemic areas. The systemic history of the patient, including past history of exposure to tuberculosis suggestive of pulmonary tuberculosis and nutritional status, should be completely evaluated in patients with lesions suggestive of tubercular aetiology. The diagnosis and management of these lesions depend on the close coordination of the ophthalmologist, microbiologist, pathologist, radiologist and physician. The treatment of these lesions is highly successful, without any sequelae, provided prompt ATT is instituted.

## References

Agrawal P K, Nath J, Jain B S (1977). Orbital involvement in tuberculosis. *Indian J Ophthalmol*; 25:12-6.

Bansal R K, Malhotra C, Bhatia Rozi, Chhabra S, Sood S. (2006) Tubercular dacryoadenitis – a case report and review of literature. *Indian J Pathol Microbiol*; 49:385-7.

Madhukar K, Bhide M, Prasad CE, Venkatramayya. (1991) Tuberculosis of the lacrimal gland. *J Trop Med Hyg*; 94:150-1.

Mortada A (1971). Tuberculoma of the orbit and lacrimal gland. *Br J Ophthalmol*; 55:565-66.

Narula M K , Chaudhary V, Baruah D, Kathuria M, Anand R ( 2010). Pictorial essay: Orbital tuberculosis. *Indian J Radiol Imaging*; 20: 6-10.

Oakhill A, Shah K J, Thompson A G, Stokes M J, Mann J R (1982). Orbital Tuberculosis in Childhood. *Br J Ophthalmol*; 66:396-7.

Schmoll C, MacRae M, Mulvihill A, Murray R, Cunningham S, McKenzie K (2009). Tuberculous dacryoadenitis in a Scottish teenager. *Br J Ophthalmol*; 93 :137-8.

Sen D K. (1980). Tuberculosis of the orbit and lacrimal gland: a clinical study of 14 cases. *J Paediatr Ophthalmol Strabismus*; 17: 232-8.

Suneetha N, Battu RR, Thomas RK. (2000). Orbital abscess: Management and outcome. *Indian J Ophthalmol*; 48:129-34.

Van Assen S, Lutterman J A (2002). Tuberculous dacryoadenitis: a rare manifestation of tuberculosis. *Neth J Med*; 60:327-9.

Source of support: nil. Conflict of interest: none