

Case report

Ophthalmomyiasis in humans

Chakraborti C¹, Mukhopadhyaya U², Mondal M³, Giri D³, Khan M⁴

¹Calcutta National Medical College, Kolkata, West Bengal, India

²Department of Ophthalmology, RIO, Kolkata

³Department of Ophthalmology, Calcutta National Medical College and Hospital

⁴IPGMER, Kolkata

Abstract

Background: Ophthalmomyiasis in humans is a rare phenomenon.

Objectives: To create awareness among the ophthalmologists regarding larval conjunctivitis.

Cases: We report two cases of ophthalmomyiasis, which came to a tertiary care centre with features of unilateral acute catarrhal conjunctivitis.

Observations: Fly larvae were detected on slit-lamp examination and removed after immobilizing them with topical 4 % lignocaine. Topical antibiotics and steroid drops were prescribed for 2 weeks. The samples were identified as *Oestrus ovis* by the entomology department of the Institute of Tropical Medicine, Kolkata. The signs and symptoms regressed within 48 hours.

Conclusion: The ocular myiasis can manifest as a unilateral catarrhal conjunctivitis.

Key words: Ophthalmomyiasis, *Oestrus ovis*, conjunctivitis

Introduction

Myiasis is the invasion of animal tissues by fly larvae (Ziemianski et al 1980; Steadly et al 1982; Pandey et al 2009). Ophthalmomyiasis is < 5 % of all human myiasis (Ziemianski et al 1980, Pandey et al 2009). The infection is specific or facultative and occurs in human eyes by maggots or bots of certain flies, the cyclorhapid and oestridae (Narayanan et al 1991). Cattle, sheep, horse, deer and rodents are the hosts. Man is an accidental host (Pandey et al 2009). Infestation in humans is through penetration of intact skin, orbit or nasal cavities. Ticks, mosquitoes and even patient's hands may transport eggs and larvae to the ocular surface (Farahvash et al 1998). An insect bite has no role in

the causation of ophthalmomyiasis. It is classified as ophthalmomyiasis externa (OE) when larvae are present on the conjunctiva, and ophthalmomyiasis interna (OI) when there is intraocular penetration (Pandey et al 2009). We report two cases of OE. To the best of our knowledge, no such case has been reported from eastern India.

Case reports

Case 1 : A 35 - year old shopkeeper, resident of a slum area, presented in March 2010 with stinging sensation in his left eye (LE) after taking a bath. His medical and family history was unremarkable. Visual acuity (VA) was 20/20 in both eyes (BE). RE was normal. LE showed mild conjunctival congestion. Slit-lamp (S/L) examination revealed highly motile thread like structures (Fig 1), 5 to 6 in number, slightly translucent, flattened with a black head end, on the conjunctiva. They actively avoided the light of the S/L trying to escape into the

Received on: 11.01.2011 Accepted on: 05.04.2011
Address for correspondence: Dr Chandana Chakraborti
Calcutta National Medical College,
Kolkata, West Bengal, India
A/1/1, Pearl Apartment,
50B Kailas Bose Street, Kolkata-700006

conjunctival fornices. No other abnormalities were detected. Anaesthetizing the eye with 4 % lignocaine hydrochloride, the thread like structures were removed with plain forceps followed by copious irrigation with normal saline. Gatifloxacin and dexamethasone eye drops were advised four times daily and the patient became symptom free after 48 hours.

Case 2: A 24-year old cobbler attended the OPD in April 2010 with redness, watering and irritation in LE for 1 day. A resident of a slum area, his medical and family history was unremarkable. VA was 20/20 in BE. Conjunctiva of LE was congested. S/L examination showed highly motile 6 to 7 thread like structures on the conjunctiva. No other abnormalities were detected. RE was normal. Management was similar to Case 1 with complete resolution by 48 hours. Specimens from both cases were identified as larvae of *Oestrus ovis* (Fig 2).

Legends

Fig 1 Larva on the conjunctiva

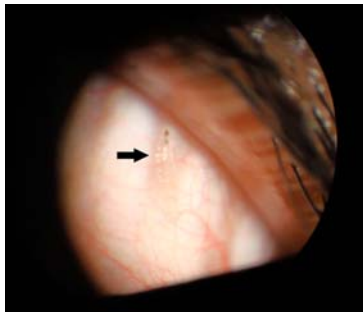
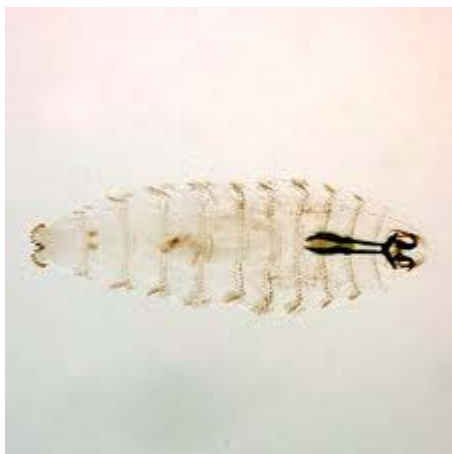


Fig 2 *Oestrus ovis* larva (x 40)



Discussion

Ophthalmomyiasis due to *O ovis* was described first in 1947 by James Pandey et al (2009). Such cases have been reported mainly from agricultural areas (Pandey et al 2009; Sigauke et al 2003). Our cases are from urban slum areas where livestock abound and are the possible source of the fly larvae. Most cases occur in spring and summer (Pandey et al 2009). Other genera of fly larvae may cause ophthalmomyiasis (Sigauke et al 2003). Though OE is occasionally observed, OI is rare and more common in children.

The fly deposits its larvae in the conjunctival sacs of humans, the females being supposedly capable of ejecting a jet of larvae while in close proximity to the eye (Narayanan et al 1991, Sigauke et al 2003). OE manifests as acute catarrhal conjunctivitis with symptoms similar to our cases. The patient may present with burning, itching, mobile foreign body sensation, photophobia, watery discharge, and eyelid cellulitis. It may be asymptomatic too. It can present as conjunctival pseudomembrane, follicular conjunctivitis, punctate keratopathy, corneal ulcer and conjunctival cyst (Sigauke et al 2003; Smith, 1960). The larva may die forming a permanent nodule which macroscopically resembles a sty (Sigauke et al 2003).

Tissue destruction is caused by a symbiosis between the larvae and proteolytic bacteria like *Staphylococcus aureus*, *Staphylococcus epidermidis*, *Pseudomonas*, *Moraxella* and *Chlamydia trachomatis* carried by the maggots. The larva destroys the tissue with a toxin, making protein available for the bacterial proteolytic enzymes. Enzymatic digestion provides nutrients for the maggot (Farahvash et al 1998). The fly enters the nostrils and deposits its larvae which eventually crawl and reach the brain cavity (Jayaprakash et al 2008). In OE, VA is not usually hampered. In OI, visual loss may be the result of intra-ocular inflammation, uveitis, retinal detachment, extension of sub-retinal tract or invasion of optic nerve head.

Normal saline irrigation is unsuccessful in washing out the larvae because they grab the conjunctiva firmly with hooks (Pandey et al 2009). Ophthalmomyiasis, though a rare phenomenon affecting laborers in the agricultural sector, can affect urban people living usually in a poor hygienic environment with no history of direct contact with livestock. Early detection, thorough S/L examination and careful extraction of the larva is essential to avoid complications.

References

Farahvash MS, Harandi ZA (1998). Bilateral Ophthalmomyiasis Inertna Posterior: Report of a case with severe visual loss. http://www.ams.ac.ir/aim/9812/farahvash_9812.html (date of access: 10.08.2010)z

Jayaprakash K and Karthikeyan A. (2008). Ocular myiasis and associated mucopurulent conjunctivitis acquired occupationally :A case study. *Indian J Occup Environ Med*; 12 : 20-22.

Narayanan S, Jayaprakash K. (1991) Incidence of ocular myiasis due to infection with the larva of oestrus ovis (Oestridae Diptera). *Indian J Ophthalmol*; 39: 176-178.

Pandey A, Madan M, Asthana AK, Das A, Kumar S, Jain K. (2009). External Ophthalmomyiasis Caused by Oestrus ovis: A Rare Case Report from India. *Korean J Parasitol* 2009; 47: 57-59.

Sigauke E ,Beebe WE , Gander RM,Cavuoti D , and Southern PM (2003). Case Report: Ophthalmomyiasis Externa in Dallas County,Texas. *Am. J. Trop. Med. Hyg*; 68:46- 47.

Smith R. (1960). Ophthalmomyiasis in England.Br.J. *Ophthalmology*; 35: 242-243.

Steadly LP, Peterson CA. (1982). Ophthalmomyiasis. *Ann Ophthalmol*; 14: 137-139.

Ziemianski MC, Lee KY, Sabates FN (1980). Ophthalmomyiasis interna. *Arch Ophthalmol*; 98:1588-1589.

Source of support: nil. Conflict of interest: none