

## Bilateral Optic Neuritis in a Child with Acute Disseminated Encephalomyelitis: A Case Report

Meenakshi Wadhvani<sup>1</sup> , Amit Kumar<sup>1</sup>, Dhulika Dhingra<sup>2</sup>

<sup>1</sup>Department of Ophthalmology, Chacha Nehru Bal Chikitsalya, New Delhi, India

<sup>2</sup>Department of Paediatrics, Chacha Nehru Bal Chikitsalya, New Delhi, India

### ABSTRACT

**Background:** Acute disseminated encephalomyelitis is an inflammatory demyelinating disease of the central nervous system following a viral illness or vaccination, which occurs most often in children as a monophasic event. The neurological signs typically appear days to weeks after an initial febrile infection (usually of the upper respiratory tract) or vaccine immunisation.

**Case:** An eight year old boy presented with painless progressive diminution of visual acuity for two days, On ophthalmic examination his visual acuity was hand movements at a close range in both the eyes. Posterior segment examination revealed bilateral optic disc swelling,

**Observations:** Magnetic Resonance Imaging (MRI) brain revealed multiple discrete ovoid hyperintense lesions in bilateral cerebral white matter. His contrast enhanced MRI orbit study revealed bilateral oedematous optic nerve.

**Conclusion:** Optic neuritis can present with different systemic conditions. Thorough ocular examinations (visual acuity, colour vision, contrast sensitivity, fundus examination) and neuroimaging should be done in all the cases. Early diagnosis and management is required for good visual prognosis.

**Key words:** Encephalomyelitis; optic disc oedema; optic nerve; optic neuritis; visual acuity.

Financial Interest : Nil

Received : 10.01.2023

Conflict of Interest : Nil

Accepted : 01.08.2023

#### Corresponding Author

Dr. Meenakshi Wadhvani

Assistant Professor, Chacha Nehru Bal Chikitsalya,  
New Delhi, India.

E-mail: mkgang08@gmail.com



Access this article online

Website: [www.nepjol.info/index.php/NEPJOPH](http://www.nepjol.info/index.php/NEPJOPH)

DOI: <https://doi.org/10.3126/nepjoph.v15i2.51347>

Copyright © 2023 Nepal Ophthalmic Society

ISSN: 2072-6805, E-ISSN: 2091-0320



This work is licensed under a Creative Commons Attribution-NonCommercial-NoDerivatives 4.0 International License (CC BY-NC-ND).

## INTRODUCTION

Acute disseminated encephalomyelitis is an inflammatory demyelinating disease of the central nervous system following a viral illness or vaccination, relapse or recurrence too have been reported though the disease is usually monophasic. The neurological signs typically appear days to weeks after an initial febrile infection (usually of the upper respiratory tract) or vaccine immunisation. Neuroimaging and clinical presentation are able to differentiate between the two clinical conditions of acute disseminating encephalomyelitis (ADEM) and multiple sclerosis (MS) as the former presents with multiple clinical presenting symptoms (polysymptomatic) and Multiple sclerosis has single symptom (monosymptomatic) (Dale et al., 2005; Hsu et al., 2012)

Ophthalmological manifestations in the form of optic neuritis may occur in MS, Neuromyelitis optica (NMO), and ADEM. Although

bilateral optic neuritis with speedy recovery after administration of intravenous steroids is believed to occur more often in the latter condition. We report the case of a young boy with sudden visual loss related to a bilateral oedematous optic neuropathy most probably associated with ADEM.

## CASE REPORT

An eight year old boy presented with complaints of blurred vision, confusion, headache for 15 days. There was a history of fever two months back. On ophthalmic examination his visual acuity was hand movement in close range in both the eyes. Posterior segment examination revealed bilateral optic disc swelling (Figure 1a,b). Colour vision and contrast sensitivity could not be done due to impaired visual acuity. The child was advised retinal nerve fibre layer optical coherence tomogram but parents could not get it done due to financial constraints. Systemic examination and blood investigation

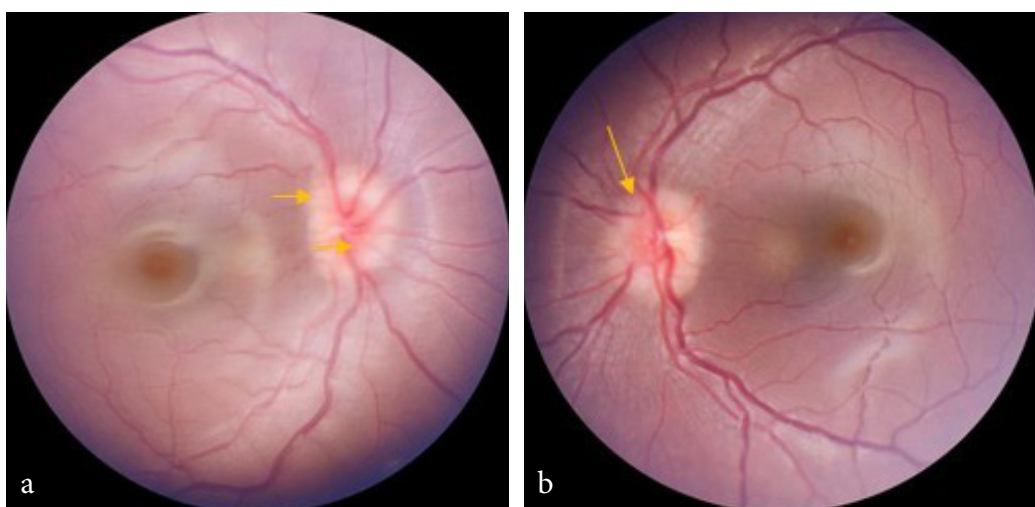
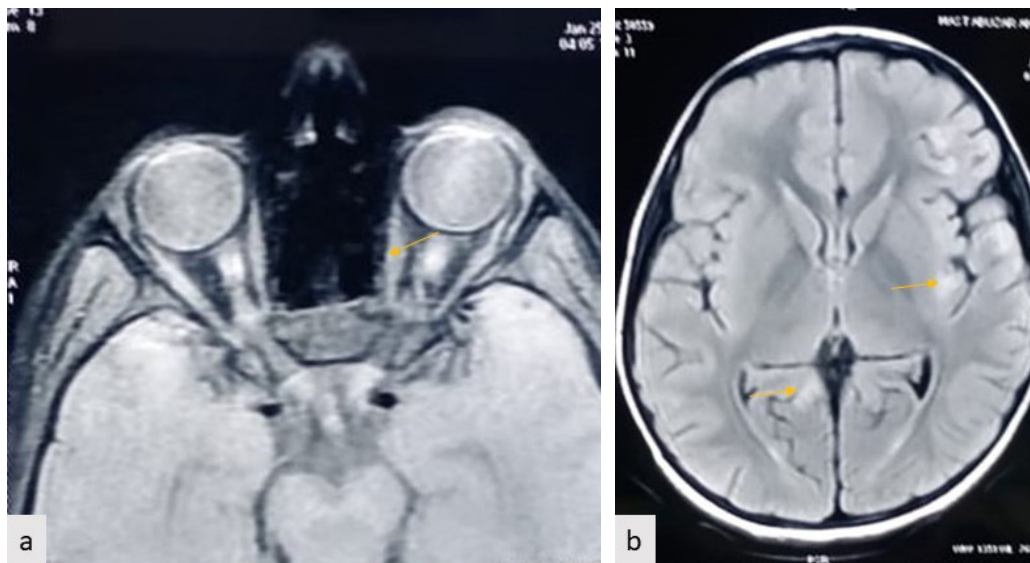


Figure 1: (a, b) Posterior segment examination revealed bilateral optic disc swelling



**Figure 2: MRI scan of case 1 (a) Bilateral oedematous optic nerve with transverse diameter of optic disc of 8.5 mm in OD and 8 mm in OS indicating increased perineural fluid underneath nerve sheath. (b) Multiple discrete ovoid hyperintense lesions in bilateral cerebral white matter.**

were within normal limits. Magnetic Resonance Imaging (MRI) brain revealed multiple discrete ovoid hyperintense lesions in bilateral cerebral white matter. His contrast enhanced MRI orbit study revealed bilateral oedematous optic nerve with transverse diameter of optic disc of 8.5 mm in right eye (OD) and 8mm in left eye (OS) indicating increased perineural fluid underneath nerve sheath (Figure 2a). Along with fraying and irregularity of both the optic nerve in its distal aspect in the region of orbital apex and its intracanalicular segment (Figure2b). A provisional diagnosis of optic neuritis was made. He was started on Methylprednisolone pulse therapy at the rate of 500 mg once a day for five days after monitoring of vitals. He underwent Lumbar puncture that had increased proteins but absent oligoclonal bands. His

visual acuity restored to 6/60 in both eyes on day five. He was discharged on a tapered dose of oral prednisolone at a dose of 1mg/kg for two months. His visual acuity at two weeks follow-up was 6/24 in OD and 6/36 in OS with impaired coloured vision. At 12 weeks follow-up visual acuity was 6/12 in both eyes and normal colour vision. Fundus examination revealed resolved disc edema with temporal disc pallor in both the eyes. The parents refused for undergoing serum aquaporin-4 autoantibody (anti-AQP4) and myelin oligodendrocyte glycoprotein (MOG) antibody evaluation due to lack of affordability as MOG-abs seropositivity and AQP4-abs seronegativity could have confirmed the diagnosis of ADEM. His repeat MRI orbit after three months revealed resolved optic nerve head thickening,

## DISCUSSION

Optic neuritis is quite rare in paediatric patients (0.15-0.57 per 100000 children/year) as compared to adult-onset optic neuritis (1-2 per 100000 person/year) (Ambika et al., 2018).

Inflammatory condition of bilateral optic nerve is most common post viral prodrome like measles, mumps, varicella, although optic neuritis is a common feature of ADEM but differentiating it from MS is very important and difficult.

The main differentiating feature between ADEM is that ADEM generally affects children in the age group of 6- 9 years whereas MS presents in elder age group. The systemic presentation of ADEM is polysymptomatic with the neurological symptoms in the form of headache, confusion, disorientation along with bilateral optic neuritis. Cerebrospinal fluid (CSF) cytology also reveals increased proteins and absence of oligoclonal bands in ADEM whereas MS has monosymptomatic presentation with unilateral optic neuritis along with absence of proteins and presence of oligoclonal bands in CSF.

Another important differential diagnosis of ADEM is NMO that was ruled out by immediate recovery after administration of intravenous steroids and is characterised by presence of diencephalic involvement in MRI brain.

In the Index case, the patient presented as bilateral optic neuritis with associated

polysymptomatic neurological signs in the form of confusion, headache and neuroimaging revealed hyperintense lesions in the bilateral white matter of the brain, with lumbar puncture suggestive of pleocytosis with the absence of oligoclonal bands favouring the diagnosis of ADEM. Visual acuity in optic neuritis may vary between 6-18- 6/60. Vision loss in optic neuritis may occur over several hours to days, can worsen for 1-2 weeks.

On comparing the index case with the previous reported cases in literature (Ryu et al., 2014; Nagashima et al., 2018; Miyauchi et al. 2014) it was found that loss of colour vision was out of proportion to the loss of visual acuity is characteristic of optic neuropathies. (Hsu et al., 2012; Serra et al., 2020) The most common patterns of colour vision loss in optic neuritis are protanopia and deuteranopia (Table 1). In Index case also loss of both red and green colour was present, besides, this delayed latency of P50 on visually evoked potential was present in all the cases (Ryu et al., 2014; Nagashima et al., 2018; Miyauchi et al. 2014, Serra et al., 2020).

Intravenous methylprednisolone was used as a treatment in all the cases either alone or along with immunomodulators. A good recovery of visual acuity was achieved in our case because of early diagnosis and prompt management. This is the fourth case of a detailed paediatric optic neuritis case from India although previously reported cases are a part of retrospective workup.

**Table 1: Detailed presentation of pediatric optic neuritis in acute disseminated encephalomyelitis in children up to 10 years.**

Author	Current Case 2022	Hsu et al. <sup>2</sup> 2012	Ryu et al. <sup>5</sup> 2014	Miyauchi et al. <sup>7</sup> 2014	Nagashima et al. <sup>6</sup> 2018	Serra et al 2021 <sup>8</sup>	Ambika et al 2020 <sup>3</sup>
Age (in years)	8	8	6	5	4.7	10	8 (4 children)
Visual acuity	6/36	RE- HM LE- 6/60	NA	NA	NA	NA	NA
Colour vision	RE-7/21 LE-6/21	BE-1/21	NA	NA	NA	RE-1/50	NA
Fundus	Disc edema	Disc edema	Disc edema	Disc edema	Disc edema	Disc edema	Disc edema
MOG-abs seropositivity	NA	NA	NA	YES	YES	YES	NA
VEP	Bilateral increased latency	NA	NA	NA	NA	RE Increased latency	NA
MRI	Hyperintense lesions in bilateral cerebral white matter with optic neuritis	Multiple hyperintensities in the subcortical white matter	NA	NA	Typical for ADEM	Right optic nerve: Hyperintensity contrast enhancement ADEM outcomes	Hyperintense lesions in bilateral cerebral white matter with optic neuritis
Management	Intravenous Methyl prednisolone	Intravenous Methyl prednisolone	corticosteroid	NA	Intravenous Costecosteroid, Rituximab, Azathioprine	Intravenous Methyl Prednisolone	Intravenous Methyl Prednisolone
Recover vision	BE 6/12	RE- CF LE- 6/7.5	NA	NA	NA	Gradual partial recovery	More than 6/12 in 3 children

NA-not available, CF-counting finger

## CONCLUSION

Optic neuritis can present with different systemic conditions. Thorough ocular examinations (visual acuity, colour vision, fundus examination) and neuroimaging should be done in all the cases. Early diagnosis

and management is required for good visual prognosis. Prolonged follow-up is needed to rule out recurrent optic neuritis.



## REFERENCES

---

- Ambika S, Padmalakshmi K, Venkatraman V, et al. (2018). Visual outcomes and clinical manifestations of pediatric optic neuritis in Indian population: An institutional study. *J Neuroophthalmol*; 38: 462-5. DOI: [10.1097/WNO.0000000000000646](https://doi.org/10.1097/WNO.0000000000000646)
- Dale RC, Branson JA (2005). Acute disseminated encephalomyelitis or multiple sclerosis: Can the initial presentation help in establishing a correct diagnosis? *Archives of disease in childhood*; 90(6): 636-639. DOI: [10.1136/adc.2004.062935](https://doi.org/10.1136/adc.2004.062935)
- Hsu HC, Bee YS, Lin MC, et al. (2012). Isolated optic neuritis in acute disseminated encephalomyelitis-A case report. *Taiwan Journal of Ophthalmology*; 2(3):109-111. DOI: [10.1016/j.tjo.2012.02.001](https://doi.org/10.1016/j.tjo.2012.02.001)
- Miyauchi A, Monden Y, Watanabe M, et al. (2014). Persistent presence of the anti-myelin oligodendrocyte glycoprotein autoantibody in a paediatric case of acute disseminated encephalomyelitis followed by optic neuritis. *Neuropediatrics*; 45(03): 196-199. DOI: [10.1055/s-0034-1371179](https://doi.org/10.1055/s-0034-1371179)
- Nagashima M, Osaka H, Ikeda T, et al. (2018). Rituximab was effective for acute disseminated encephalomyelitis followed by recurrent optic neuritis with anti-myelin oligodendrocyte glycoprotein antibodies. *Brain and Development*; 40(7): 607-611. DOI: [10.1016/j.braindev.2018.03.011](https://doi.org/10.1016/j.braindev.2018.03.011)
- Ryu WY, Sohn EJ, Kwon YH, et al. (2014). Acute disseminated encephalomyelitis without optic neuritis followed by optic neuritis in a child due to the sudden cessation of steroid therapy. In *Seminars in Ophthalmology*; 29(1): 18-21. DOI: [10.3109/08820538.2013.835837](https://doi.org/10.3109/08820538.2013.835837)
- Serra M, Presicci A, Fucci M, et al. (2020). Acute disseminated encephalomyelitis followed by optic neuritis: A rare syndrome of uncertain treatment and prognosis. *Neuropediatrics*; 51(04): 286-291. DOI: [10.1055/s-0039-3402004](https://doi.org/10.1055/s-0039-3402004)
- Toosy AT, Mason DF, Miller DH (2014). Optic neuritis. *The Lancet Neurology*; 13(1): 83-99. DOI: [10.1016/S1474-4422\(13\)70259-X](https://doi.org/10.1016/S1474-4422(13)70259-X)
-