

■ **Original article**

A comparative study of combined small-incision cataract surgery with sutureless trabeculectomy versus trabeculectomy using W-shaped incision

Khurana AK, Chawla U, Passi N, Jyoti, Archana, Yogesh

Regional Institute of Ophthalmology, Pt BD Sharma, Post Graduate Institute of Medical Sciences,
Rohtak, Haryana, India

Abstract

Introduction: Manual small-incision cataract surgery with trabeculectomy is now an acceptable option in the surgical management of combined cataract and glaucoma uncontrolled with maximum tolerated medical therapy.

Objective: To compare the results and complications of combined manual small-incision cataract surgery (SICS) and posterior chamber intraocular lens (PCIOL) implantation with trabeculectomy by sutureless versus W-shaped incision technique.

Materials and methods: The study included 30 eyes of 28 patients with senile cataract and primary open-angle glaucoma (POAG) who were randomly divided into two groups. The patients in Group A (n = 15) underwent SICS with sutureless trabeculectomy and those in Group B (n = 15) underwent SICS with trabeculectomy using W-shaped incision with one suture. Post-operative evaluation was done at the first post-operative day and thereafter on follow-ups at 1 week, 2 weeks, 4 weeks and 8 weeks.

Results: The mean preoperative and postoperative intraocular pressure (IOP) in Group A was 27.33 ± 3.35 mmHg and 16.13 ± 4.30 mmHg respectively and in Group B it was 29.46 ± 6.06 mmHg and 14.66 ± 2.69 mmHg respectively. The mean reduction in IOP after 8 weeks of follow-up in Group A was 12.52 ± 3.59 mmHg and that in Group B was 16.47 ± 3.79 mmHg ($p < 0.001$). Besides this, the uncorrected visual acuity (UCVA) was better in Group B postoperatively with less surgically-induced against-the-rule (ATR) astigmatism.

Conclusion: Combined SICS with trabeculectomy using W-shaped incision offers better prospective in terms of glaucoma control and visual performance than sutureless combined surgery.

Key words: sutureless trabeculectomy, combined surgery, W-shaped trabeculectomy

Introduction

Manual small-incision cataract surgery with trabeculectomy is now an acceptable option in the surgical management of combined cataract and glaucoma uncontrolled with maximum-tolerated medical therapy, especially where phacoemulsification has a limitation of a long learning curve, where there is machine dependency and when

it is relatively difficult in situations like hard cataract, small pupil, etc (Dash et al 2006). Pantelis et al (1994) suggested a modification of the frown type incision for the implantation of rigid intraocular lens: a W-shaped incision. It has improved the control of astigmatism and self-sealing characteristics, needs no special requirement for suture material, has a high mechanical stability, and is easily extendible for extra-capsular cataract extraction (ECCE) or trabeculectomy. In combined surgery, it can also be used to "cover" a trabeculectomy located underneath, which controls leakage and over-filtration (Michielsens & Henneker, 1994). The present study was carried out to compare the results and complications of combined small-incision cataract

Received on: 03-03-2010 Accepted on: 12.06.2010
Address for correspondence:
Dr Urmil Chawla, MD
Assistant professor, Regional Institute of Ophthalmology
Pt BD Sharma, PGIMS, HN 62/9J Medical Campus, Rohtak
Haryana, India,
Email: urmil01@yahoo.com
Phone: 0091-9812545500

surgery (SICS) and posterior chamber intra-ocular lens implantation (PCIOL) with trabeculectomy by sutureless versus W-shaped incision technique.

Materials and methods

A randomized comparative study of 30 eyes of 28 hospitalized patients of either sex with POAG and cataract was carried out at the Regional Institute of Ophthalmology, Pt BD Sharma, Postgraduate Institute of Medical Sciences, Rohtak, Haryana. An informed consent was taken from all the patients. All the surgeries were performed by the same surgeon. The patients with cataract requiring surgery with coexistent POAG with IOP > 21 mmHg were included in the study. The patients with any other associated ocular disease, with previous ocular surgery and with diagnosed cases of secondary glaucoma were excluded.

History and clinical examination:

A detailed history regarding diminution of vision, headache or eyeache, colored haloes, dark spots in the field of vision, redness, photophobia, family history of glaucoma and history of drug intake was recorded. Any systemic illness and past history in relation to any ocular trauma, surgery, treatment or medications were enquired about. A complete ocular examination, including visual acuity measurement, slit-lamp examination, applanation tonometry, gonioscopy, perimetry, keratometry and biometry, was carried out. The patients were randomly divided into two groups (A & B). Group A (n = 15) included patients who underwent combined SICS with sutureless trabeculectomy. Group B (n=15) included the patients who underwent combined SICS with W-shaped incision trabeculectomy with one suture.

Surgical procedure

1. A fornix-based conjunctival flap was made at the limbus from 10 O'clock to 2 O'clock positions. Wet field cautery was done to maintain hemostasis.
2. In Group A, a partial thickness 'V' shaped scleral groove of 6 mm size was made superiorly 2 mm away from the limbus (Fig.1). In Group B, a partial thickness W-shaped scleral groove was made superiorly 2 mm away from the limbus (Fig.2). A scleral tunnel was dissected with a crescent knife, extending about 1.0 – 1.5 mm into clear cornea.

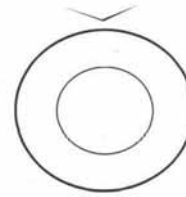


Fig. 1 Diagrammatic depiction of V shaped scleral groove.

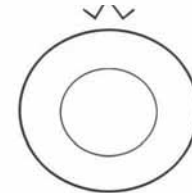


Fig. 2 Diagrammatic depiction of flattened W shaped scleral groove.

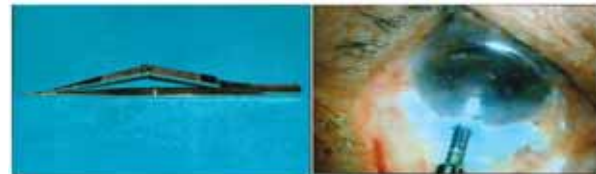

Fig.3 Kelly's Punch

Fig.4 Trabeculectomy with Kelly's Punch

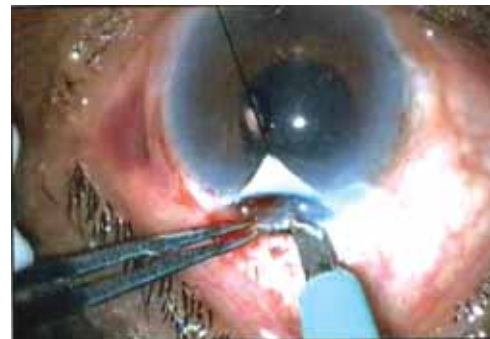

Fig.5

Trabeculectomy beneath triangular flap of W-shaped incision

3. A continuous curvilinear capsulorrhexis (CCC) about 6 mm in size was made.
4. Hydro-dissection was performed and the nucleus was prolapsed out into the anterior chamber and delivered. Cortical matter was aspirated and a PCIOL implanted in the capsular bag.
5. In Group A patients, AC was formed with viscoelastic. Kelly's punch (Fig.3) was used to punch out a piece of trabecular meshwork at the posterior limbus within the scleral tunnel (Fig.4). Irrigation and aspiration of viscoelastic was done using ringer lactate solution. In Group B patients, the central triangular part of the W-

shaped scleral flap was lifted and a block of deep sclera (1.5 × 2 mm) was excised using a razor blade fragment and corneal scissors (Fig.5). A peripheral iridectomy was done. The superficial triangular scleral flap was sutured by one 10 - 0 nylon suture at the apex of the flap.

- The conjunctival flap was repositioned back and anchored with the help of wet field cautery.

Post-operative evaluation:

Evaluation was done on the first post-operative day and thereafter on follow-up at 1 week, 2 weeks, 1 month (4 weeks) and 2 months (8 weeks).

Results

The mean age of the patients in Group A was 66.20 ± 10.37 years and that in Group B was 61.06 ± 11.39 years. The number of eyes operated on was 30 of 28 patients, out of which 13 (43.33 %) were males and 17 (56.67 %) were from female patients. Both eyes of 1 male and 1 female were included in the study. Group A included 7 (46.67 %) males and 8 (53.33 %) female cases. Group B comprised 6 (40 %) males and 9 (60 %) female cases. There were 11 cases of immature senile cataract (ISC) with POAG and 4 cases of mature senile cataract (MSC) with POAG in Group A. Group B had 12 cases of ISC with POAG and 3 cases of MSC with POAG.

In Group A, out of 15 cases, 12 (80 %) eyes had preoperative intraocular pressure (IOP) in the range of 21-30 mmHg (Table 1). Three (20 %) eyes had IOP between 31 - 40 mmHg. In Group B, IOP of 10 (66.67 %) eyes ranged between 21 - 30 mmHg and that of 4 (26.67 %), between 31 - 40 mmHg. One eye had IOP between 41 - 50 mmHg. The mean pre-operative IOP in Group A was 27.33 ± 3.35 mmHg and that in Group B was 29.46 ± 6.06 mmHg. A detailed optic disc evaluation was done in all cases whenever possible. The disc was not visualized in 4 cases of Group A and 3 cases of Group B. Glaucomatous changes of nasal shifting of blood vessels, thinning of neuro-retinal rim (NRR), optic disc hemorrhages, peri-papillary atrophy with special emphasis on cup : disc (C:D) ratio were looked for (Table 2). No patient in any group had a total glaucomatous optic atrophy. The mean C : D ratio in Group A was 0.57 ± 0.09 and in Group B, it was 0.62 ± 0.16. Visual field changes were observed in all cases preoperatively, in relation to Humphrey

glaucoma hemi-field 30 - 2 full threshold test (Table 3). Six (40 %) cases of Group A and 8 (53.33 %) cases of Group B were not able to perform the test due to poor vision. Nine (60 %) cases of Group A showed outside normal limits (ONL) changes while only 5 (33.33 %) cases of Group B had visual fields changes ONL. Only 2 (13.33 %) cases of Group B showed borderline changes.

The mean pre-existing with-the-rule (WTR) astigmatism in Group A was 0.6 ± 0.28 D seen in 33.33 % of cases and the mean against-the-rule (ATR) astigmatism was 0.86 ± 0.66 D seen in 60 % of cases. In group B, the mean preoperative WTR astigmatism was 1.0 ± 0.51 D in 40 % of cases and the ATR astigmatism was 0.81 ± 0.34 seen in 53.33 % of cases (Table 4).

Table 1
Preoperative intraocular pressure
(applanation tonometry)

Intraocular pressure (mmHg)	Group A	Group B
	No. of eyes (%)	No. of eyes (%)
21-30	12 (80)	10 (66.67)
31-40	3 (20)	4 (26.67)
41-50	0	1 (6.67)
>51	0	0

Table 2
Preoperative cup : disc ratio

C : D ratio	Group A	Group B
	No. of cases (%)	No. of cases (%)
0.4 :1	1 (6.67)	2 (13.33)
0.5:1	3 (20)	2 (13.33)
0.6:1	5 (33.33)	3 (20)
0.7:1	2 (13.33)	2 (13.33)
0.8:1	0	2 (13.33)
0.9:1	0	1 (6.67)
Glaucomatous optic atrophy	0	0
Disc not visualized	4 (26.67)	3 (20)

No intra-operative complications were seen in Group B while in Group A out of 15 eyes, 1 (6.67 %) had an iris prolapse intra-operatively and 1 (6.67 %) case had hyphema (Table 5). Postoperatively, the patients

Table 3
Preoperative visual field changes

Glaucoma hemi-field test (central 30-2 full threshold)	Group A	Group B
	No. of cases (%)	No. of cases (%)
Unable to test due to poor vision	6 (40)	8 (53.33)
Within normal limits	0	0
Generalized reduced sensitivity	0	0
Borderline	0	2 (13.33)
Outside normal limits	9 (60)	5 (33.33)

Table 4
Pre-operatively observed astigmatism

Astigmatism	Group A (no. of eyes)		Group B (no of eyes)	
	WTR	ATR	WTR	ATR
	0.25 D	1	3	-
0.50 D	2	1	3	1
0.75 D	1	2	-	3
1.0 D	1	-	-	1
1.25 D	-	1	1	2
1.50 D	-	-	1	-
1.75 D	-	1	1	-
2.0 D	-	1	-	-
> 2.0 D	-	-	-	-
Total	5	9	6	8

were observed for one day to see for any complications. In Group A, out of 15 cases, one (6.67 %) eye had shallow anterior chamber (AC). This patient was given pressure bandage following which the AC formed within 48 hrs. Three cases (20 %) had a raised IOP postoperatively. One case was well treated with topical anti-glaucoma therapy, but the rest two cases were not under control even with this therapy. Conventional trabeculectomy was carried out in 2 cases to bring the IOP under control. One case (6.67 %) had uveitis post-operatively that resolved within two weeks by topical steroid therapy, while in Group B only one case presented with uveitis postoperatively, which also resolved with topical

Table 5
Intra-operative and postoperative complications

Complications	Group A No of cases (%)	Group B No of cases (%)
Intra-operative complications		
Hyphema	1(6.67)	0
Perforation of scleral flap	0	0
Buttonholing of conjunctiva	0	0
Iris prolapsed	1(6.67)	0
Posterior capsular rent (PCR)/vitreous prolapse	0	0
Postoperative complications		
Shallow anterior chamber	1 (6.67)	0
Iris prolapsed	0	0
Corneal oedema	2 (13.33)	0
Retained cortical matter	0	0
Hyphaema	0	0
Uveitis	1 (6.67)	1 (6.67)
Raised IOP	3 (20)	1 (6.67)
Infection	0	0
Choroidal effusion	0	0

Table - 6
Postoperative intraocular pressure-Group A

IOP (mmHg)	1 st day	1 st week	2 nd week	4 th week	8 th week
<10	01	0	0	0	2
11-20	12	12	12	13	11
>21	2	3	3	2	2

steroid therapy. One (6.67 %) case had a raised IOP, which was brought under control after anti-glaucoma medication. No other complications were encountered in any of the operated eyes.

All the cases were followed up after 1 week, 2 weeks, 4 weeks and 8 weeks. On every visit, the patients were examined for BCVA, IOP, slit-lamp examination and fundus examination. Visual field plotting (automated perimetry) was done after 8 weeks. In Group A, the mean IOP on the 1st postoperative day was 17.6 ± 4.61 mmHg (Table 6). The mean post-operative IOP on the first day in Group B was 17.2 ± 3.36 mmHg (Table 7). The mean reduction in the IOP after 8 weeks follow-up in Group A was 12.52 ± 3.59 and in group B it was 16.47 ± 3.79 mmHg ($p < 0.01$). The status of C:D ratio and visual fields in all

Table -7

Postoperative intraocular pressure-Group B

IOP(mmHg)	1 st day	1 st week	2 nd week	4 th week	8 th week
<10	0	1	0	3	2
11-20	14	13	14	12	13
>21	1	1	1	0	0

Table -8

Postoperative astigmatism

Astigmatism	Postoperatively observed astigmatism			Surgically induced astigmatism		
	ATR		WTR	ATR		WTR
	Group A	Group B		Group A	Group B	
	0.25 D	-	1	-	-	1
0.50 D	2	3	-	-	2	-
0.75 D	-	-	-	-	2	-
1.0 D	1	1	-	4	2	-
1.25 D	2	2	-	2	2	-
1.50 D	2	4	-	3	3	-
1.75 D	1	-	-	3	2	-
2.0 D	2	2	-	3	1	-
2.25 D	2	-	-	-	-	-
2.5 D	0	1	-	-	-	-
>2.5 D	3	-	-	-	-	-

Table 9

Success rate

Results	No. of cases	
	Group A	Group B
Complete success*	12 (80 %)	14 (93.33 %)
Relative success**	1(6.67 %)	1 (6.67 %)
Failure***	2 (13.33 %)	0

* IOP <21 mmHg at the end of follow up

** IOP <21 mmHg with medication at the end of follow up

*** IOP >21 mmHg with medication at the end of follow up

eyes remained the same on all follow- up visits in both the groups.

The mean surgically-induced astigmatism in Group A was 1.48 ± 0.38 D ATR and that in Group B was 1.15 ± 0.52 D (Table 8). None of the cases of any group showed WTR astigmatism. Table 9 depicts the success rate of combined SICS with trabeculectomy. As shown in the table, the complete

success rate (IOP < 21mmHg without medication at the end of follow-up) was seen in 12 (80 %) cases in Group A and 14 (93 %) cases in Group B. There occurred relative success (IOP < 21 mmHg with medication at the end of follow-up) in one (6.67 %) case in each group. Failure (IOP >21 mmHg with medication at the end of follow up) of the procedure performed was observed in 2 (13.33 %) cases from Group A and in none from Group B.

Discussion

Co-existence of cataract and glaucoma is not infrequent in the elderly population. Friedman et al (2002) stated that long term IOP is controlled more by combined cataract and glaucoma procedures than by cataract extraction alone. Trabeculectomy surely has achieved the best results among all the anti-glaucoma techniques. Many variations have been proposed and a recent one concerns the use of a punch through sclera-corneal tunnel in which ocular pressure control is achieved by creating a fistula rather than real trabeculectomy (Stewart et al 1994). During the past two decades, SICS and trabeculectomy (conventional or sutureless) has become more and more popular and offers a new option for surgical treatment of patients with cataract and glaucoma. The aim of the combined surgery is to improve visual acuity and to reduce IOP by means of one single procedure (Gayton et al 1999).

In our study, the intraocular pressure was well controlled in both groups but Group B had better reduction with less medication required postoperatively. The mean IOP reduction in Group A was 12.52 ± 3.59 and in Group B it was 16.47 ± 3.79 mm Hg ($p < 0.01$). These results are in consensus with studies by other workers. Aggarwal et al (2004) compared phaco-trabeculectomy with Kelly's punch (Group I) with conventional phaco-trabeculectomy (Group II). The mean pre-operative IOP in Groups I and II were 29.06 ± 8.59 and 28.7 ± 8.87 mmHg, respectively. The mean post-operative IOP in Group I was 16.45 ± 4.20 mmHg after a mean post-operative follow up period of 10.95 ± 6.77 months. In Group II it was 15.15 ± 2.35 mmHg after 11.48 ± 6.70 months. Crestani et al (1997) analyzed the results of combined phacotrabeulectomy with or without punch in 24 patients affected by cataract and POAG. They found that both procedures were equally effective to restore visual acuity and lower

IOP. In the present study, sutureless combined surgery group (Group A) revealed lower filtration than the W-shaped incision combined surgery group (Group B) and the requirement of anti-glaucoma medication increased from the mean 1.0 ± 0 to 1.33 ± 0.57 , whereas in the W-shaped incision combined surgery group, requirement of anti-glaucoma medications decreased from 1.16 ± 0.40 to 1.0 ± 0.0 after surgery. A good filtering bleb was observed in Group B in 93.33 % of cases as compared to 80 % in Group A.

Visual fields and cup-to-disc ratio did not show any progression postoperatively in any group. Arnold (1996) observed (mean follow up of 13.2 months) no progression of visual fields defects or C:D ratio (no stitch phaco-trabeculectomy) while two eyes had progression of visual field defects and C:D ratio (two stitch phaco-trabeculectomy). Bobrow (2000) detected visual field progression in average follow-up of 80 months. In our study, we didn't detect any progression of visual fields or C:D ratio, which may be because of a short (8 weeks) follow-up period.

We calculated astigmatism by the vector method. The mean induced astigmatism in Group A was 1.48 ± 0.38 D ATR and in Group B, it was 1.15 ± 0.52 D ATR. Nielsen (1997) reported the mean induced astigmatism ranging from -1.9 D ATR to +1.3 D WTR astigmatism at 12 months in cases of combined small-incision cataract surgery and trabeculectomy. In cases of ECCE with trabeculectomy increased diopter vector of astigmatism by 1.94 was reported by Bobrow (2000). Surgically-induced astigmatism observed in the present study in Group A patients was almost comparable to that reported in most of the combined surgeries. However, a comparatively less induced astigmatism was seen in Group B due to the high mechanical stability of the W-shaped incision and suturing leading to appropriate healing of the section.

Conclusion

The combined small incision cataract surgery (SICS) with trabeculectomy appears to be a safe and effective approach to the management of co-existing senile cataract and primary open-angle glaucoma. The combined procedure using the W-shaped incision offers better prospective in terms of glaucoma control and visual performance than sutureless combined surgery does.

References

- Agarwal A, Gupta SC, Tara A (2004). Evaluation of efficacy of sutureless phacotrabeulectomy versus conventional trabeculectomy. AIOC proceedings. p.290-2.
- Arnold PN (1996). No stitch phacotrabeulectomy. J Cataract Refract Surg; 22:253-60.
- Bobrow JC (2000). Prospective inpatient comparison of extracapsular cataract extraction and lens implantation with and without trabeculectomy. Am J Ophthalmol; 129: 291-6.
- Crestani A, Denatale R, Steindler P (1997). Phacotrabeulectomy with or without punch: Preliminary results comparing the two techniques. Ophthalmologica; 211:72-4.
- Dash R, Dhanuka NR, Das DA, Biswal P (2006). Step by step approach to manual SICS with trabeculectomy [on line] available from (<http://www.aios.org/aioc2006/flm%20festival.pdf>) [Accessed on July 17, 2006].
- Friedman DS, Jampel HD, Kempen JH, Quigley H, Congdon N, Robinson KA (2002). Surgical strategies for coexisting glaucoma and cataract. Ophthalmology; 109:1902-13.
- Gayton JI, Karr MV, Sanders V (1999). Combined cataract and glaucoma surgery: trabeculectomy versus endoscopic laser cycloablation. J Cataract Refract Surg; 25: 1214-9.
- Michielsens A, Henneker R (1994). W-incision for combined cataract and glaucoma surgery. Bull Soc Belge Ophthalmol; 254: 13-7.
- Nielsen PJ (1997). Combined small incision cataract surgery and trabeculectomy: a prospective study with 1 year follow up; Ophthalmic Surg Lasers; 28:21-9.
- Pantelis V, Wijaya J, Hennekes R (1994). W- incision for cataract surgery. Bull Soc Belge Ophthalmol; 254: 19-23.
- Stewart WC, Crinkley CM, Carlson AN (1994). Results of trabeculectomy combined with phacoemulsification versus trabeculectomy with extra-capsular cataract extraction in patients with advanced glaucoma. Ophthalmic Surg; 25: 621-7.

Source of support: nil. Conflict of interest: none