




Study of Natural Course of Serous Macular Detachment in Pregnancy induced Hypertensive Patients at a Tertiary Care Centre

Shilpa Yellur Devegowda¹, Kalpana Badami Nagaraj¹, Hithashree Hampannavar Rajanna¹ ,
Hemalatha B Chikhanumantappa¹, Ravi Bypareddy¹, Manoj Kumar N¹,
Kavitha L Tumbadi¹, Jessica Basumatary¹

¹Minto Ophthalmic Hospital and Regional Institute, Bangalore Medical College, Bangalore, Karnataka, India

ABSTRACT

Introduction: The research aimed to study the natural course of serous macular detachment SRD) in patients with pregnancy induced hypertension (PIH), and document fundus changes, OCT findings and visual outcome.

Materials and methods: This is a prospective observational study. Admitted patients underwent ocular screening, and detailed dilated indirect ophthalmoscopy. Those with serous macular detachment were further evaluated with OCT; characteristics of OCT analysed and recorded. All eyes were followed up till macular resolution was noted.

Results: Out of 4950 cases, 22 patients (38 eyes) had serous macular detachment. Mean central macular thickness (CMT) was 512.29 (SD 242.074). RPE irregularity (31.6%), subretinal hyperreflective dots (26.3%) and subretinal membranes (23.7%) were more commonly seen OCT features in these eyes.

The difference between mean vision and mean central macular thickness at different intervals was statistically significant : F(3, 111)=65.514, p - 0.001; F(3, 111)=47.331, p – 0.001 respectively. All eyes had resolution of retinal detachment with full visual recovery following delivery. However, 10 pregnancies had foetal mortality.

Conclusion: The incidence of ocular affection in pregnancy induced hypertension is 1-2%. Retinal detachment in such cases have good visual potential following termination of pregnancy. However, the cases had a high incidence of foetal demise. Therefore, early emphasis on early detection of ocular involvement in pregnancy induced hypertension and timely intervention is focused on to prevent foetal demise.

Key words: Eclampsia, Fundus, OCT, Preeclampsia.

Financial Interest : Nil

Received : 26.12.2021

Conflict of Interest : Nil

Accepted : 12.04.2022

Corresponding Author

Dr. Hithashree HR
Assistant Professor, Vitreo-retina Department,
Minto Ophthalmic Hospital and Regional Institute,
Bangalore Medical College and Research Institute,
Bangalore, Karnataka, India.
E-mail: hithashree_rajanna@yahoo.co.in



Access this article online

Website: www.nepjol.info/index.php/NEPJOPH

DOI: <https://doi.org/10.3126/nepjoph.v14i2.41804>

Copyright © 2022 Nepal Ophthalmic Society

ISSN: 2072-6805, **E-ISSN:** 2091-0320



This work is licensed under a Creative Commons
Attribution-NonCommercial-NoDerivatives 4.0
International License (CC BY-NC-ND).

INTRODUCTION

Pregnancy Induced Hypertension(PIH) is an obstetric complication occurring after gestational week 20 and upto postpartum 12 weeks. Characteristic features are elevated blood pressure (systolic ≥ 140 mmHg or diastolic 90 mmHg on at minimum two occasions recorded 6 hours apart), accompanied by proteinuria (≥ 300 mg/24 hours), and it contributes significantly to maternal and foetal morbidity and mortality. It affects 5-15% of pregnancies (Bhandari, A et al., 2014; Kumar, 2016). Pre eclampsia affects 3-5% of pregnancy, characterised by hypertension, edema, and proteinuria. Eclampsia occurs later, defined as seizures in Preeclampsia. HELLP represents a severe form of pre-eclampsia/eclampsia, presenting with elevated liver enzymes, hemolysis, and low platelets (Abu Samra, K. et al., 2013; Lee, C. et al., 2019).

Ocular involvement is noted in 30-100% of Preeclampsia cases, (B Sreckovic, S. et al., 2011; Bakhda, R. et al., 2015; Chakraborti, C. et al., 2016; Kumar et al., 2016) and in 71% of eclampsia cases (Kumar et al., 2016). Retinal vascular changes occur in 40–100% of preeclampsia/eclampsia patients, and the most common retinal abnormality is spasm and narrowing of retinal vessels. RD affects 1-2% of severe preeclampsia and 10% of eclampsia patients; risk is increased 7 times if associated with HELLP syndrome (Abu Samra, K. et al 2013; Lee, C et al., 2019; Prado, R. et al., 2002). Visual symptoms are delayed until macula is involved; occurring in 25% of severe

preeclampsia and 50% of eclampsia cases (Abu Samra, K. et al 2013; Lee, C.S. et al., 2016; Varghese S et al., 2012).

There are few case reports published regarding serous macular detachment in Pregnancy induced hypertension (PIH). However there are no studies pertaining to the natural course of serous macular detachment. In this study we have attempted to study the various patterns in macular detachment and their natural clinical course and visual outcome.

MATERIALS AND METHODS

It is a prospective observational study conducted between 1/8/2017 to 15/01/2021 (39 months). Institutional Ethical Committee approval was obtained before we started the study, and our study was done according to the declaration of Helsinki. Informed consent was taken from all subjects who agreed to be a participant in our study.

All cases of PIH admitted in obstetric wards underwent routine ocular screening, visual acuity evaluation, anterior segment evaluation with IDO and +20 Dioptre lens, and detailed dilated indirect ophthalmoscopy fundus examination bedside. Patients diagnosed with serous macular detachment underwent a detailed evaluation at Vitreous-retina department which included visual acuity, IOP using GAT, slit lamp anterior segment evaluation; and posterior segment evaluation with IDO. Fundus photo was taken using a Zeiss FF450+. OCT documentation done using CIRRUS HD-OCT model 5000,



Zeiss Meditec, USA. OCT characteristics were analysed and recorded. Patients were followed up every week until resolution of serous macular detachment. Obstetric case records of these patients were studied - antenatal, postnatal status and foetal well being noted. Patient treatment charts studied for anti hypertensive medications and eclampsia regimens that were followed.

Inclusion criteria – PIH patients detected with serous macular detachment on IDO examination.

Exclusion criteria – Patients with retinal detachment due to other ocular pathologies (Diabetic, vascular disorders related, other inflammatory etc), patients with previous existing ocular morbidities (uveitis patients, Coloboma etc)

Statistical Analysis

- Data collected entered in MS Excel and analysed using version 24 Statistical Package for Social Sciences (SPSS). ANOVA was applied to test the statistical significance between vision and central macular thickness (CMT) at different intervals. A p value of <5% was considered statistically significant.

RESULTS

A total of 4950 PIH cases were screened. 38 eyes of 22 patients among them had Serous Macular Detachment which were further evaluated. Out of 22 patients, 18 were antepartum in third

trimester of their pregnancy, 4 were postpartum day 1. Patients having preeclampsia, eclampsia, HELLP syndrome were 13, 6 and 3 respectively.

Age group of our study subjects ranged from 19 to 34 years, with a mean of 26 years. In our study, 13 cases were primigravida (preeclampsia 7, eclampsia 4, HELLP 2) and 9 were gravida ≥ 2 (preeclampsia 5, eclampsia 3, HELLP 1). Out of 13 primigravida, 5 subjects had bilateral manifestations of PIH. None of our patients had pre-existing hypertension/pre-gestational or gestational diabetes. However only one patient had previous history of preeclampsia. All patients were taken up for emergency delivery of the foetus.

10 of these pregnancies ended in foetal death (HELLP 3, eclampsia 3, preeclampsia 4) with no maternal mortality. All cases of our study (22 patients, 38 eyes) showed spontaneous resolution of retinal detachment with visual recovery post-delivery.

Pre-delivery vision ranged from CF 1 metre to 6/18 in the affected eyes. 25/38 eyes (65.8%) had $> 6/36$ vision on Snellen chart. The least vision of CF 1 metre in our study was documented in a case of HELLP syndrome who had exudative RD involving macula in one eye. Post-delivery during followup, vision ranged from 6/12 to 6/6. 32/38 eyes (84.2% eyes) had 6/6 vision recovery with a mean of 14 days.

Anterior segment was normal in all 38 eyes. 16 patients had bilateral retinal detachment involving macula. Out of these, 3 had B/L

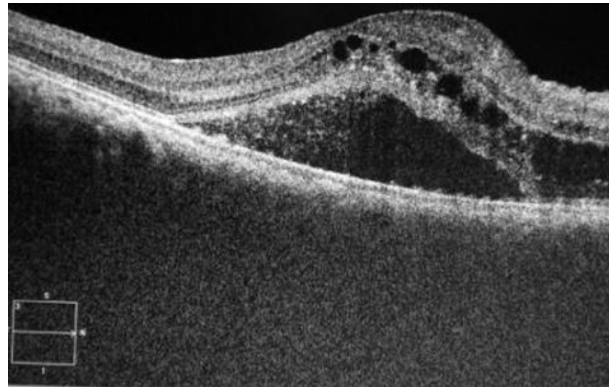


Figure 1: HD- OCT scan showing macular SRF with multiple cystoid spaces in the sensory retina, focal RPE elevations and RPE irregularities.

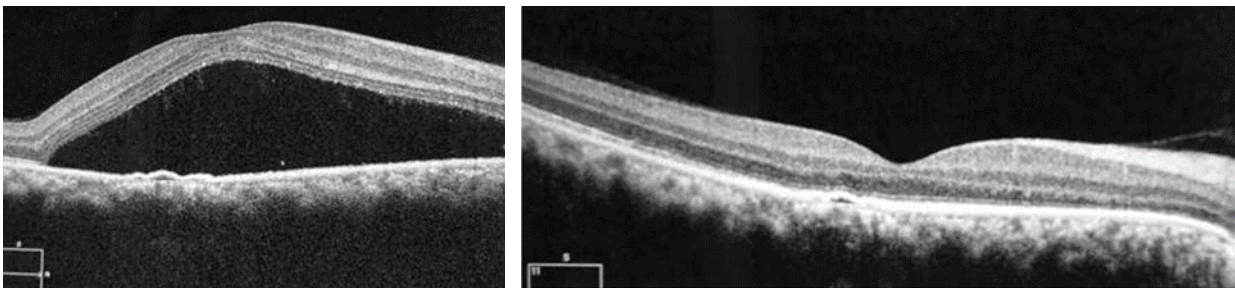


Figure 2: OCT showing SRD with PED, RPE hyperreflectivity. SRF resolved completely postpartum, but PED persisted.

ERD, 3 had ERD in one eye with SRD in other eye. 6 cases presented with unilateral serous macular detachment.

Hypertensive vascular changes (arteriolar narrowing) was seen in 2 preeclamptic patients bilaterally (4 eyes), but only 3 eyes had macular serous RD. OCT revealed SRF with intraretinal cystoid spaces (Figure 1).

CMT ranged from 580 microns to 324 microns in the first visit of these patients. Other OCT features included RPE irregularity, subretinal hyperreflective dots, subretinal membranes,

intraretinal cysts at macula, ILM irregularities, RPE undulations, PED (Table 1). All these OCT features resolved within 4 to 20 days, barring PED in 1 eye (Figure 2) and RPE irregularities in 3 eyes even after complete visual recovery and SRF resolution at macula.

Our study had 3 cases of HELLP syndrome, all of which resulted in foetal demise. One of these had ERD in one eye, SRD in the other, which took maximum days for resolution (28 days) (Figures 3A-C). The second patient had U/L SRD.

Table 1 : Showing different OCT features seen; appearance of each in percentage of eyes.

OCT features	Yes		No	
	No of eyes	Percent	No of eyes	Percent
Subretinal hyperreflective dots	8	21.1	30	78.9
Subretinal membrane structures	8	21.1	30	78.9
RPE folds/undulations	2	5.3	36	94.7
PED	3	7.9	35	92.1
ILM irregular	4	10.5	34	89.5
RPE irregularities/Focal RPE elevation	10	26.3	28	73.7
Subretinal fluid	17	44.7	21	55.3
Cysts at macula	8	21.1	30	78.9

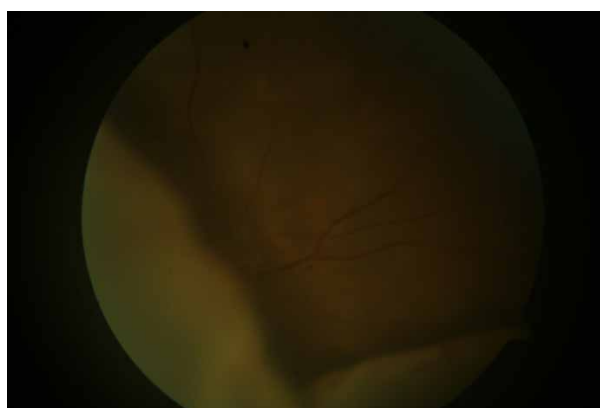

Figure 3A: Fundus picture showing RE exudative RD extending to and involving macula. Patient had serous macular detachment in LE.

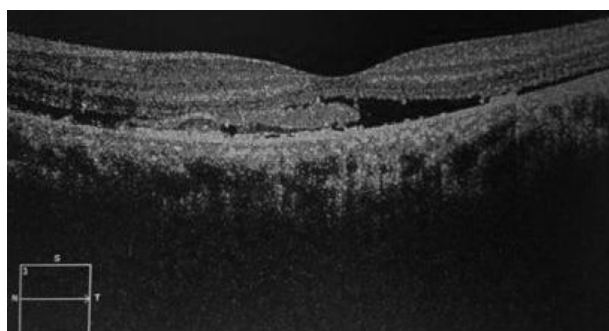


Figure 3B: OCT of the same patient showing proteinaceous material deposited between sensory retina and RPE, RPE irregularity and hyperreflectivity.

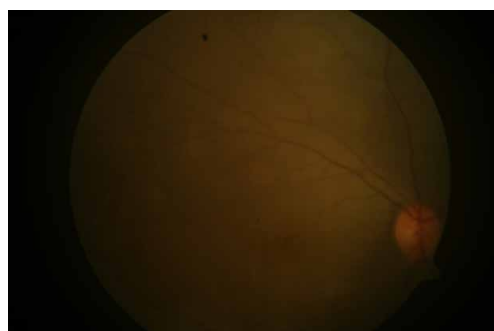


Figure 3C: Fundus photo showing resolution of RD, with generalised mottling of fundus persisting probably because of pigmentary migration in choroid/pigment layer.

2 cases of eclampsia presented with U/L ERD along with serous macular elevation. Both pregnancies ended in foetal death. Patients recovered completely postpartum.

During follow up serous elevation decreased and subsequently foveal contour was restored in

all 38 eyes within 4-20 days. In this study higher elevation took longer duration for resolution. CMT was not influenced by age. No significant difference was found in CMT and pattern of serous elevation between preeclampsia and eclampsia cases and between primigravida and multigravida.

Table 2 : Comparison of recording of vision at each visit showing p value for visual recovery at each follow up.

(I) Time intervals	(J) Time intervals	Mean Difference (I-J)	Std. Error	p value*	95% Confidence Interval (CI) for Difference ^b	
					Lower Bound	Upper Bound
1st visit	1 wk post delivery	0.516*	0.066	0.000	0.333	0.699
	2 wks post delivery	0.813*	0.096	0.000	0.547	1.080
	4 wks post delivery	0.913*	0.102	0.000	0.628	1.198
1 wk post delivery	2 wks post delivery	0.297*	0.050	0.000	0.158	0.436
	4 wks post delivery	0.397*	0.061	0.000	0.228	0.567
2 wks post delivery	4 wks post delivery	0.100*	0.027	0.004	0.024	0.176

*. The mean difference found significant at 0.05 level.

Table 3: Comparison of measured CMT at each visit showing p value for CMT changes between visits.

(I) factor1		Mean Difference (I-J)	Std. Error	p value ^b	95% CI ^b	
					Lower Bound	Upper Bound
CMT	CMT - 1 w post delivery	220.816*	31.237	0.000	133.738	307.893
	CMT - 2 weeks	262.895*	38.064	0.000	156.787	369.003
	CMT - 3 weeks	270.211*	39.118	0.000	161.166	379.255
CMT - 1 week post delivery	CMT - 2 weeks	42.079*	8.435	0.000	18.564	65.593
	CMT - 3 weeks	49.395*	9.474	0.000	22.984	75.806
CMT - 2 weeks	CMT - 3 weeks	7.316	2.711	0.063	-.241	14.873

*. Mean difference found significant at 0.05 level.



Table 4: Showing correlation value between CMT and vision at each visit.

Pearson correlation	r **.value	p value
CMT and Vision log Mar	0.244	0.14
CMT - 1 wk and vision - 1 wk	0.514	0.001
CMT - 2 wk and vision - 2 wk	0.255	0.122
CMT - 3 wk and vision - 4 wk	0.062	0.712

** - r is the coefficient of correlation.

Positive correlation was found between CMT and vision at respective intervals.(Table 2 and 3) But significant correlation is found only at 1 week (r – 0.514, p – 0.001);(Table 4).

Since the hospital is a referral centre, a large number of high risk pregnancies report to the department of Obstetrics and Gynecology. Routine fundoscopy in cases of PIH patients helped us to identify these fundus changes.

DISCUSSION

Von Graefe was the first to describe serous RD in toxemia of pregnancy in 1855. (B Sreckovic,S. et al.,2011;Tranos et al.,2002) . Pathophysiology in PIH has been demonstrated to be associated with increase in systemic vascular resistance, an abnormal placentation leading to generalised vasospasm, even though the exact pathophysiology is yet to be elaborated. These associated factors cause dysfunction of the retinal as well as choroidal circulation; ischemia of choroid and also RPE. This further causes degradation of the outer Blood-Retinal-Barrier and formation of serous proteinaceous exudate from the choroid through RPE into subretinal space producing Serous

RD. (B Sreckovic,S. et al.; 2011; Bakhda, Lee, C.S. et al., 2019; Haslinda et al., 2017; Tranos et al., 2002)

Management of RD as a complication of preeclampsia is conservative.In most cases detachment resolves with a return to normal visual function spontaneously after delivery. (Abu Samra,K. 2013; Bakhda,R, 2015; B Sreckovic,S. et al., 2011; Talbishi, A et al., 2015; Tranos et al.,2002). Few patients develop residual macular RPE changes which may represent areas of infarction of choriocapillaris. Residual visual impairment may persist if there is extensive RPE necrosis and pigmentary macular disturbance. (Abu Samra,K.et al 2013; Tranos et al., 2002)

Our study shows that Retinal detachment in PIH is more common in Eclampsia (59% cases). It presents more commonly as bilateral RD (72.7% eyes).Our incidence of Serous macular detachment among PIH patients is 0.44%. Vision was worse than 6/36 in all the patients. OCT features most consistent were subretinal hyperreflective dots, RPE irregularities and focal RPE elevations (31.6%).

OCT features of SRF with cysts at macula;SRF with PED;Serous RD with Subretinal fibrin membranes(SRFM); have been reported in separate case reports.(Komoto, S. Et al 2019; Pastore,M et al(2012); Talbishi et al 2015).We found similar features in our patients.These OCT features resolved spontaneously with control of blood pressure and systemic features in these patients.

Talbishi et al(2015) has observed the presence of V-shaped adhesions at the location of elschnig's spots, the centre of which showed disruption of the outer retinal bands and V-shaped outer parts remained tethered to RPE- bruch's membrane complex by hyper reflective exudates on the surface of RPE. Similar findings were observed in one of our cases (Figure 4).

The feature that is of more interest we feel is the finding of Serous RD with subretinal fibrin membranes (SRFM), which we saw in a good 8 cases (21.1%), with no associated retinal

vessel abnormality (Figure 5). The visual acuity recorded and the OCT features noted, spontaneously improved within the postpartum period of 4 weeks, with 72% actually resolving within the first postpartum week. None of the patients had morbidity of permanent visual loss. Thus the acute clinical condition might not have led to any irreversible retinal circulation changes or outer retinal

changes, thus we saw spontaneous resolution with complete visual recovery in all patients.

SRFM on OCT has been previously seen in central serous chorioretinopathy (CSC) and Vogt–Koyanagi–Harada (VKH) disease. (Liu XY et al., 2016). In CSC, fibrin though being a large molecule might still have entered the subretinal space because of hyperpermeable choroid and RPE breach. (Rajesh B et al., 2017). SRFM in CSC and VKH have been described to be macrophages that have engulfed shed outer segments or other inflammatory debris. (Komoto S et al., 2019)

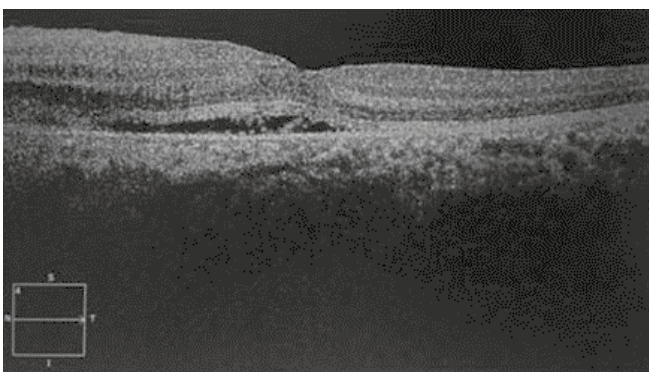


Figure 4: V-shaped outer retinal disrupted parts tethered to RPE- bruch's membrane complex by hyper reflective exudates on the surface of RPE.

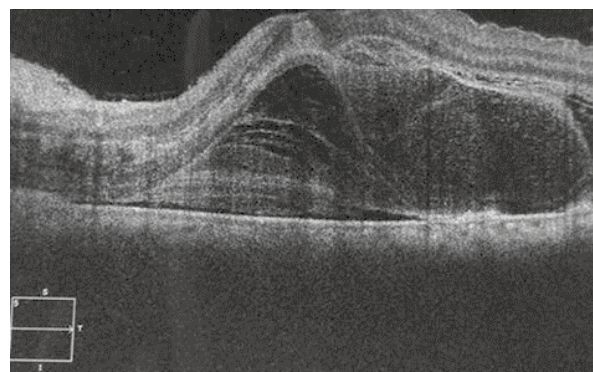


Figure 5: OCT showing subretinal fibrinous membranes, focal RPE elevations but no RPE defects; also showing ILM folds.

Alleyes in our study which had fibrin-like material had RPE irregularities/focal RPE elevations, but no signs of inflammation in anterior or posterior segment, and SRFM disappeared without any treatment shortly after delivery. We speculate that pregnancy associated with increased viscosity of blood, caesarean delivery and the reduced plasma volume, and PIH associated choroidal vasoconstriction might have caused intense choroidal hypoperfusion. Thus leading to ischemic conditions, RPE damage and hyperpermeable choroid. Although we did not find any involvement of inflammation in these cases, it is possible that SRFM in our cases was because of some kind of an inflammatory response to this ischemic condition.

Only persistent feature at 4 weeks of delivery was PED in 1 eye, which did not affect vision, neither caused persisting SRF. We could not follow up this patient further, as she was lost for follow-up further.

As previously stated, the treatment is only conservative, that is PIH needs to be managed, and retinal disease settles spontaneously. However, after control of blood pressure and delivery, if the condition is not showing improvement spontaneously, we need to then investigate for other coexistent pathological conditions affecting the retina, and may need interventions as indicated.

Examination of fundus is a simple and noninvasive and essential diagnostic step in cases with PIH. Though definitive management

will depend on other factors, suggestive diagnosis by fundoscopy will guide the obstetric management of the patient (Kumar et al., 2016). This is one of the important strengths of our study.

FFA is limited partly because of teratogenic effects on the foetus. FFA done in cases have shown that RD in preeclampsia is due to occlusion of choroidal arterioles and choriocapillaries (B Sreckovic, S. et al., 2011). FFA has shown multiple foci of fluorescein leakage in mid phase and pooling of dye in subretinal space in late phase (Talbish, A et al., 2015). FFA and ICG observation support the hypothesis that RD is secondary to choroidal ischemia (Lee, C.S. et al., 2016)

Retinal detachment/papilloedema in PIH patients, can be a red alert sign to terminate pregnancy to save the patient's vision (Song Y et al., 2013). Further studies are needed to establish the exact pathogenesis and implications of retinal microvascular changes in preeclampsia. The major limitation of our study is we could not deduce the correlation between the PIH blood parameters and the severity of SRD or vision loss, and its recovery.

CONCLUSION

In this study all 22 patients had improvement in visual acuity over a few days to a few weeks. OCT of the macula showed normal retinal architecture after a few days (maximum 20 days). Systemic control of hypertension helped

in all the cases. Here we present 22 cases of serous macular detachment in pre eclampsia and eclampsia. We have managed to describe OCT features in these cases which show RPE changes which are transient and resolving back to almost normal with systemic control of blood pressure after delivery.

Foetal deaths were 10/22, which is a huge proportion, so even though ocular involvement with SRF at macula is not a threat to the eyes, it is

nevertheless a feature if present, having adverse foetal outcome in the pregnancies complicated by it. Therefore immediate transfer and care of pregnant women with visual complaints is needed to save the lives of mother and baby. Prompt delivery and control of hypertension results in reversal of ocular manifestations in these patients, thus saving the lives and also the eye.



REFERENCES

- Abu Samra, K., 2013. The eye and visual system in the preeclampsia/eclampsia syndrome: What to expect?. *Saudi Journal of Ophthalmology*, 27(1), pp.51-53. <https://doi.org/10.1016/j.sjopt.2012.04.003>
- B. Srećković, S., A. Janićijević-Petrović, M., B. Stefanović, I., T. Petrović, N., S. Šarenac, T. and S. Paunović, S., 2011. Bilateral retinal detachment in a case of preeclampsia. *Bosnian Journal of Basic Medical Sciences*, 11(2), p.129. <https://doi.org/10.17305/bjbms.2011.2598>
- Bakhda, R., 2015. Clinical assessment of retinopathy post management of pregnancy induced hypertension. *International Journal of Medicine and Public Health*, 5(3), p.205. <https://doi.org/10.4103/2230-8598.161516>
- Bakhda, R.N. (2015). Ocular manifestations of Pregnancy Induced Hypertension. *Delhi Journal of Ophthalmology*, 26(2). <https://doi.org/10.7869/djo.144>
- C, L. (1999). RETINAL DETACHMENT IN POSTPARTUM PRE ECLAMPSIA AND ECLAMPSIA REPORT OF TWO CASES. 3(22).
- Chakraborti, C., Barua, N. and Malsawmtluanga, M., 2016. A rare case of bilateral total retinal detachment in pre-eclamptic primigravida patient. *Sudanese Journal of Ophthalmology*, 8(2), p.62. <https://doi.org/10.4103/1858-540X.198542>
- Haslinda (2017). bilateral exudative retinal detachment in mother with preclampsia. *aperito journal of ophthalmology*, 3(1127), pp.2-4. Lee, C., Choi, E., Lee, M., Kim, H. and Chung, H., 2019. Serous retinal detachment in preeclampsia and malignant hypertension. *Eye*, 33(11), pp.1707-1714. <https://doi.org/10.1038/s41433-019-0461-8>
- Komoto, S., Maruyama, K., Hashida, N., Koh, S. and Nishida, K. (2019). Bilateral serous retinal detachment associated with subretinal fibrin-like material in a case of pregnancy-induced hypertension. *American Journal of Ophthalmology Case Reports*, 16, p.100572. <https://doi.org/10.1016/j.ajoc.2019.100572>
- Kumar (2016). importance of ophthalmoscopic examination and prevalence of fundus changes in pregnancy induced hypertension in tertiary care rural hospital. *Internal journal of recent scientific research*, 7(7).



Lee, C., Choi, E., Lee, M., Kim, H. and Chung, H., 2019. Serous retinal detachment in preeclampsia and malignant hypertension. *Eye*, 33(11), pp.1707-1714. <https://doi.org/10.1038/s41433-019-0461-8>

Liu, X.Y., Peng, X.Y., Wang, S., You, Q.S., Li, Y.-B., Xiao, Y.Y. and Jonas, J.B. (2016). FEATURES OF OPTICAL COHERENCE TOMOGRAPHY FOR THE DIAGNOSIS OF VOGT-KOYANAGI-HARADA DISEASE. *Retina*, 36(11), pp.2116-2123. <https://doi.org/10.1097/IAE.0000000000001076>

Pastore, M., De Benedetto, U., Gagliardi, M. and Pierro, L., 2012. Characteristic SD-OCT Findings in Preeclampsia. *Ophthalmic Surgery, Lasers and Imaging Retina*, 43(6). <https://doi.org/10.3928/15428877-20121001-03>

Prado, R., Figueiredo, E. and Magalhães, T., 2002. Retinal Detachment in Preeclampsia. *Arquivos Brasileiros de Cardiologia*, 79(2), pp.185-186. <https://doi.org/10.1590/S0066-782X2002001100011>

Rajesh, B., Kaur, A., Giridhar, A. and Gopalakrishnan, M. (2017). "VACUOLE" SIGN ADJACENT TO RETINAL PIGMENT EPITHELIAL DEFECTS ON SPECTRAL DOMAIN OPTICAL COHERENCE TOMOGRAPHY IN CENTRAL SEROUS CHORIORETINOPATHY ASSOCIATED WITH SUBRETINAL FIBRIN. *Retina*, 37(2), pp.316-324. <https://doi.org/10.1097/IAE.0000000000001192>

Song, Y., Kinouchi, R., Ishiko, S., Fukui, K. and Yoshida, A., 2013. Hypertensive choroidopathy with eclampsia viewed on spectral-domain optical coherence tomography. *Graefes Archive for Clinical and Experimental Ophthalmology*, 251(11), pp.2647-2650. <https://doi.org/10.1007/s00417-013-2462-9>

Talbishi, a. (2015). elschnig spots iin acute and remission stages of preclampsia. *eupean journal of ophthalmology*, 5(25), pp.84-87. <https://doi.org/10.5301/ejo.5000586>

Tranos, P.G., Wickremasinghe, S.S., Hundal, K.S., Foster, P.J. and Jagger, J. (2002). Bilateral serous retinal detachment as a complication of HELLP syndrome. *Eye*, 16(4), pp.491-492. <https://doi.org/10.1038/sj.eye.6700056>

Varghese, S., Koshy, J. and Avasthi, K., 2012. Bilateral serous retinal detachment in a case of eclampsia. *Health*, 04(01), pp.13-14. <https://doi.org/10.4236/health.2012.41003>
