

## An Unusual Presentation of Corneal Intraepithelial Neoplasia: A Case Report

Leena Bajracharya<sup>1</sup>, Jyoti Sapkota<sup>2</sup>

<sup>1</sup>Tilganga Institute of Ophthalmology, Kathmandu, Nepal.

<sup>2</sup>Rapti Eye Hospital, Dang, Nepal

### ABSTRACT

**Introduction:** Corneal squamous neoplasia is less common than that of conjunctiva and can cause diagnostic confusion.

**Case:** A 40-year-old male presented with gradual onset blurring of vision in left eye for 8 weeks. He had received treatment for dry eyes, then for herpetic dendritic keratitis, but without improvement. On slit-lamp examination with diffuse light, apparently the cornea looked clear with some dilated conjunctival vessels nasally. But in the retro-illumination, on the corneal surface, there was a translucent inverted “V” shaped lesion with irregular fimbriated margin. He underwent excisional biopsy of the corneal lesion and the adjacent conjunctiva. Cryotherapy of the conjunctival margin and the adjoining limbus was done. Corneal and conjunctival specimens reported intraepithelial neoplasia grade II and I respectively. There had not been any recurrence till 4 year post-operatively.

**Conclusion:** Corneal examination by retro-illumination aids to diagnose and demarcate corneal intraepithelial neoplasia clinically. Timely management results in good prognosis.

**Key words:** Corneal CIN, Ocular surface tumors, OSSN.

### INTRODUCTION

Ocular surface squamous neoplasia (OSSN) is a broad term encompassing intraepithelial neoplastic lesions (carcinoma in situ, CIN) and invasive squamous cell carcinoma of conjunctiva

and cornea (Lee GA et al, 1995). It presents more commonly within the interpalpebral perilimbal conjunctiva and may extend to involve the cornea (Mittal R et al, 2013). Isolated corneal neoplasia may also occur, but it is very rare (Mittal R et al, 2013; Kumar R et al, 2009). Corneal epithelial

Financial Interest : Nil

Received : 16.09.2021

Conflict of Interest : Nil

Accepted : 20.12.2021

#### Corresponding Author

Dr. Jyoti Sapkota  
Rapti Eye Hospital,  
Dang, Nepal.  
E-mail: jyoti.ss100@gmail.com



Access this article online

Website: [www.nepjol.info/index.php/NEPJOPH](http://www.nepjol.info/index.php/NEPJOPH)

DOI: <https://doi.org/10.3126/nepjoph.v14i1.39806>

Copyright © 2021 Nepal Ophthalmic Society

ISSN: 2072-6805, E-ISSN: 2091-0320



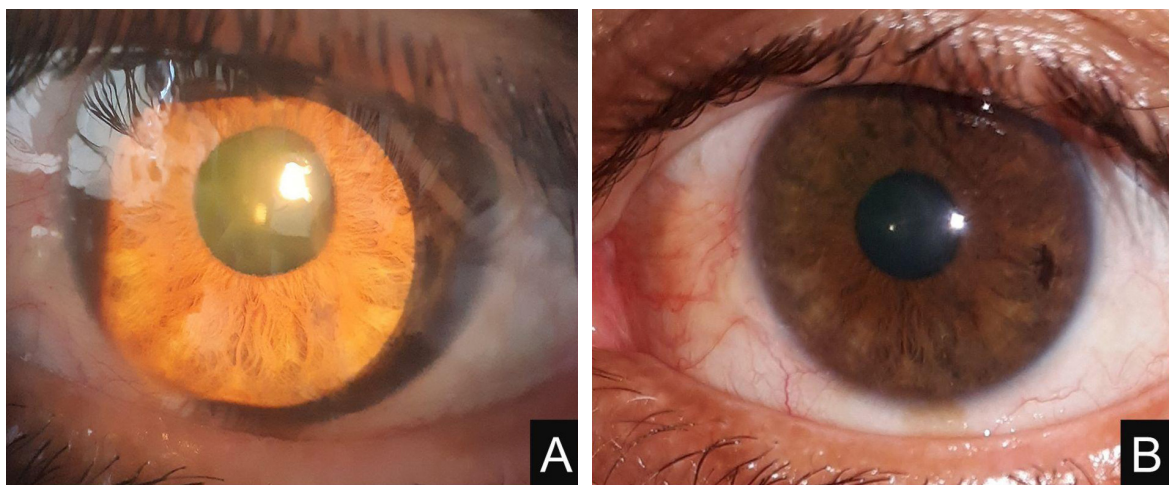
This work is licensed under a Creative Commons Attribution-NonCommercial-NoDerivatives 4.0 International License (CC BY-NC-ND).

neoplasia usually commences at the limbus and grows towards the central cornea as a translucent lesion and may have neovascularization into the lesion. Risk factors for OSSN are advanced age, male gender, exposure to solar ultraviolet rays, infection with human papillomavirus (HPV), immunosuppression and infection with human immunodeficiency virus (HIV) (Mittal R et al, 2013). We report a middle-aged male with corneal CIN, which caused diagnostic confusion due to atypical presentation.

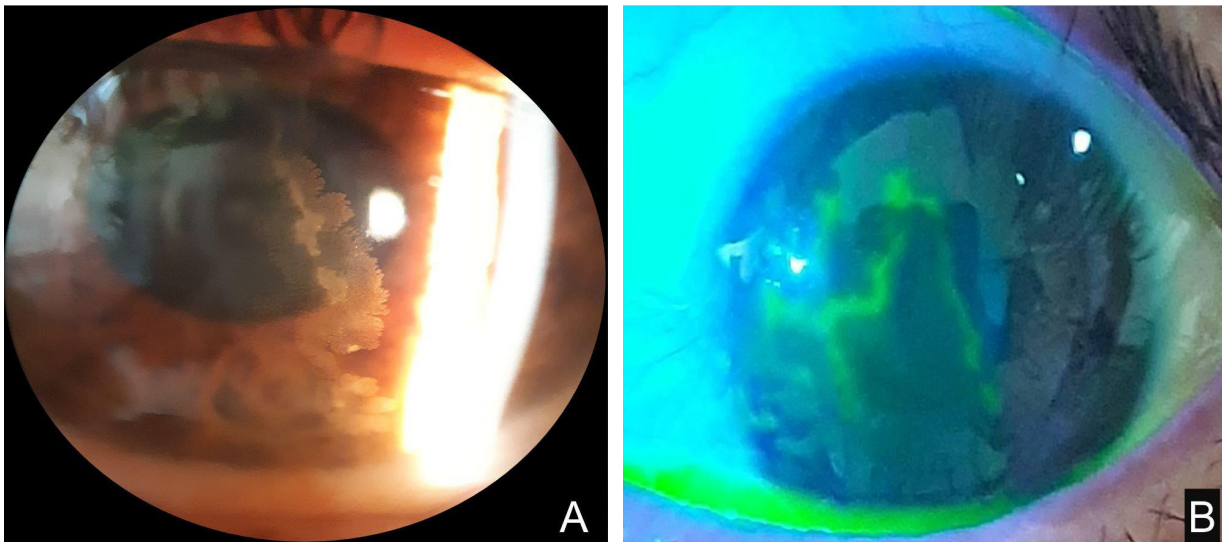
### CASE

A 40-year-old male from a hilly region (subtropical climate) of Nepal came with 8 weeks' history of gradual visual disturbance in left eye. There was no pain or redness. He had consulted in an eye clinic where he was treated as dry eyes with artificial tears. He did not get better, instead started having discomfort and irritation. After that, he visited a local eye hospital 3 weeks back where he was treated

for Herpes simplex dendritic keratitis with Acyclovir 3% ointment, antibiotic drops and later on with topical steroids. But he did not improve. On presentation to our institute, his best-corrected visual acuity in the affected eye was 6/36. His vision in the fellow eye was 6/6. On torchlight as well as on slit-lamp examination in diffuse light, cornea looked clear without any haze or opacity except that there was slight conjunctival congestion nasally (Figure 1A and 1B). But retro-illumination of the cornea revealed a translucent lesion in the shape of an inverted "V". The lesion was occupying the nasal, central and inferior cornea. One end of the limb was continuous with nasal limbus, adjacent to which where there were dilated conjunctival vessels. There were no clinically suspicious lesions in the limbus and conjunctiva apart from those dilated (feeder) vessels. The margins of the lesion were fimbriated and irregular. It was highly suspicious of corneal CIN. On staining the cornea with fluorescein, the central area



**Figure 1: (A) Slit-lamp photography under diffuse illumination and (B) Torch light examination apparently showing clear cornea.**



**Figure 2: (A) Slit-lamp examination under retro-illumination shows translucent lesion with fimbriated margin. (B) Axis of the lesion taking fluorescein stain, showing shape of the lesion.**

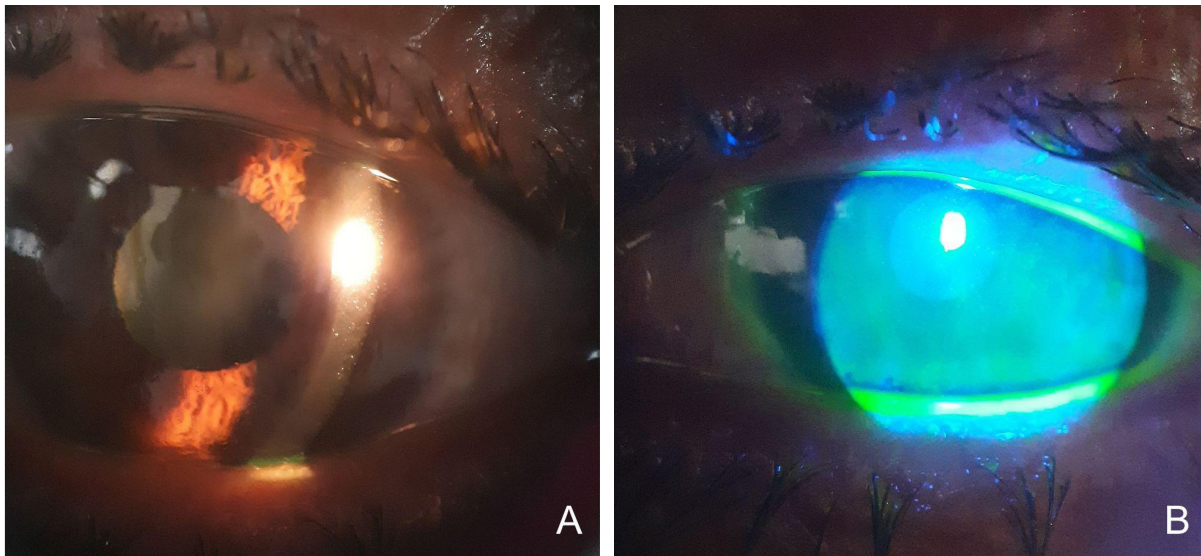
of the lesion took stain, which was also in the shape of an inverted “V”, mimicking the dendritic pattern of viral keratitis (Figures 2A and 2B). Corneal sensation was intact in both eyes. Patient underwent Ethyl alcohol assisted surgical debridement of the corneal lesion along with surrounding 4 mm of the normal corneal epithelium. The 4 mm strip of conjunctiva adjacent to the lesion was also excised and both the samples were sent for histopathological examination. The sample from the cornea was also sent for polymerase chain reaction (PCR) test for herpes simplex virus (HSV) and HPV. We sent for HSV because we wanted to rule out herpetic keratitis, in case it had co-existed.

Double freeze-thaw cryotherapy was done in the limbal area adjoining the corneal lesion and in the rim of the excised conjunctiva. Postoperatively the patient was given low dose

topical steroids and prophylactic antibiotics for 4 weeks.

Histopathology of the corneal section revealed CIN grade II with hyperplastic squamous epithelium and mild to moderate dysplasia. Margins were not commented on as the corneal epithelial specimen was in pieces. Histopathology of conjunctiva reported CIN grade I with mild dysplasia. There were congestion and elastotic changes in the substantia propria. Margins of conjunctival tissue were not involved. The PCR test was negative for HSV and HPV. His HIV status was negative too.

Post-operatively in the first week, the patient’s symptoms were gone and vision improved to 6/6 (Figures 3A and 3B). At 4 years follow-up, the patient did not have any signs of recurrence in the cornea or conjunctiva.



**Figure 3: Post-operative at 4 weeks. (A) Retroillumination of cornea showing clear cornea. (B) without epithelial defect.**

## DISCUSSION

OSSN usually occurs at the limbal region, and gradually invades the conjunctival (more common) and corneal epithelium. Corneal lesion is mostly associated with the more extensive limbal or conjunctival lesion and may be accompanied by neovascularization (Gichuhi S et al, 2014). Morii T et al, 2016 reported an isolated corneal lesion surrounded by normal corneal epithelium, which is quite a rare occurrence. In a study by Kumar R et al, 2009 conjunctiva was the most common site (74.3%) in OSSN and the cornea only accounts for (5.1%). Our case of OSSN was predominantly corneal, without any clinically suspicious lesions in the limbus or in conjunctiva. Corneal CIN may be misinterpreted as calcific scar, viral keratitis, dry eyes, fatty degeneration,

corneal pannus and dermoid (Mittal R et al, 2013; Hamam R et al, 2009). In our case, the corneal staining pattern mimicked HSV dendritic keratitis (Figure 2B) but careful retroillumination examination showed translucent lesion with irregular border (Figure 2A). An interesting thing in our case is that on torchlight and diffuse slit lamp examination, the lesion was barely seen (Figure 1A and 1B). This was the reason why the corneal lesion was overlooked and treated as dry eyes and as herpetic keratitis initially. Other sophisticated tools for diagnosis of corneal CIN are superficial cytology, confocal microscopy and anterior segment optical coherence tomography (Mittal R et al, 2013). However, careful and thorough clinical examination cannot be underestimated in picking up cases of OSSN.

Our patient was a middle-aged male from a subtropical climate within door occupation. HIV serology and PCR for HPV were also negative. Hence, apparently he did not have any risk factors (Mittal R et al, 2013).

Surgical excision and intra-operative adjuvant cryotherapy had good outcome for CIN of ocular surface (Crim N et al, 2013; Moon CS et al, 2016), whereas adjuvant topical chemotherapy may have ocular surface side effects like punctate keratopathy, conjunctival hyperemia, eyelid and eye irritation (Crim N et al, 2013). In our case, the patient responded very well with surgical excision and cryotherapy. He was recurrence free till 4 years post-operation. Long-term follow-up is essential as recurrences can occur many years later.

## REFERENCES

- Crim, N., Forniés-Paz, M.E., Monti, R., Espósito, E., Maccio, J.P. and Urrets-Zavalía, J.A., 2013. In situ carcinoma of the conjunctiva: surgical excision associated with cryotherapy. *Clinical Ophthalmology (Auckland, NZ)*, 7, p.1889. doi: 10.2147/OPHTH.S50762; PMID: 24092968
- Gichuhi, S., Ohnuma, S.I., Sagoo, M.S. and Burton, M.J., 2014. Pathophysiology of ocular surface squamous neoplasia. *Experimental eye research*, 129, pp.172-182. doi: 10.1016/j.exer.2014.10.015
- Hamam, R., Bhat, P. and Foster, C.S., 2009. Conjunctival/corneal intraepithelial neoplasia. *International ophthalmology clinics*, 49(1), pp.63-70. doi: 10.1097/IIO.0b013e3181924ec3
- Kumar, R., Adhikari, R.K., Sharma, M.K., Pokharel, D.R. and Gautam, N., 2009. Pattern of ocular malignant tumors in Bhairahwa, Nepal. *The internet Journal of Ophthalmology and visual science*, 7(1), pp.1-6.
- Lee, G.A. and Hirst, L.W., 1995. Ocular surface squamous neoplasia. *Survey of ophthalmology*, 39(6), pp.429-450. doi: 10.1016/S0039-6257(05)80054-2
- Mittal, R., Rath, S. and Vemuganti, G.K., 2013. Ocular surface squamous neoplasia—Review of etio-pathogenesis and an update on clinico-pathological diagnosis. *Saudi Journal of Ophthalmology*, 27(3), pp.177-186. doi: 10.1016/j.sjopt.2013.07.002
- Moon, C.S., Nanji, A.A., Galor, A., McCollister, K.E. and Karp, C.L., 2016. Surgical versus medical treatment of ocular surface squamous neoplasia: a cost comparison. *Ophthalmology*, 123(3), pp.497-504. doi: 10.1016/j.ophtha.2015.10.043
- Morii, T., Sumioka, T., Izutani-Kitano, A., Takada, Y., Okada, Y., Kao, W.W.Y. and Saika, S., 2016. A Case of Solitary Nonvascularized Corneal Epithelial Dysplasia. *Case reports in ophthalmological medicine*, 2016. doi: 10.1155/2016/5687285
- Sivkova, N., 2009. Squamous cell carcinoma of the "pure" cornea. *Der Ophthalmologe: Zeitschrift der Deutschen Ophthalmologischen Gesellschaft*, 106(9), pp.826-828. doi: 10.1007/s00347-008-1883-z; PMID: 19806383



Sivkora N et al, 2009 mentioned a case of corneal neoplasia with stromal invasion, needing extensive intervention like lamellar keratoplasty and radiotherapy. So, proper examination, early diagnosis and treatment are very important for a better prognosis of OSSN.

## CONCLUSION

OSSN presenting predominantly as a corneal lesion or as an isolated corneal lesion is rare. Such conditions may be confused with other entities causing diagnostic delay. Retro-illumination is important in clinical diagnosis and delineation of corneal CIN. Early treatment results in good prognosis.