

Original article ● ● ● ●

Surgical treatment and histopathological analysis of proptosis

Rizvi SAR¹, Gupta Y², Gupta M³

¹Assistant Professor, ²Professor, Institute of Ophthalmology

³Associate Professor, Department of Physiology

Jawaharlal Nehru Medical College, AMU, Aligarh, UP, India.

Abstract

Introduction: Inflammations and tumors of the orbit and para-orbital regions may present as proptosis. Management depends on clinical, radiological, histo-pathological and biochemical evaluation.

Objective: To analyze the clinical and histopathological profile of the lesions causing proptosis and to report the outcome of their surgical management.

Materials and methods: In a retrospective study, 25 cases of proptosis due to orbital and paraorbital tumours were analyzed in relation to their age, sex, and clinical and histopathological profiles. CT Scan was considered as the first line investigation modality. According to location and type of tumour, different surgical options like anterior orbitotomy, lateral orbitotomy and medial orbitotomy were considered.

Results: The majority of the patients were of the age group 50-59 years (28 %). Primary orbital tumors were encountered in 15 cases (60 %) and para-orbital in 10 (40 %). Of 15 primary orbital tumors, 7 (46.66 %) were excised by lateral orbitotomy, another 7 (46.66 %) were approached via anterior orbitotomy, whereas 1 (6.67%) was removed by medial orbitotomy. Pediatric orbital tumors were quite common {7(46.66%)}. Three cases of rhabdomyosarcoma, 3 cases of dermoid cyst and 1 case each of optic nerve glioma were found in pediatric age group. The most common benign adult tumor found in our study was pleomorphic adenoma of the lacrimal gland {3 (20 %)}.

Conclusion: The majority of the patients with proptosis are of the age group 50-59 years. Proptosis due to primary orbital tumors is more common than para-orbital tumors. Early diagnosis and timely surgical intervention provide good functional and cosmetic results.

Keywords: orbit, proptosis, tumors, orbitotomy.

Introduction

The eye is not only an organ of vision but also an index of beauty in the human race. Inflammations and tumors of the orbit and paraorbital regions normally present as proptosis which sometimes distort the natural architecture of the eye. The most common cause of

unilateral or bilateral proptosis in an adult is thyroid-related orbitopathy (Leatherbarrow B, 2002). Management of a case of proptosis depends on its extensive clinical, radiological, histopathological and biochemical evaluation. Close co-operation between an oculo-plastic surgeon, otorhinolaryngologist, neurosurgeon, radiologist, oncologist and histopathologist is required for the management of orbital and paraorbital tumors.

Received: 27.10.2009

Accepted:30.12.2009

Correspondence and reprint request to: Dr Yogesh Gupta
B-6, Medical Colony, Aligarh UP 202002, India.

Tel: 0091-571-272 1202; 0091-9837116477,

Fax: 0091 571-270 2758;

E-mail: yogibear3190@hotmail.com

Materials and methods

A total of 25 cases of proptosis due to orbital and paraorbital tumors who presented at the Jawaharlal Nehru Medical College and Institute Of Ophthalmology, Gandhi Eye Hospital, were taken up in this study. The duration of the study was from April 2004 to March 2008. All the patients in the present study underwent detailed history-taking and meticulous examination that included best-corrected visual acuity (BCVA), exophthalmometry, extraocular muscle movements, retropulsion, palpation of orbital margins and eyelids, IOP measurement in different gazes, orbital palpation for thrills and auscultation for bruits, visual field examination and ophthalmoscopy. A detailed general physical examination including the patient's skin and oropharynx, regional and distant lymph nodes and cranial nerves examination was also done. All the patients in the present series underwent radiological investigation; and CT scan was done in all cases to evaluate the extent of tumor and localize the lesion. The lesions were approached as per their anatomical location, size, extent and suspected pathology. Primary orbital tumor was approached by different orbitotomy routes. Anterior orbitotomy either by the trans-conjunctival or trans-cutaneous route was performed for lesions anterior to the equator of the globe and in the anterior intraconal space. All deep-seated lesions posterior to equator and in the intraconal space and lesions lateral to optic nerve were approached by the lateral orbitotomy route. The paraorbital tumors were referred to otorhinolaryngologist or neurosurgeon for their specific management. All the lesions of the present series were biopsied after excision for their histopathological diagnosis and were treated accordingly.

Results

All the patients of proptosis in this study were analyzed with regard to their age, site of involvement, surgical approaches employed and histopathological diagnosis. The age of the patients ranged from 8 years to 65 years. Three patients were below 10 years (12 %). The maximum number of patients was in the age group of 50-59 years, i.e. 7 (28 %).

Primary orbital tumors were encountered in 15 (60 %) cases whereas paraorbital tumors were found in 10 (40 %) cases of proptosis. Lateral orbital tumors were found in 4 cases (26.67 %). A mass in the antero-superior orbit was encountered in 7 (46.66 %) cases,

Table 1
Age distribution of patients (n=25)

Age (years)	Tumor frequency (%)
0-9	3 (12)
10-19	4 (16)
20-29	2 (8)
30-39	2 (8)
40-49	5 (20)
50-59	7 (28)
60-69	2 (8)

intraconal space was involved in 3 (20.0 %) cases and 1(6.66 %) case had a mass in the medial extraconal space. Among the paraorbital tumors, nasopharyngeal lesion was seen in 2 (20 %) cases, primary maxillary mass in 5 (50 %) cases and fronto-ethmoidal mass extending into the orbit in 3 (30 %) cases.

Only the orbital tumors were surgically treated while the paraorbital tumors were referred to ENT surgeons for their specific management. Among the primary orbital tumors in the study, 7 (46.67 %) cases were excised by lateral orbitotomy. (Fig 1a, 1b and 1c) whereas 7 (46.67 %) cases were approached by anterior orbitotomy (Fig 2a and 2b). Two cases of rhabdomyosarcoma were also treated with a combination of radiation and chemotherapy, preceded

Table 2
Location of tumors

Primary orbital tumors		Para-orbital tumors	
Area involved	Number of tumors (%)	Area involved	Number of tumors (%)
Lateral orbital tumors	4 (26.67)	Nasopharyngeal tumors	2 (20)
Antero-superior tumors	7 (46.66)	Maxillary tumors	5 (50)
Intraconal tumors	3 (20.00)	Fronto-ethmoidal tumors	3 (30)
Extra-conal tumor	1 (6.66)		
Total	15 (100)	Total	10 (100)

by anterior orbitotomy for incisional biopsy (Fig 3a & 3b). One (6.67 %) case of extraconal capillary hemangioma was removed by medial orbitotomy (Fig 4a, 4b, 4c and 4d). The histopathological diagnosis of the excised orbital tumors is shown below, in tabulated form (Table 3).



Fig 1a: Downward proptosis in a case of lacrimal gland tumor.

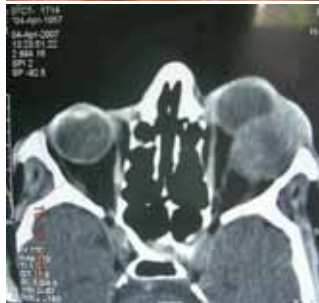

Fig 1b: Axial Computed Tomography showing lateral orbital mass of the same patient.



Fig 1c: Postoperative status (Lateral Orbitotomy) of the same patient.

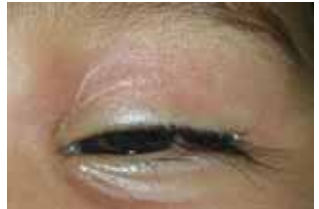

Fig 2a: Superonasal mass in a 2 year old child.

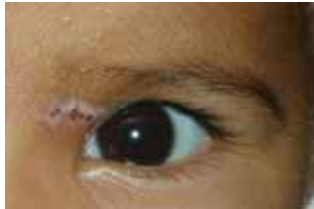

Fig 2b: Postoperative status (Anterior Orbitotomy) of the same patient.

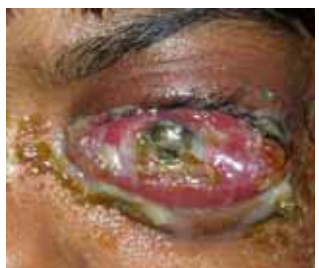

Fig 3a: Rhabdomyosarcoma of left eye.

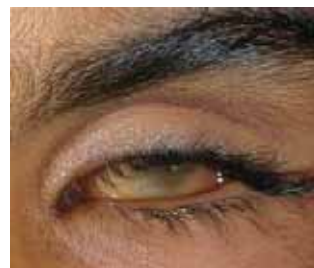

Fig 3b: Post treatment photograph of the same patient.



Fig 4a: Axial and lateral proptosis in a case of capillary haemangioma.

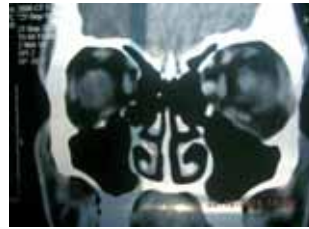

Fig 4b: Coronal Computed Tomography showing mass in medial extraconal space of the same patient

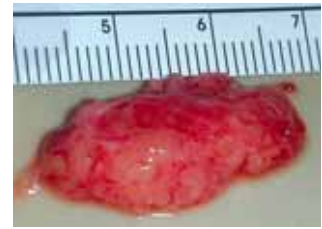


Fig 4c: Excised tumor mass.



Fig 4d: Postoperative status (Medial Orbitotomy) of the same patient.

Table 3
Histopathological diagnosis of orbital tumors

Histopathological diagnosis n=15	Frequency (%)
Cavernous hemangioma	2 (13.33)
Capillary hemangioma	1 (6.66)
Dermoid cyst	3 (20)
Pleomorphic adenoma of lacrimal gland	3 (20)
Lymphoma	1 (6.66)
Pseudotumor	1 (6.66)
Rhabdomyosarcoma	3 (20)
Optic nerve glioma	1 (6.66)

Discussion

The causes of proptosis are numerous. They may be neoplastic, inflammatory, vascular, traumatic or structural in etiology. The neoplastic causes can be further subdivided into two groups: primary orbital tumors and paraorbital tumors involving the orbit. The majority of primary orbital tumors originate between the bony orbital wall and the extraocular muscle cone and 90% of primary orbital tumors present with proptosis (Rootman J, 1988). The roof of the orbit shares common wall with the floor of the frontal sinus, the medial wall of the orbit with the orbital labyrinth, the floor with the maxillary sinus and the orbital apex with the sphenoidal sinus. As a result, the neoplastic lesions from these regions have ready access to the orbital cavity (Kimmelman CP, Konvin GS, 1988). Thus, the paraorbital tumors can invade the orbit in the course of tumor growth.

Pediatric orbital tumors are quite common, as observed in our study (46.66 %). Rhabdomyosarcoma is the commonest primary malignant tumor of the orbit in children. Radiation therapy and systemic chemotherapy has become the mainstay of treatment, based on the guidelines set forth by the Intergroup Rhabdomyosarcoma Study (Crist W, Gehan EA, Razeb AH et al, 1995). In the present study, one case of optic nerve glioma, 3 cases of dermoid and 3 cases of rhabdomyosarcoma were found in pediatric age group. Lateral orbitotomy was the surgical treatment of choice for primary orbital tumors located within the muscle cone, behind the equator of the globe or in the lacrimal gland fossa (Fran Taylor, 2000). The incision of choice is the traditional S-shaped Stallard -Wright incision, extending from beneath the eyebrow laterally and curving down along the zygomatic arch, allowing good exposure of the orbital rim. The newer approaches for lateral orbital exposure are either through an upper lid-crease incision or a lateral canthotomy incision (Narris GJ, Logani SC, 1999). In the present study, 7 (46.66 %) cases were approached by lateral orbitotomy, 7 (46.66 %) cases were excised by anterior orbitotomy and one (6.66 %) case was removed by medial orbitotomy. An anterior orbitotomy is used for the incisional or excisional biopsy of the anterior orbital lesions, biopsy of more posteriorly-placed orbital lesions and for the drainage of hematomas and abscesses. An upper lid skin-crease trans-septal approach is used particularly for superior lesions, whereas the trans-conjunctival approach may be preferred for inferior lesions as this avoids a visible cutaneous scar (Kersten RC,1988). Medial orbitotomy is required for tumors of the medial orbit where the tumor originates medial to the optic nerve, whether intraconal or extraconal. The medial orbit can be approached via a skin incision (Lynch incision), transconjunctival incision, transcaruncular incision or endoscopically depending on the type of lesion and site of location (Leone CR, 1983). In the present case series, we excised a medial orbital capillary haemangioma via the transcaruncular approach.

Orbital and paraorbital tumors quite commonly cause proptosis, though the commonest cause of exophthalmos is dysthyroid ophthalmopathy. In the

present study, the dermoid cyst and pleomorphic adenoma of lacrimal gland were the most frequently occurring primary benign orbital tumors among the pediatric patients and adults respectively. Rhabdomyosarcoma has been described as the commonest soft tissue malignancy of the orbit in children (Kimmelman, 1988) and this corresponds to the result of the present study.

Conclusion

The majority of the patients with proptosis are of the age group 50-59 years. Proptosis due to primary orbital tumors is more common than para-orbital tumors. Early diagnosis and timely surgical intervention provide good functional and cosmetic results. The treatment of orbital and paraorbital tumors needs a multidisciplinary approach. Early diagnosis and timely surgical intervention provides good functional as well as cosmetic results.

References

- Crist W, Gehan EA, Razeb AH et al, 1995). The Third Intergroup Rhabdomyosarcoma Study. *J Clin Oncol*; 13:610-630.
- Fran Taylor, ed. *Orbital Surgery* (2000). In: the foundation of the American Academy of Ophthalmology (Section 7). USA; LEO:100-103.
- Kersten RC (1988). The eyelid crease approach to superficial lateral dermoid cysts. *J Paediatr Ophthlmlol Strabismus*; 25: 48-51.
- Kimmelman CP, Konvin GS (1988). Management of paranasal sinus neoplasm involving the orbit. *The Otolaryngologic Clinics of North America*; 21(1): 77-92.
- Leatherbarrow B (2002). Orbital disorders. In: *Oculoplastic surgery*. United Kingdom: Martin Dunitz; Chapter 16: 177-201.
- Leone CR (1983). Surgical approach to the medial retrobulbar space. *AJO*; 96:1-5.
- Narris GJ, Logani SC (1999). Eyelid crease incision for lateral orbitotomy. *Ophthalmic Plastic Reconstr. Surg*; 15:9-18.
- Rootman J (1988), ed. *Diseases of the orbit*. Philadelphia: JB Lippincott.

Source of support: nil. Conflict of interest: none