

## Management of corneal wounds: some practical tips

Lee SH, MD, FRCS (C), FAAO

### Abstract

Corneal trauma is one of the leading causes of ocular morbidity. This paper aims at providing some practical tips useful for management of corneal wounds.

### Introduction

Laceration of cornea is one of the leading causes of ocular morbidity (Thakker, 2006 and Chang et al, 2008). This paper presents an update on management of such injury, whether medical or surgical, and is directed primarily at the restoration of normal ocular anatomy. The ultimate goal is to prevent secondary complications and maximize the patient's visual prognosis (Hersh PS, Kenyon KR, 1988).

### Injury assessment

A meticulous injury assessment is important in determining the extent of injury.

This should include detection of presence or absence of intraocular foreign body, orbital bony injury or adnexal tissues injury such as lacrimal drainage system injury.

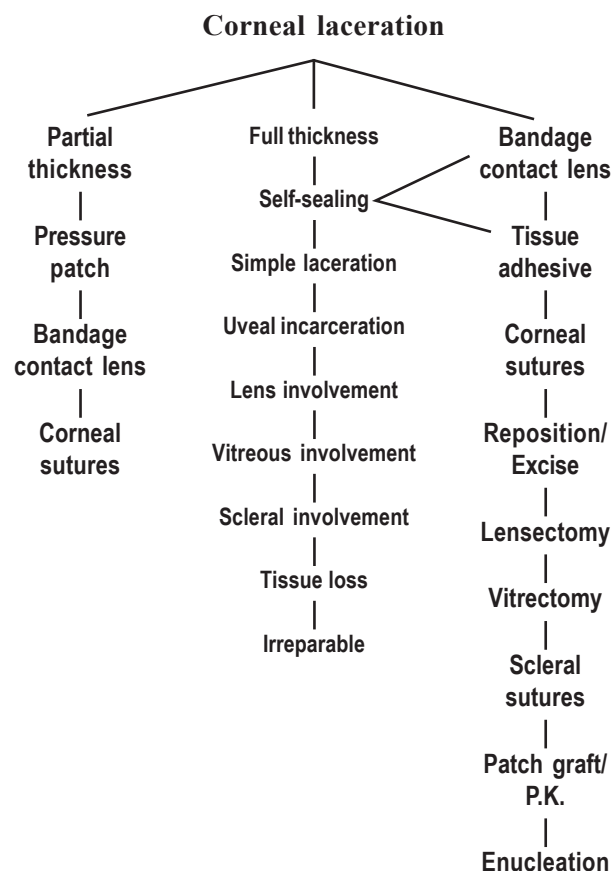
A quick history must be obtained on how it happened, when it happened, past ocular history, past medical history, including current topical and oral medications and allergy.

A short but focused ocular examination should be conducted. Visual acuity, ocular mobility, external examination, anterior and posterior segments examination, including intra ocular pressure if possible should be documented. Auxiliary tests such as X-rays, C.T. scans will help to determine the extent of the injury. All documented details should be neatly written on patient's chart not only for medical record, but for medical-legal purpose if required in the future.

### Open globe injury or not

The primary goal is to determine whether it is an open globe injury (penetrating or perforating) or just a partial thickness corneal laceration, as the former type of injury is always surgically managed, and the latter may be medically or surgically managed. If in doubt, it is best to suture the wound especially if the wound edge is not in good apposition. It is a good principal to follow a flow chart.

### Flow chart of management of corneal laceration



Received: 26.11.2008

Accepted: 08.04.2009

Correspondence and reprint request to: Dr SH Lee, MD, FRCS (C)

Email: lee\_shui@hotmail.com

### Medical management

All suspected cases must be carefully examined to rule out penetration or perforation, such as microscopic leak.

**Seidel's testing** with 2% fluorescein will be helpful. Gentle digital pressure may reveal that it is indeed a self sealing wound.

All self sealing corneal lacerations may be treated with eye patch or bandage contact lens, with broad spectrum antibiotic eye drops frequently. Patient has to be monitored daily on out-patient basis. Any symptom or sign of infection such as infectious keratitis or endophthalmitis should admit the patient to the hospital for more intense treatment. Any sign of anterior chamber becoming progressively shallow, or the corneal wound becoming unstable, suturing of the wound must be considered. Every effort must be made to minimize scarring and surface irregularity. The bandage contact lens should not be removed until the wound is stable, and complete re-epithelialization has occurred.

### Surgical management

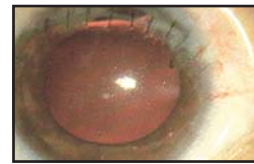If the corneal laceration is full thickness, it should be determined whether it is simple or complex laceration: with or without uveal, crystalline lens, vitreous, retinal or scleral involvement. It is important to detect any corneal tissues loss, and whether it is an irreparably damaged globe.

The primary goal in repairing corneal laceration is to achieve a water tight globe with structural integrity (Segev et al 2007). Other secondary goals will be removal of any lens fragments, vitreous incarceration, uveal tissue incarceration or prolapse and intra-ocular foreign body if they are detected during the surgery. To restore the normal or near normal anatomical relationship is the final goal.

### Simple corneal laceration

Stable wound, with watertight laceration, and formed anterior chamber, 10-0 monofilament nylon may be placed directly across the wound without entering the anterior chamber. The suture has to be 90% in depth through the stroma, 1.5mm in length, and equal in depth on each side of the wound. Some corneal surgeons may think that 100% depth through the stroma will be better, but at least in theory, such suturing would provide a conduit for allowing micro-organisms from external surface to enter the eye.

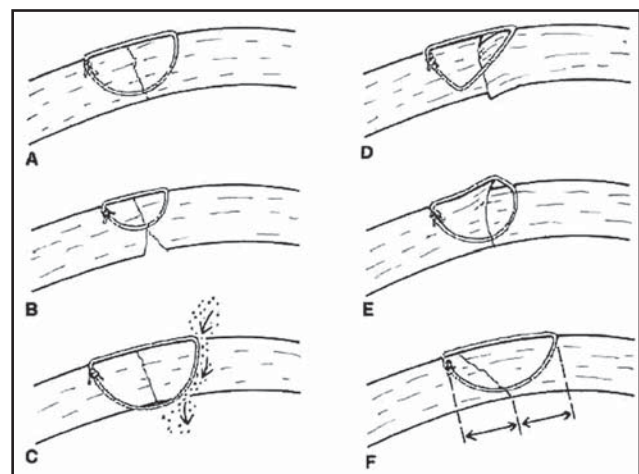
### Figure 1. After suturing of corneal laceration



Incorrect corneal suturing should be avoided since shallow suturing may lead to internal wound gape, suturing with unequal depth may create wound override.

### Figure 2

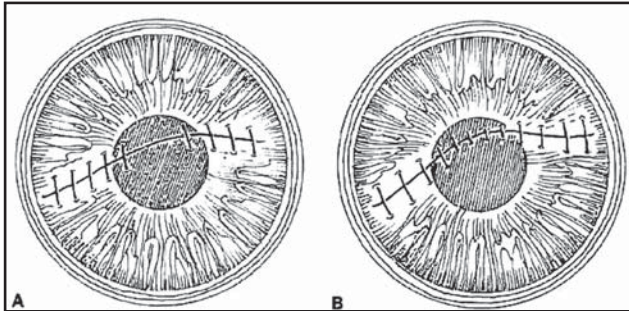
- A. Correct
- B. Wrong –too shallow suturing and internal gape
- C. Wrong –through and through suturing (100% depth) with a conduit
- D. Wrong – unequal distance from each side of the wound with wound distortion
- E. Wrong – suture with unequal depth and distance causing wound override
- F. Correct



Placement of sutures through the visual axis should be avoided. If the laceration has affected the visual axis, the suturing should avoid the central cornea by placing it on either side of the wound but not through the axis, and by ensuring that the suture bites close to the visual axis are short.

**Figure 3**

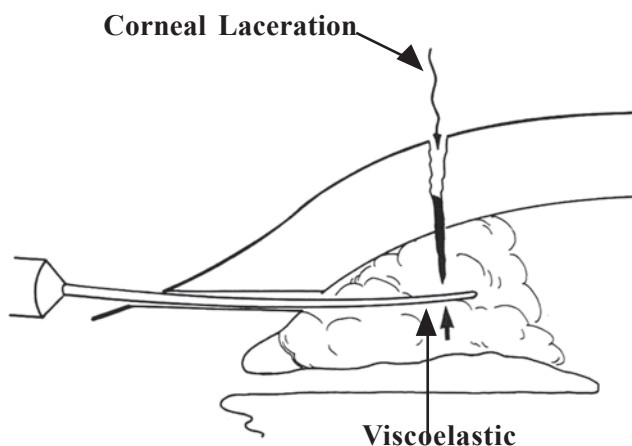
- A. Correct: central cornea - no suture
- B. Wrong: suturing runs through the visual axis



**Unstable wound with shallow or no anterior chamber**

A viscoelastic is used to reform the anterior chamber through a newly created side port. Any incarcerated ocular tissues into the wound should be either excised if contaminated and of longer duration or repositioned if fresh. At times the anterior chamber cannot be formed because of leakage. A temporary suture to close the wound may be required, and subsequent removal will be required once the wound becomes stable, when the accurate appositional way of correct suturing should be carried out.

**Figure 4**  
Viscoelastic material is injected into the anterior chamber through the side port



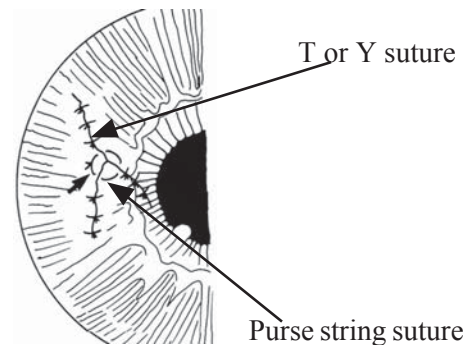
**Complex corneal laceration wound**

The goal is to achieve good wound apposition with minimal distortion (Mackenson et al, 1974). An irregular wound is first subdivided into straight segments with interrupted sutures. Long deep and relatively tight peripheral sutures and short, shallow, appositional sutures near the central cornea may restore the normal corneal dome and surface corneal topography.

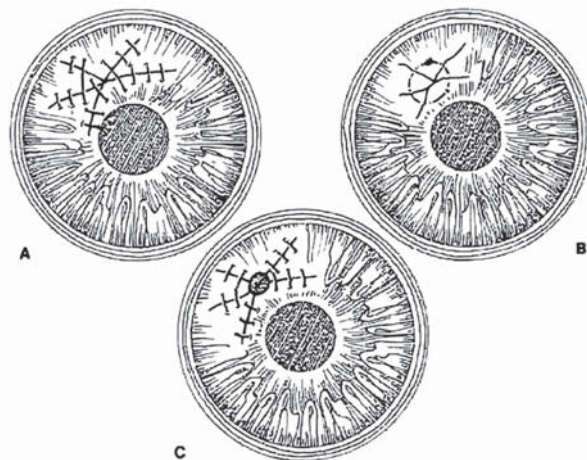
Some of those complex corneal lacerations are illustrated as below.

**Figure 5 a**

A T-or Y- shaped laceration often leaks at the apex and may be difficult to close. A purse string suture is generally effective in closing such laceration.



**Figure 5 b**



Stellate laceration close by (A) bridging sutures, (B) pursestring suture, and (C) multiple interrupted sutures and tissue adhesive in the center

### Corneal laceration with tissue loss

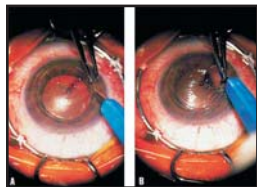
The wound can be divided into central, paracentral and peripheral.

**Central** -with tissue loss is treated with corneal graft.

**Paracentral** -with tissue loss is treated with suturing or tissue glue or combination of the two.

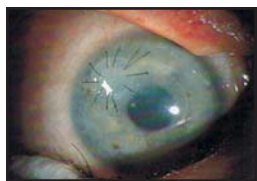**Peripheral** with tissue loss is treated with patch graft.

**Figure 6**



Penetrating keratoplasty for central corneal laceration with tissue loss, removal of lacerated cornea. Curved scissors and supra sharp knife are used instead of a trephine.

**Figure 7**



Final appearance of the cornea after patch graft for peripheral corneal laceration with tissue loss

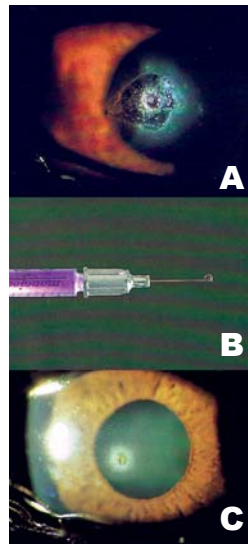
### Use of tissue glue

In most cases of corneal laceration, use of tissue glue (Refojo et al, 1968) is only for adjunct treatment to suturing. It is useful in small puncture wound with leaking, selected small perforated laceration, and paracentral laceration with suturing.

When deciding to use tissue adhesive, the corneal surface is dried with a cellulose sponge and the epithelium surrounding the perforation is debrided. The tissue adhesive (cyanoacrylate) is applied to the edge of the perforation with 25-gauge needle on a tuberculin syringe with least amount or in the form of a bead.

A bandage contact lens (Smiddy WE, 1989) is placed for comfort and to protect the adhesive from being lodged by the eyelids. Frequent follow-ups are necessary to ensure that the perforation is sealed.

**Figure 8**



- A. Punctured corneal wound with leaking
- B. #25 gauge needle on tuberculin syringe with tissue glue in the form of a bead
- C. Final appearance of corneal wound after tissue glue, removal of bandage contact lens. Re-epithelialized corneal surface

### Corneal laceration with involvement of other ocular structures

#### With lens involvement

Depending upon the extent of involvement, lensectomy may be required. Any lens fragment has to be removed, and anterior vitrectomy has to be performed (Cowden JW, Hu BV, 1988).

#### With uveal tissue involvement

The incarcerated uveal tissue has to be repositioned, if fresh or excised, if contaminated and old.

#### With vitreous or retinal tissue involvement

Service of the retina sub-specialist will be required, and it will be a multi-sub-specialty approach.

With intra-ocular foreign body It has to be removed with any means possible.

### Conclusion

It is important to manage corneal laceration according to the flow chart for management of corneal laceration. Use of appropriate surgical techniques of suturing to minimize the corneal scarring, to stabilize the wound and to re-establish normal or near normal anatomical relationship is vital.



A clear understanding of corneal laceration and the use of appropriate surgical approaches may permit the reduction of ocular morbidity and may enhance visual rehabilitation after trauma.

### Reference

Chang CH, Chen CL, Ho CK, Lai YH, Hu RC, Yen YL (2008). Hospitalized eye injury in a large industrial city of South-Eastern Asia. *Graefes Arch Clin Exp Ophthalmol*; 246(2):223-8.

Cowden JW, Hu BV (1988). A new surgical technique for posterior chamber lens fixation during penetrating keratoplasty in the absence of capsular or zonular support. *Cornea*; 7:231-5.

Hersh PS, Kenyon KR (1988): Anterior segment reconstruction following ocular trauma. *Int Ophthalmol Clin*; 28:57-68.

Mackenson G, Faulborn J (1974). Primary and secondary reconstruction of the eyeball after extensive lacerations. *Ophthalmic Surg*; 5:43-9.

Refojo MF, Dohlman CH, Ahmad B et al (1968). Evaluation of adhesives for corneal surgery. *Arch Ophthalmol*; 80:645-56.

Segev F, Assia EI, Harizman N, Barequet I, Almer Z, Raz J, Moisseiev J (2007). Corneal laceration by sharp objects in children seven years of age and younger. *Cornea*; 26(3):319-23.

Smiddy WE (1989). Contact lenses for visual rehabilitation after corneal laceration repair. *Ophthalmology*; 96:293-8.

Thakker MM, Ray S (2006). Vision-limiting complications in open-globe injuries. *Can J Ophthalmol*; 41(1):86-92.

**Source of support: nil. Conflict of interest: none**