



Demographic pattern, clinical features and treatment outcome of patients with infective keratitis in the eastern region of Nepal

Lavaju P¹, Arya SK¹, Khanal B², Amatya R², Patel S¹

¹Department of Ophthalmology

²Department of Microbiology

B P Koirala Institute of Health Sciences, Dharan, Nepal

Abstract

Background: Corneal ulcer is one of the major causes of monocular blindness in developing countries.

Objective: To determine demographic pattern, risk factors, microbiological pattern and treatment outcome of infective keratitis.

Materials and methods: A retrospective analysis of hospital records of 44 patients with clinically-diagnosed infective keratitis presenting to B.P. Koirala Institute of Health Sciences in the eastern region of Nepal was carried out.

Outcome measures: The parameters studied were risk factors and organisms responsible for keratitis.

Results: The infective keratitis was mostly prevalent among the males between 21-40 years of age (50%). 79.5 % of them were engaged in agricultural work. A history of corneal injury was found in 30 eyes (68.1%). Vegetative matter was the most common agent of trauma in 17 (56.6%). Culture positivity for micro-organisms was observed in 20 (45.5%) samples. Of these, 8 (40%) patients had purely bacterial corneal ulcer. Purely fungal growth was seen in 4 (20%) and mixed in 8 (40%). *Staphylococcus aureus* was the most commonly isolated bacteria (70%). The other bacteria included *Pseudomonas species*, *E. coli* and *Acinetobacter*. *Aspergillus species* was the most common fungal organism isolated in 8 (40%) samples. 65.9 % of the patients improved with medical treatment alone. Perforation, endophthalmitis and panophthalmitis were the common complications encountered in 11.3%, 4.5% and 4.5% respectively.

Conclusion: Corneal ulcer is prevalent in males, predominantly amongst the farmers. Ocular trauma with vegetative matter is the commonest predisposing factor. *Staphylococcus aureus* and *Aspergillus species* are the most commonly isolated organisms in corneal ulcers.

Keywords: corneal ulcer, fungal keratitis, ocular trauma

Introduction

Corneal infections are the second most common cause of monocular blindness after un-operated cataract in developing countries (Upadhyay MP et al 1991, Gonzales CA et al 1996, Whitcher JP et al 2001). The incidence of microbial keratitis varies from 11 per

100,000 persons/ year in the United States (Erie JC et al 1993) to 799 per 100,000 persons/ year in Nepal (Upadhyay MP et al 2001).

The etiology and epidemiological pattern of corneal ulceration varies significantly from country to country and even from region to region (Leck AK et al 2002). Specific treatment requires quick and accurate identification of the causative micro-organisms (Leck AK et al 2002). The associated ocular morbidity due to corneal ulcer is the result of several factors and its management depends on the availability of diagnostic facilities.

Received: 10. 01. 2009

Accepted: 06.07.2009

Correspondence and reprint request to: Dr Poonam Lavaju, MD
Assistant Professor

Department of Ophthalmology

B P Koirala Institute of Health Sciences

Dharan, Nepal

Tel: 00977-25-525555,

Fax: 00977-25-520251

Email: ophth_eye@yahoo.com

In order to develop a comprehensive strategy for the diagnosis, treatment and ultimately for the prevention of blindness due to corneal infections, accurate identification of the causative organisms and the etiological factors predisposing to the ulceration is important.

The purpose of this study was to find out the demographic pattern, microbial pattern and treatment outcome of patients with infective keratitis seen at B.P. Koirala Institute of Health Sciences (BPKIHS) in the eastern region of Nepal.

Materials and methods

A retrospective study of records of patients hospitalized with clinical diagnosis of infective keratitis at BPKIHS in eastern Nepal was done during the period of 1st January 2007 to 31st July 2008. Corneal ulceration was defined as a loss of the corneal epithelium with underlying stromal infiltration and suppuration associated with signs of inflammation with or without hypopyon. Ulcers with typical features of viral infection and healing ulcers were excluded. Similarly, Mooren's ulcer, interstitial keratitis, sterile neurotrophic ulcers, and any ulcer associated with autoimmune conditions were excluded. Keratitis, whose microbiological examination was not done, was also excluded.

A standardized form was filled out for each patient, documenting socio-demographic features, duration of symptoms, predisposing factors, history of corneal trauma, traumatizing agents, associated ocular conditions, other systemic diseases, therapy received prior to presentation and visual acuity at the time of presentation and of clinical examination.

Slit-lamp biomicroscopy examination was done for all the patients. The size of the epithelial defect after staining with 2% fluorescein was measured and recorded in millimeters. In similar fashion the size and depth of the stromal infiltrate was recorded. A sketch of each ulcer was drawn on the form using standardized frontal and cross-sectional diagrams. The presence or absence of hypopyon was recorded and the height was measured in millimeters.

Associated ocular conditions such as blepharitis, trichiasis, lid abnormalities, conjunctivitis, dacryocystitis, corneal degeneration, dry eyes, bullous keratopathy and pre-existing viral keratitis were noted. The use of

contact lenses and of topical antibacterial agents, antifungal agents, corticosteroids and other systemic combinations were also recorded.

After detailed ocular examination, corneal scraping from each ulcer was done using aseptic technique and a flame sterilized Kimura spatula or a no. 15 Bard-Parker blade. The procedure was performed under magnification of a slit-lamp or operating microscope or a binocular magnifying loupe after instillation of 4% lignocaine (lidocaine). The material obtained from the leading edge and the base of each ulcer was initially inoculated directly onto solid media such as sheep's blood agar, chocolate agar, and Sabouraud's dextrose agar in a row of C-shaped streaks. Deep inoculation in liquid media such as brain heart infusion broth was also done. It was also spread onto labeled slides for 10% KOH wet mount, Gram staining, and Giemsa staining. Meticulous care was taken in collection of material and its aseptic transfer to the appropriate culture media.

Microbial cultures were considered significant if growth of the same organism was demonstrated on more than one solid phase medium, and/ or if there was confluent growth at the site of inoculation on one solid medium, and/or if growth of one medium was consistent with direct microscopic findings (that is, appropriate staining and morphology with Gram-stain) and/or if the same organism was grown from repeated scraping.

Treatment was started depending on the clinical type of keratitis and the organisms identified. Fortified cefazolin 5% and fortified tobramycin 1.4% eye drops were given for bacterial keratitis. For fungal, 5% natamycin eye drops and fuconazole eye drops. Systemic antifungals were given where ever seen necessary. Antibiotics were progressively tapered according to the clinical response.

Results

Epidemiological characteristics

Forty-four patients with the clinical diagnosis of infective keratitis meeting the inclusion criteria were included in the study. Twenty-six (59%) of them were male and 18(40.9%) were female (M: F= 4:1). Ulcers were more prevalent in the middle age groups, between 21- 40 years of age (50%), with a range of 6- 73 years (*Figure 1*). Most of the patients 33 (75%) were from rural community and 79.5% were from an agriculture group (*Figure: 2*).

Figure 1

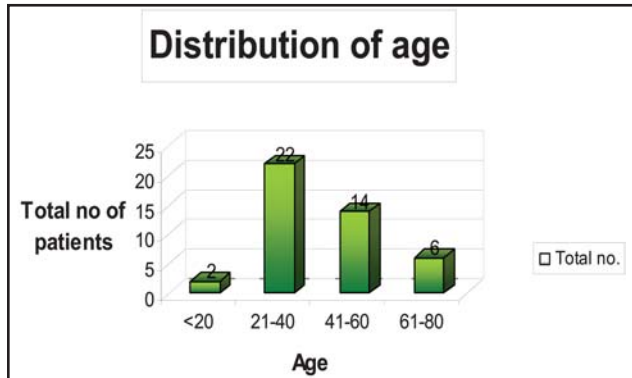
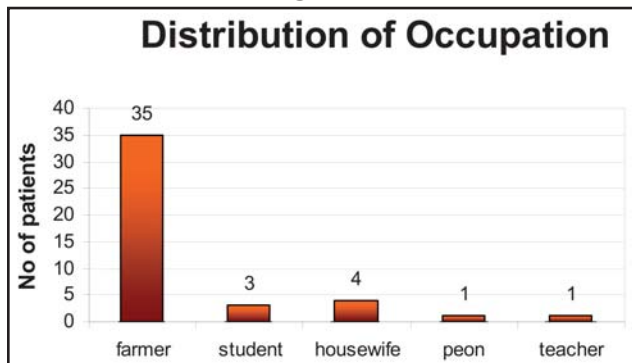


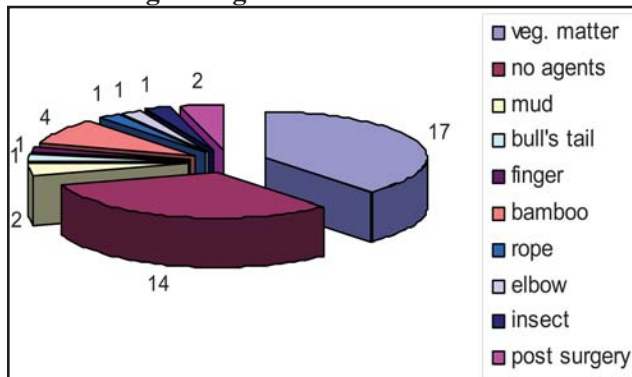
Figure 2



History of corneal injury was the most common risk factor, encountered in 30 eyes (68.1%). Trauma with vegetative matter was found to be the most common cause seen in 17 (56.6%) patients (*Figure: 3*). Most of the patients were using topical eye drops at the time of presentation. Twenty (45.4%) of them were using antibiotics, 9 (20.4 %) antifungal, 2 (4.5 %) steroids and in 43 % (19) details were not available. Visual acuity

Figure 3

Etiological agents of infective keratitis

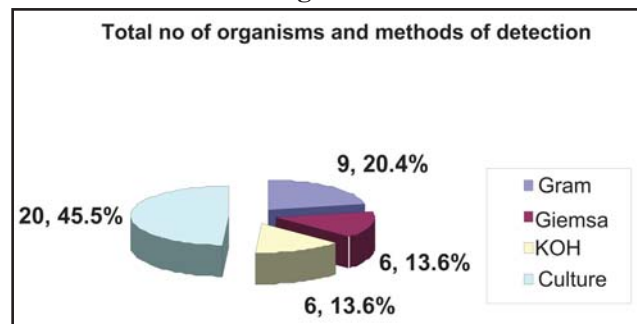


on presentation ranged from 6/24 to no perception of light (NPL). The right eye was involved in 19 eyes (44 %) and left eye in 25 eyes (56 %). Clinically mixed type of keratitis was seen in 16 eyes (36.4%), bacterial in 18 (40.9%) and fungal keratitis in 10 (22.7%).

Microbiological characteristics

Out of 132 specimens examined, direct microscopy was positive in 18 (13.6%) specimens. The Gram stain detected micro-organism in 9 (20.4%), Giemsa in 6 (13.6%) and KOH in 6 (13.6%) specimens (*Figure: 4*). Out of these stain-positive specimens, 75% (6) were positive for Gram +ve cocci, 25% (2) Gram -ve bacilli, 28.5% (2) for yeast and 85.7% (6) showed filamentous fungi.

Figure 4



Culture was positive in 20 samples (45.5%). Out of 20 samples, in 16 eyes (80%) bacteria were identified and 12 eyes (60%) showed fungal growth.

Out of these 20 culture-positive samples, 40% (8) had pure bacterial growth, 20% (4) pure fungal growth and 40% (8) mixed growth (bacterial and fungal).

Out of 20 culture-positive samples, 70% (14) grew *Staphylococcus aureus*, 15% (3) *pseudomonas*, 5% (1) *Acinetobactor*, 10% (2) *E.coli*, 40% (8) *Aspergillus sp*, 10% (2) *fusarium* and 10% (2) *dematiaceous fungi*.

Culture positivity could be correlated with direct microscopy in 82.3% of samples. *Staphylococcus aureus* was the most commonly isolated bacterial organism representing 70% of all positive bacterial growth. *Aspergillus* was seen as the most common isolate accounting for 66.6% of fungal positive samples. Other organisms isolated were *pseudomonas species*, *Acinetobactor*, *E. coli*, *candida* and *fusarium*.

Sensitivity pattern

Most of the bacterial isolates were sensitive to commonly used antibiotics. 92.8% of *Staphylococcus aureus* isolated were sensitive to amikacin. They were also found sensitive to tobramycin, chloramphenicol, ceftriaxone, ofloxacin and tetracyclines. *Acinetobacter*, *E.coli* and *pseudomonas* were also found sensitive to cephalosporins, fluoroquinolones, tetracyclines and aminoglycosides. They were found to be resistant with trimethoprim.

Treatment and clinical outcome

Eleven patients received topical antibacterial alone, 6 antifungal alone and 27 required both drugs. 65.9% improved with medical treatment alone. Complications were seen in 11 patients of which two (4.5%) had impending perforation, 5(11.3%) perforation, 2(4.5%) developed panophthalmitis and 2 (4.5%) endophthalmitis.

Nine patients required therapeutic penetrating keratoplasty (TPK). Of these one patient had persistent epithelial defect after the TPK requiring amniotic membrane graft (AMT) and two needed intracameral antibiotics. Bandage soft contact lens (BSCL) was applied in 4 patients for persistent epithelial defect which healed later on. Two patients with panophthalmitis and the other with perforated corneal ulcer with no perception of light required evisceration.

Discussion

Corneal ulcer was predominantly seen in males with a ratio of M: F= 4:1. This was similar to other studies done by Gonzales CA et al 1996 and Liesegang TJ et al 1980. This may be due to the fact that males are mainly involved in outdoor activities. Corneal ulcer was more prevalent in the middle-age group between 21-40 years (50%). While analyzing a similar set of data from Nepal, Upadhyay MP et al 1991 found that ulceration was more common in patients between 41-50 years of age.

A majority of keratitis was seen in the agricultural group (75%), which was similar(72%) to other studies done by Upadhyay MP et al (1991) and Srinivasan M et al in 1997 (78.8%); but a marked contrast was seen with the study done in Ghana where only 16.1% were involved in agriculture activity. This could be because of the difference in the pattern of occupation.

Corneal injury has always been identified as a cause of microbial keratitis (Upadhyay MP et al 1991, Srinivasan M et al 1997). In our study, a history of corneal injury was seen in 30 eyes (68.18%). Similarly, corneal injury has been reported as the most common cause for corneal ulcer in other studies also (Upadhyay MP et al, 2001& Liesegang TJ et al; 1980). Trauma with vegetative matter was found to be the most common cause in 56.6%. This could be explained by the fact that most of our patients were from an agriculture community. Most of the patients were using topical eye drops at the time of presentation to the hospital (79.5%).

Laboratory investigations

Micro-organisms were isolated from 20 cultured ulcers (45.5%). These findings were comparable to other studies done in Ghana (Hagan et al 1995), where 57.3% were culture positive. Similarly, 50% culture positivity was reported by Upadhyaya et al (1982), 67.8% by Khanal et al (2005), and 68.4% by Liesegang TJ et al (1980). These reports, however, are less than the 80% isolation reported again by Upadhyaya et al in 1991 and 81.7% from Bangladesh (Dunlop et al, 1994; Katz et al, 1983). The lower rate of isolation in our study could be attributed to empirical use of topical antibiotics before presentation to our hospital.

Culture

Bacteria were isolated in 16 (80%) samples and fungus in 12 (60%) of culture-positive samples. Out of these 20 culture positive samples, 40% (8) had pure bacterial growth, 20% (4) pure fungal growth and 40% (8) mixed growth (bacterial and fungal).

Upadhyay et al in 1991 reported pure bacterial cultures in 63.2%, pure fungal in 6.7% samples and 10.1% mixed growth of bacteria and fungi. In another study done in Nepal by Khanal et al in 2005, pure fungal growth was seen in 47.8%, pure bacterial in 34% and mixed in 18.2% of culture-positive cases.

Srinivasan et al in 1997 reported pure bacterial cultures in 47.1%, pure fungal in 46.8% and mixed growth in 5.1% of culture-positive samples. Laspina et al in 2004 reported positive culture in 79%, of which 51% had bacterial, 26% fungal and 29% mixed type of growth. Of 20 (40%) bacterial isolates, 14(70%) were positive for *Staphylococcus aureus*. The second most common

bacteria was *Pseudomonas*, accounting for 15%. Khanal et al reported *Staphylococcus aureus* (93, 56.7%) as the commonest bacterial agent and *Streptococcus pneumoniae* (33, 20%) was seen as the second most common organism. In study reported by Upadhyay et al in 1991 and Srinivasan et al in 1997, *Staph pneumoniae* were predominantly seen accounting for 31.1% and 44.3% respectively. *Aspergillus species* was seen as most common isolates accounting for 8 (66.6%) of fungal positive isolates. Other fungal organisms less dominant in the scene in our study were *Candida*, *Fusarium* and dematiaceous fungi.

In a study reported by Khanal et al from BPKIHS, Nepal in 2005, the commonest fungal pathogen was *Aspergillus species* in 38.4% followed by *Fusarium species* in 22%.

Upadhyaya et al in 1991 in their study found *Aspergillus species* accounting for 47% of all fungal isolates, followed by *Candida species* (13.2%) and *Fusarium species* (11.7%).

In a study done by Srinivasan M et al the most common fungal pathogen isolated was *Fusarium species*, representing 47.1% of all positive fungal cultures, followed by *Aspergillus species* (16.1%). Similarly, *Fusarium species* dominated in studies reported by Hogan et al from Ghana (52%) and by Liesegang and Forster from South Florida (61%). Bharathi et al in 2003 did a retrospective review of all culture-positive fungal keratitis and found *Fusarium species* to be the predominant fungi isolated (42.82%), followed by *Aspergillus species* (26%).

This difference in fungal pathogens may be explained by differences in climate and environment (Araujo et al 2004).

Conclusion

Microbial keratitis remains a therapeutic challenge and a vision-threatening condition. The incidence of microbial keratitis is significantly higher in males, individuals with agricultural activity and following corneal injury. *Staphylococcus aureus* and *Aspergillus* are the most common isolates. Early isolation of causative organism and treatment with intensive ocular antibiotics represent decisive steps in the management of corneal ulcer. Since our sample

size is small, a further study looking at the predictability of predisposing factors would be clinically valuable.

References

- Bharathi MJ, Ramakrishnan R (2002). Epidemiological characteristics and laboratory diagnosis of fungal keratitis. A three year study. *Indian J Ophthalmol*; 51:315-21.
- Carmichael TR, Wolpert M, Koornhob HJ (1985). Corneal ulceration at an urban African hospital. *Br J Ophthalmol*; 69:920-926.
- Di Bisceglie AM, Carmichael TR (1987). Factors predisposing to central corneal ulceration in a developing population. *S Afr Med J*; 71:769-770.
- Dunlop AA, Wright ED, Howlader SA, Nazrul I, Husain R, McClellan K et al (1994). Suppurative corneal ulceration in Bangladesh: a study of 142 cases examining the microbiological diagnosis, clinical and epidemiological features of bacterial and fungal keratitis. *Aust NZ J Ophthalmol*; 22:105-110.
- Erie JC, Nevitt MP, Hodge DO, Ballard DJ (1993). Incidence of ulcerative keratitis in a defined population from 1950 through 1988. *Arch Ophthalmol*; 111:1665-71.
- Gonzales CA, Srinivasan M, Whitcher JP, Smolin G (1996). Incidence of corneal ulceration in Madurai District, South India. *Ophthalmic Epidemiol*; 3:159-166
- Hagan M, Wright E, Newman M, Dolin P, Johnson G (1995). Causes of suppurative keratitis in Ghana. *Br J Ophthalmol*; 79:1024-1028
- Katz NN, Wadud SA, Ayazuddin M (1983). Corneal ulcer disease in Bangladesh. *Ann Ophthalmol*; 15:834-837
- Khanal B, Deb M, Panda A, Sethi S H (2005). Laboratory Diagnosis in Ulcerative Keratitis *Ophthalmic Res*; 37:123-127.
- Laspina F, Samudio M, Cibils D et al (2004). Epidemiological characteristics of microbiological results on patients with infectious corneal ulcers: a 13-year survey in Paraguay. *Graefes Arch Clin Exp Ophthalmol*; 242(3):204-9.

- Leck AK, Thomas PA, Hagan M, Kaliyamurthy J, Ackuaku E, John M et al (2002). Aetiology of suppurative corneal ulcers in Ghana and south India, and epidemiology of fungal keratitis. *Br J Ophthalmol*; 86:1211-15.
- Liesegang TJ, Forster RK (1980). Spectrum of microbial keratitis in south Florida. *Am J Ophthalmol*; 90:38- 47
- Mahajan VM (1985). Ulcerative keratitis: an analysis of laboratory data in 674 cases. *J Ocul Ther Surg*; 4:138-141.
- Ormerod LD (1987). Causation and management of microbial keratitis in subtropical Africa. *Ophthalmology*; 94:1662-1668.
- Sharma S, Srinivasan M, George C (1993). The current status of *Fusarium* species in mycotic keratitis in south India. *Indian J Med Microbiol*; 11:140-147.
- Srinivasan M, Christine A Gonzales et al (1997). Epidemiology and aetiological diagnosis of corneal ulceration in Madurai, south India. *Br J Ophthalmol*; 81:965-971.
- Upadhyay MP, Karmacharya PC, Koirala S, Tuladhar NR, Bryan LE, Smolin G et al (1991). Epidemiologic characteristics, predisposing factors, and aetiologic diagnosis of corneal ulceration in Nepal. *Am J Ophthalmol*; 111:92-99.
- Upadhyay MP, Karmacharya PC, Koirala S, Shah DN, Shakya S, Shrestha JK et al (2001). The Bhaktapur eye study: ocular trauma and antibiotic prophylaxis for prevention of corneal ulceration in Nepal. *Br J Ophthalmol*; 85:388-92.
- Whitcher JP, Srinivasan M, Upadhyay MP (2001). Corneal blindness: a global perspective. *Bull World Health Organ*; 79:214-21.

Source of support: nil. Conflict of interest: none