

## Review article

## Post-operative capsular opacification

Raj S M, Vasavada A R, Kaid Johar S R, Vasavada V A, Vasavada V A

Iladevi Cataract and IOL Research Centre<sup>1</sup>  
Raghudeep Eye Clinic, Gurukul Road, Memnagar<sup>2</sup>  
Ahmedabad 380052, Gujarat, India<sup>3</sup>

**Abstract**

Post-operative capsular opacification (PCO) is a multifactorial physiological consequence of cataract surgery. Opacification involving the central posterior capsule has a significant impact on high and low contrast acuity and low contrast sensitivity. The assessment of PCO on cadaver eyes, experimental studies and culture models and in clinical studies has provided an understanding of its pathogenesis. The proliferation, migration and abnormal differentiation of residual lens epithelial cells and fibers in the capsular bag have been implicated in the pathogenesis of PCO. The incidence and severity of PCO correlates to the use of surgical techniques, intraocular lens (IOL) optic edge designs and IOL materials. This article summarizes the clinical studies with recommendations for retarding the development of central PCO. It discusses experiments with pharmacological agents broadly categorized as anti-inflammatory, immuno-modulating, antiproliferative, antiadhering and antitransdifferentiating agents for the prevention of PCO. These studies will remain critical for future endeavors undertaken for the eradication of PCO.

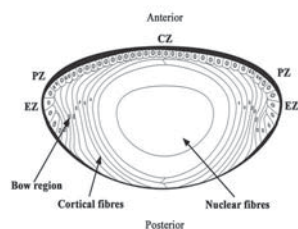
**Key words:** posterior capsular opacification, capsular opacification, cataract, crystalline lens, phacoemulsification

**Introduction**

Cataract is an opacification of the transparent crystalline lens. The lens is a transparent, biconvex, elliptical, semi-solid and avascular body. It is enveloped by a thick capsule, which is a basement membrane of the lens epithelium. The lens epithelial cells (LECs) line the interior surface of the anterior, pre-equatorial, and equatorial regions of the lens capsule (Figure 1). In the

equatorial region of the lens, the LECs undergo terminal differentiation to form lens fibers that are laid down in a concentric manner. From the lens capsule to the center of the lens, these concentric layers of lens fibers are identified broadly as cortex and nucleus. The nucleus contains the oldest lens fibers while the newer ones lie superficially in the cortex. Generally, cataract is associated with old age; however, it may be present in neonates or may develop at any time in the lifespan of an individual. The most common risk factor of cataract is aging. Other risk factors are exposure to ultraviolet (UV) light, inadequate nutrition, cigarette smoking, high alcohol intake, diabetes, and long-term use of antipsychotic medications or steroids (Harding, 1991). Epidemiological studies have emphasized a relationship between sunlight, particularly long wavelength UV (300-400 nm) and UV B (290-320 nm), and the formation of cataracts (Taylor et al 1988; McCarty et al 2002). Cataract leads to dimness of

Figure 1: The anatomy of the human crystalline lens.



Received: 02.12.2008. Accepted: 20.12.2008

Correspondence and reprint requests to: Dr Abhay R. Vasavada  
Iladevi Cataract and IOL Research Centre, Raghudeep Eye Clinic,  
Gurukul Road, Memnagar, Ahmedabad - 380 052, Gujarat, India  
Fax: 91-79-7411200  
E-mail: shetalraj@yahoo.com, icirc@abhayvasavada.com

**Commercial interest declaration:** The authors do not have any commercial connection and/or interest in marketing any product, instrument or piece of equipment discussed in the manuscript.

vision while focusing either on distant or near objects and corrective glasses may or may not help rectify it. The only viable option for treating cataracts is to extract it surgically and replace it with an artificial intraocular lens (IOL).

Previously, in intracapsular cataract extraction, the whole lens along with the entire capsule was extracted. In this method, the LECs are completely removed but there is no capsule left for IOL implantation. In the modern approach to extracapsular cataract extraction, the surgeon extracts all the lens fibers but leaves behind an intact posterior capsule and peripheral anterior capsule of the capsular bag for IOL implantation. Along with the residual capsule, LECs that have the potential to lay down cellular products are also left behind. These again cause opacification, which is referred to as capsular opacification. Thus, capsular opacification is a physiological postoperative consequence of an uneventful, uncomplicated, extracapsular cataract surgery. Capsular opacification is different from the intraoperative opacification that takes place in the intact lenses. It is known as a plaque which can either be in the anterior and/or posterior capsule. Plaques are frequently associated with white mature cataract (Vasavada et al 1997).

## 1. Classification

Postoperative capsular opacification can be classified based on its location into anterior and posterior capsule opacification (Figure 2A to 2E).

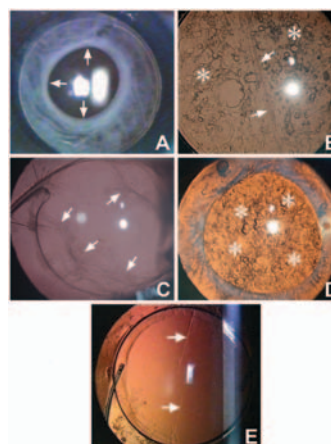
### 1.1 Anterior capsule opacification (ACO)

Opacification of the residual peripheral anterior capsule is known as anterior capsule opacification (Figure 2A). This is pronounced in eyes in which a continuous curvilinear capsular opening overlaps the IOL edge and peripheral anterior IOL surface (Ishibashi et al 1993, Obstbaum 1998). This opacification sets in by the first postoperative month and continues until 6 months (Kimura et al 1998). Some studies have cited the IOL material and the IOL design as influencing factors for ACO (Salika et al 2003; Sacu et al 2004). An analysis of the opacified anterior capsule lying over the IOL can provide inference on the chemical and physical properties of the different IOL materials. Increased capsulorhexis contraction has been noted following implantation of silicone IOLs with sharp optic edges (Saika et al 2003) or a plate-haptic silicone design.

ACO has been observed to be the lowest with acrylic IOLs (Werner et al 2001). The incidence of ACO and contraction is high in eyes with retinitis pigmentosa (Jackson et al 2001) and in diabetic patients (Elgohary et al 2006). Werner et al have clinically graded ACO from 0 to IV (Werner et al 2001). A histopathological examination of the opacified anterior capsule of rabbits showed fibroblast-like cells, presumably transformed from LECs (Hara et al 1992).

Figure 2: Eyes showing various forms of capsular opacification.

- A. Extensive anterior capsule opacification.
- B. Mixed type of PCO with fibrous (arrow) and pearl type areas (asterisk).
- C. Fibrous form of posterior capsule opacification (arrow).
- D. Proliferative or pearl form of posterior capsule opacification (asterisk).
- E. Linear posterior capsule opacification.



The increased capsulorhexis contraction could be a hindrance, especially during examination of the peripheral fundus. Reducing ACO is especially important because it can cause decentration of the IOL. With multifocal IOLs being used, it is of paramount importance to maintain good centration to achieve a good visual outcome (Baumeister et al 2005). Aspiration of LECs from the anterior capsule during cataract surgery has been shown to reduce the capsulorhexis aperture contraction 3 months after cataract surgery (Hanson et al 2006). In our clinical trial, scraping of the anterior capsule to aspirate the LECs was not mandatory when considering implantation of the AcrySof IOL (Vasavada et al 2008).

## 1.2 Posterior capsular opacification (PCO)

Posterior capsular opacification, referred to as 'secondary cataract' or 'after cataract', develops over the clear posterior capsule a few months to a few years after an uneventful cataract surgery (Figures 2A, 2B, 2C). PCO results from the growth and abnormal proliferation of LECs on the capsule at the time of cataract surgery. These cells migrate to the posterior capsule where they approach the central visual axis and cause visual axis obscuration, resulting in dimness of vision.

The PCO has two forms, fibrous and pearl. Sometimes a combination of both is also found (Figure 2B). The LECs that line the anterior capsule are believed to be responsible for fibrous PCO (Figure 2C). Clinically, it is seen as a wrinkling on the posterior capsule at the site of fusion of the anterior and posterior capsules. A histological examination of the fibrous PCO shows extracellular matrix (ECM) accumulation and the presence of elongated fibroblast cells positive to vimentin and alpha-smooth muscle actin ( $\alpha$ SMA) (Shirai et al 2004). The LECs lining the pre-equatorial zone are responsible for the pearl or proliferative PCO (Figure 2D). On examination, it shows clusters of swollen, opacified, differentiated LECs called bladder or Wedl cells (Apple et al 1992).

## 1.3 Other forms

The interlenticular opacification develops after cataract surgery between 2 intraocular lenses (IOLs) placed in the capsular bag (Spencer et al 2002). Linear posterior capsule opacification along persistent striae has also been noted (Figure 2E). The striae appear to create a channel that allows epithelial cells to bypass the barrier created by the square-edge design of the IOL and migrate posteriorly in a linear pattern (Vasavada et al 1999; Wolken et al 2001). These can cause visual difficulties in some patients.

## 2. Incidence and impact

The incidence of PCO is known to range from as high as 50% to as low as <5% in eyes undergoing cataract surgery for uncomplicated senile cataracts (Schmidbauer et al 2002; Dholakia et al 2004; Thompson et al 2004). PCO reduces visual acuity when the central area (inside the pupillary aperture) is involved (Buehl et al 2005). PCO within the central 3 mm zone of the posterior capsule affects high contrast sensitivity,

low contrast acuity, and sensitivity psychophysical test results with differing degrees of sensitivity. Forward light-scatter is the most sensitive, followed by contrast sensitivity and visual acuity (Meacock et al 2003). The amount of PCO and the size of the area analyzed are relevant since this could interfere with the appropriate interpretation of findings on scanning with a laser polarimetry (Meacock et al 2003).

## 3. Assessment and analysis

Different methodologies have been used in experimental and clinical studies.

### 3.1 Human autopsy studies

An examination of human autopsy eyes from the posterior (Miyake-Apple) view, complemented by microscopic analyses, is useful in evaluation of IOL-capsular bag interaction, role of the surgical technique, and evaluation of new IOL designs (Izak et al 2004; Werner et al 2005), in retarding development of central PCO.

### 3.2 Experimental studies and culture models

Animal studies and in-vitro models have been used to assess the mechanism of PCO formation (Jacob 1987; Tetz and Wildeck, 2005). The development of PCO is faster in rabbits and has been found to be suitable for studies to explain human PCO development (Wallentin et al 2002). In in-vitro models, the LECs are cultured either in a medium or in capsular bags prepared from porcine eyes (Choi et al 2004) or human cadaver eyes (El-Osta et al 2003). Culture of animal LECs (de Jong-Hesse et al 2005; Mansfield et al 2004), human LECs, and human epithelial cell lines (McLean et al 2005; Oharazawa et al 2005) have been used to study the mechanisms involved in the pathogenesis of PCO. Culture studies can also detect potential therapeutic targets in the treatment of PCO. A digital quantification of the cell migration onto the posterior capsule and capsule contraction can also be done in these models (Wong et al 2004).

### 3.3 Clinical studies

In clinical studies, PCO can be assessed by either comparing the presence or absence of PCO within the central visual axis or comparing the Nd:YAG capsulotomy rates (Ernest 2003; Auffarth et al 2004). PCO-induced loss of contrast sensitivity has also been used as a method for clinical studies on PCO (Buehl et

al 2005). However, these are subjective comparisons, which rely on the patients' perceptions of the difficulties involved and need longer follow-up before a conclusion can be arrived at. Another option is to assess PCO on slit-lamp-acquired retro-illumination images after complete mydriasis. This is, however, subjectively graded based on the severity of PCO. The uneven illumination and low resolution of the images obtained with a slit lamp has led to the increasing use of digital images.

Digitally acquired retro-illumination photography allows quick acquisition of PCO images. It provides excellent image quality and high reproducibility. This technique forms a sound basis for subjective grading of the intensity of PCO (score 0 to 4) (Buehl et al 2002) as well as for automated quantification of PCO with new software systems. These systems can detect early progression of PCO as well as visually significant PCO. Images with no clinical PCO produce very low scores in the analysis (Aslam et al 2005). Several software systems are available for analysis of PCO on digitally acquired retroilluminated images such as Evaluation of Posterior Capsule Opacification (EPCO) (Tetz and Wildeck, 2005) and the Automated Quantification of After-Cataract (AQUA) automated PCO analysis program (Findl et al 2003).

### 3.4 Analysis

In the POComan software, images are analyzed by a set protocol of defining the area of the posterior capsule, removing the Purkinje light reflexes by intensity segmentation, contrast enhancement, filtering to enhance low-density PCO, and variance analysis using a co-occurrence matrix to assess the texture. It provides a semi-objective assessment of PCO and is valid and repeatable (Barman et al 2003; Spalton, 2003). The POComan software determines the percentage area of PCO and assigns a severity score. The results of the POComan system have correlated well with the results of the automated POCO system as well as the results of the clinical evaluation.

These automated image-analysis systems such as the EPCO and AQUA provide an objective PCO assessment and are valuable tools for clinical studies evaluating the development and prevention of PCO. The OSCA is a new system of PCO analysis that incorporates flash detection and removal, registration

and subsequent merger of images for artifact removal, as well as for location-sensitive texture analysis. The system is referred to as the open-access systematic capsule assessment (OSCA) (Aslam et al 2006).

Another system that captures high resolution images is the EAS-1000 system (Scheimpflug videophotography) (Saika et al 2001). However, the IOL material has been seen to significantly influence the scatter light density measurements and thus the intensity of PCO quantified by this system cannot be directly compared with different optic materials. This makes the system less applicable in evaluating PCO (Tanaka et al 2004). The optical coherence tomography (OCT-1) has been used to quantify PCO and to discriminate between different types of PCO (Moreno-Montanes et al 2005). PCO evaluation with OCT is based on peak intensity (PI) and posterior capsule thickening (PCT), with PCT indicating the distance between two reflectivity spikes with an approximate axial resolution of 10  $\mu$ m. Ultra high-resolution OCT images using 1.4  $\mu$ m axial x 3.0  $\mu$ m transverse resolutions have corresponded to the histology sections (Linnola et al 2005). Using a wavelength of 800 nm, the anterior and posterior capsules, area of growth of the LECs, ECM production, and IOL can be clearly visualized. The extent of the capsular bag adhesion to the IOL and the amount of PCO can be detected. The improved resolution can make UHR OCT a powerful tool in anterior segment imaging, to evaluate the capacity of IOL materials and models to induce capsular bag adhesion and to determine the area of origin of PCO after cataract surgery.

## 4. Pathogenesis

The development of PCO is a very dynamic process and involves three basic phenomena: proliferation, migration and differentiation of residual LECs.

### 4.1 Proliferation

The proliferation of residual LECs is highest in the 3 to 4 days after surgery (McDonnell et al 1985). The precise reason for the response of LECs, which leads to their proliferation and the subsequent PCO development, is not known. The removal of lens fiber mass during cataract surgery seems to alter the local environment, inducing proliferation of LECs (Rakic et al 1997). Residual cortex may also promote proliferation of PCO. Besides LECs, melanocytes from the iris and



cells released from the blood due to the breakdown of the blood aqueous barrier may also contribute to the initial proliferation of cells (Cobo et al 1984). This inflammation response may be exacerbated by the presence of a foreign material, that is, the IOL. The response of the LECs in the lens capsular bag is executed by the autocrine or paracrine systems (Wormstone 2002). In the autocrine system, the residual LECs themselves secrete various cytokines that control the development of PCO (Wormstone 2001). The evidence of the autocrine system is based on the observation that LECs in culture maintain themselves in a protein-free medium. A variety of cytokines including fibroblast growth factor (FGF), platelets derived growth factor (PDGF), hepatocyte growth factor (HGF), epidermal growth factor (EGF), insulin like growth factor (IGF), transforming growth factor  $\beta$  (TGF $\beta$ ), interleukin 1 and 6, have been shown to regulate the behavior of LECs in-vitro, but little is known about their in-vivo effects that lead to PCO (Wormstone et al 2002). Basic FGF (bFGF) in the aqueous humor of rabbits increases after surgery and stimulates proliferation of LECs (Wallentin et al 1998). TGF concentration in rabbit aqueous humor decreases after surgery and returns to the preoperative level after about 30 days (Wallentin et al 1998). TGF $\beta$  induces epithelial mesenchymal transition (EMT) of LECs and leads to production of extracellular matrix (de Iongh et al 2005). It seems that the initial fall in TGF $\beta$  allows proliferation of LECs due to the action of bFGF and other growth factors (Wormstone 2002; Meacock et al 2000). In children, the higher density of the LECs and greater number of mitotically active cells result in a higher growth potential (Wormstone et al 1997; Pandey et al 1999).

#### 4.2 Migration

The migration of LECs toward the posterior capsule and their subsequent attachment to the posterior capsule are facilitated by various cell attachment molecules present on the LECs. These molecules include various integrin subunits (Nishi et al 1997; Mathew et al 2003), cell adhesion molecules (CAM) (Volk et al 1986) and hyaluronan receptor CD 44 (Saika et al 1998), Gly-Arg-Gly-Asp-Ser-Pro (GRGDSP) RGD peptide inhibited cell attachment, and migration on laminin and fibronectin that have Arg-Gly-Asp (RGD) peptide sequences (Oharazawa et al 2005).

Matrix metalloproteinases (MMPs), which are a group of proteolytic enzymes, are essential for cell migration and cell-mediated contraction following wound healing (Wong et al 2004).

#### 4.3 Differentiation

The LECs have the ability to undergo both normal and abnormal differentiation. The normal pre-planned differentiation of LECs leads to the formation of pearl-like structures in the posterior capsule known as bladder cells (Ernest et al 2003). The bladder cells are quite dynamic, show reorganization and even disappear within a time period (Neumayer et al 2006). They have a homogeneously granular cytoplasm with pyknotic or no nuclei and do not express  $\alpha$ SMA (Kurosaka et al 1996). The LECs of the equatorial zone are believed to have a stronger tendency to form these cells compared with the anterior LECs.

The abnormal differentiation of LECs takes place in a form of EMT. TGF $\beta$  induces the EMT of LECs and FGF promotes the survival of TGF $\beta$ -affected cells (Symonds et al 2006). The EMT of LECs leads to the formation of myofibroblast cells that are positive to  $\alpha$ SMA. The formation of myofibroblast also takes place locally at the cut margin of the anterior capsule (Nishi et al 1997). The appearance of  $\alpha$ SMA gives a retractile property to the cell, causes wrinkling of the posterior capsule, and forms fibrous PCO. The myofibroblasts also secrete various types of ECM proteins such as fibronectin, collagen type I, collagen type III, chondroitin sulphate, dermatan sulphate and keratan sulphate, (Ishibashi et al 1995; Nishi et al 1995) amongst others.

#### 5. Risk factors

Several systemic and ocular associations have been cited for influencing the development of PCO. The review of case records to evaluate the risk factors for PCO has revealed no correlation between PCO and age, gender, or axial length. At the one-year follow-up, diabetic patients had significantly severe PCO after cataract surgery when compared with non-diabetic patients (Ebihara et al 2006). However, amongst the diabetics, the stage of diabetic retinopathy and the systemic status of diabetes did not seem to correlate with the degree of PCO (Hayashi et al 2002). Myopic eyes were postulated to have an increased risk of PCO probably because IOL implantation was deferred in

them. However, a study with IOL implantation in myopic eyes showed no association between degree of myopia to degree of PCO. The incidence of PCO is also high in eyes with uveitis (Rahman and Jones, 2005). In these eyes, hydrophobic acrylic IOLs have been seen to provide a better visual outcome and lower incidence of PCO than silicone, PMMA, or heparin-surface-modified PMMA IOLs (Alio et al 2002). Patients with myotonic dystrophy have required multiple capsulotomies following cataract surgery (Garrott et al 2004). Similarly, patients with retinitis pigmentosa showed a significantly higher incidence and density of PCO (Auffarth et al 1997). In traumatic cataracts, the incidence of PCO is significantly higher and has been quoted to be as high as 92% at the three-year follow-up (Krishnamachary et al 1997).

## 6. Prevention

### 6.1 Surgical techniques

#### 6.1.1. Continuous curvilinear capsulorhexis

In aphakic eyes, the creation of a continuous curvilinear capsulorhexis was found to delay the development of central visual obscuration. In such eyes, the fusion of the edge of the continuous curvilinear capsulorhexis to the posterior capsule forms a Soemmering's ring. This ring provides a closed environment, which restricts the migration of the LECs toward the central posterior capsule. The ring contains residual LECs, residual cortical fibers, and differentiated LECs. Excessive proliferation of residual LECs or migration of LECs across this ring has been reported at longer follow-ups. Because the residual LECs are the main culprits, their thorough removal can prolong the development of a central PCO (Apple et al 1992).

#### 6.1.2. Cortical cleaving hydrodissection

Cortical cleaving hydrodissection causes a cleavage between the lens capsule and the cortex (Fine, 2000). In a study done on cadaver eyes, Peng and coauthors reported that the hydraulic force exerted by cortical cleaving hydrodissection could remove the LECs (Peng et al 2000). Our study has also suggested that if cortical cleaving hydrodissection could be done in multiple quadrants, the time required to aspirate the epinucleus and cortex would be shorter, and the removal complete (Vasavada et al 2002). High-resolution digital retro-illumination images of the posterior capsule in these eyes at 4 years revealed no difference in the

incidence of PCO, but the percentage area of the central posterior capsule affected by PCO was significantly lower in eyes that had multi-quadrant cortical cleaving hydrodissection than in those that did not (Vasavada et al 2006).

#### 6.1.3. Hydrodissection combined with rotation

In an experimental laboratory study of fresh human cadaver eyes, cortical cleaving hydrodissection combined with rotation removed significant quantities of LECs and residual cortical fibers by way of friction (Vasavada et al 2006). The fact that loose LECs were found in the fluid collected from capsular bag confirms that these two procedures effectively scrap the LECs that otherwise remain attached to the capsule (Johar et al).

#### 6.1.4. Cortical clean-up

Bimanual irrigation and aspiration for cortical clean-up facilitates access to the deep fornices of the capsular bag, especially in the sub-incisional quadrants (Vasavada et al 2006; Vasavada et al 2006). The thorough removal of residual cortical fibers reduces the number of mitotically active cells that have the potential to proliferate and migrate across the central visual axis (Peng et al 2000).

#### 6.1.5. In-the-bag IOL fixation

In-the-bag fixation of the optic and the haptic is required to consistently reduce the incidence of central PCO. Tan and associates noticed an increased incidence of fibrosis type PCO in cases of ciliary sulcus fixation (Tan et al 1993). In-the-bag fixation is facilitated by creating a continuous curvilinear capsulorhexis. It functions primarily to enhance the IOL optic barrier effect (Peng et al 2000). In-the-bag fixation, along with other measures related to surgical techniques and IOL choice, have reduced the incidence of Nd:YAG laser posterior capsulotomy to 0.9% with Alcon AcrySof IOL (Schmidbauer et al 2002).

#### 6.1.6. Anterior capsule overlap of IOL optic

When the size of the anterior capsulorhexis is larger than that of the IOL, there is an increased incidence of fibrous PCO since the anterior epithelium remains opposed to the posterior capsule. It is believed that with a capsulorhexis smaller than the IOL optic, the adhesion between the anterior capsule and the IOL optic keeps the anterior lens epithelium away from the

posterior capsule. This would decrease the incidence of migration of the anterior LECs behind the IOL optic (Tan et al 1993). On the other hand, it has also been postulated that a capsulorhexis larger than the IOL optic allows adhesion of the anterior and posterior capsules, forming a Soemmering's ring. This could contain the cells and regenerative cortical matter, preventing LEC migration onto the visual axis (Apple et al 2000 ; Trivedi et al 2002). The size of this continuous capsulorhexis opening has not shown any correlation with the degree or severity of PCO (Hayashi et al 2004).

There are several probable mechanisms of anterior capsule overlap over the IOL optic that help in delaying development of central PCO, including the "shrink wrap" effect (Apple et al 2000), the concept of the barrier effect of an IOL optic edge (Schmidbauer et al 2002), the creation of a discontinuous capsular bend by an IOL with a sharp optic edge (Nishi et al 2000), and the bioactivity based Sandwich theory (Linnola et al 1997).

Different IOL materials show different PCO rates due to the variations in the overlap of the anterior capsule with the IOL optic (Meacock et al 2001; Vasavada et al 2004). The total cover of the IOL optic remains an important factor, especially in eyes implanted with PMMA IOLs (Meacock et al 2001) and those with silicone IOLs (Daynes et al 2002). However, in the AcrySof IOL implantation, the size of the rhexis may not be a crucial factor in delaying the development of a central PCO (Vasavada et al 2004). Capsular tension rings have shown to reduce the formation of capsular opacification (Nishi et al 2001).

#### 6.1.7. Buttonholing of PC.

The potential of primary posterior continuous curvilinear capsulorhexis (PCCC) to prevent PCO 2 years after surgery has shown encouraging results (Georgopoulos et al 2003). Posterior optic buttonholing through a PCCC has also shown to preclude lens epithelial cells from accessing the retrolental space. The sandwiched posterior capsule blocks optic contact and thus, prevents fibrosis of the anterior capsule (Menapace et al 2006). This technique is skill-dependent and could be potentially demanding in eyes with the risk of posterior segment complications.

#### 6.1.8. Bag-in-the-lens implantation

The culture of postmortem capsular bags and in-vivo animal models have used a bag-in-the-lens implantation technique to limit LEC proliferation. In this technique, anterior and posterior capsule flaps of similar sizes are inserted in a flange of the IOL. The LEC proliferation is restricted within the space of the remaining lens bag and does not approach the visual axis (Tassignon et al 2002). However, it is cautioned that this prevents PCO only if the anterior and posterior capsules have been secured properly in the peripheral groove of the IOL (De Groot et al 2005).

#### 6.1.9. Polishing (scraping) the anterior capsule

The overlap of the anterior capsule rim over the IOL optic leads to the EMT of the LECs, resulting in ACO. Several authors have evaluated the role of polishing the anterior capsule on the development of PCO when using silicone IOLs. Polishing of the anterior capsule has been effective in reducing fibrotic opacification but ineffective in reducing regenerative opacification (Menapace et al 2005). In eyes with a sharp-edged silicone, anterior capsule polishing caused no significant difference in fibrotic PCO (Sacu et al 2004).

### 6.2 IOL design

IOL design, optic size and edge, and its material are important considerations in retarding the development of PCO. Optics with biconvex designs retarded capsular opacification when there was a broad adhesion of the lens optic to the posterior capsule (Born et al 1990). A 6 mm IOL optic diameter was associated with less PCO than a 5.5 mm IOL optic (Meacock et al 2001).

Nishi et al suggest that IOLs with a sharp optic edge create an acute bend in the posterior capsule and this helps to a large extent in retarding the development of central PCO (Nishi et al 1998). The sharp capsule bend appears to represent a physical hindrance, which may induce contact inhibition of cell movement (Prosdocimo et al 2003). A histopathological examination reveals that IOLs with a rounded edge show a capsular bend and complex folds in the posterior capsule that are not as sharp as that of a square-edged optic (Nishi et al 1998). Our clinical trials have also shown that the square-edged AcrySof IOLs led to significantly lower levels of PCO than the square-edged PMMA IOL at six months and one-year post operatively (Praveen et al 2008 in peer

review). Based on the mathematical model, it has been predicted that IOLs with square-edged optic profiles exert higher pressure on the posterior capsule than IOLs with round-edged optic profiles. The higher pressure may form a physical barrier to prevent the migration of LECs onto the posterior capsule (Boyce et al 2002).

In addition to the optic edge, it has been observed that the haptic angulation also reduces the incidence of PCO by inducing a pressure gradient over the posterior capsule (Ayaki et al 2003).

### 6.3 IOL material

It has been experimentally shown that in addition to the sharp rectangular optic edge, an IOL with an adhesive material promotes capsular adhesion. In-vitro experiments have shown that a sharp discontinuous bend in the lens capsule is unlikely to be solely responsible for the observed reduction in posterior capsule opacification associated with the use of square-edged IOLs (Bhermi et al 2002). In addition, the speed of the capsule bending depends on the material of the IOL (Nishi et al 1998). AcrySof material has a "tacky surface" with adhesive properties and experimental studies have revealed that collagen type IV, fibronectin and laminin adhered stronger and faster to the acrylate IOL (Linnola et al 2000). Sacu et al (2005) noted that the capsule-IOL contact on optical coherence tomography was on the 10<sup>th</sup> day with a single piece AcrySof, on the 13<sup>th</sup> day with a three-piece AcrySof, and on the 15<sup>th</sup> day with a three-piece silicone IOL.

The incidence of PCO is the least following implantation of the AcrySof IOL (Schmidbauer et al 2002) (Figure 4). A laboratory study has shown that the AcrySof IOL has a relatively low propensity to induce cellular proliferation in the capsular bag and has less Sommering's ring formation than other IOL designs (Apple et al 2001).

### 6.4 Chemical agents

A number of pharmacological agents have been proposed to prevent PCO, and most of these have been tested in-vitro. These are anti-inflammatory, anti-proliferative, anti-adherence, anti-migrative, and anti-transdifferentiating in nature.

6.4.1. Anti-inflammatory and immuno-modulating agents  
Anti-inflammatory and immuno-modulating drugs reduce the inflammatory response and secretion of

cytokines, and this subsequently leads to a reduction in the proliferation of LECs. These drugs are indomethacin (Nishi et al 1995), diclofenac sodium (Nishi et al 1995), and cyclosporin A (Cortina et al 1997). Topical instillation of diclofenac in the immediate postoperative period did not seem to influence the formation of PCO (Zaczek et al 2004).

#### 6.4.2. Anti-proliferative agents

Anti-proliferative agents reduce the rate of proliferation of LECs and prevent the entry of LECs into the process, which leads to the development of PCO. The various anti-proliferative agents tested in-vitro are 5-fluorouracil, mitomycin C (Inan et al 2001), duanomycin (Power et al 1994), FGF receptor-1 antagonist SU5402 (Wormstone et al 2001), octreotide (Lois et al 2005), colchicines (Legler UF et al 1993), and doxorubicin (McDonnell et al 1988). The sustained release of mitomycin C suspended in sodium hyaluronate has shown to reduce PCO in rabbits (Chung et al 2000). The proteasome inhibitor also leads to reduced proliferation of LECs in the in-vitro condition (Awasthi and Wagner. 2006). Application of electric fields has been shown to decrease the entry of cells into the S-phase from the G1-phase by decreasing the G1-specific cell cycle protein cyclin E and increasing the cyclin-Cdk complex inhibitor p27kip1 (Bretton et al 2002).

#### 6.4.3. Anti-adhering and anti-migratory compounds

Anti-adhering and anti-migrative compounds do not allow the attachment of LECs to the posterior capsule and thus prevent the migration of LECs to the posterior capsule. The various anti-migrating and anti-adherence substances tested are ilomastat (a matrix metalloproteinase inhibitor), naphthyl urea suramin (Rieck et al 2004), salmosin (a disintegrin) (Kim et al 2002), mibefradil (Ca-channel inhibitor) (Nebe et al 2004), RGD peptide (Oharazawa et al 2005), EDTA (Nishi et al 1996), and coating an acrylic IOL surface with MPC polymer (Okajima et al 2006). They reduce proliferation of LECs by reducing prostaglandin E2 production by LECs.

#### 6.4.4. Cell death inducing agents

Anti-transdifferentiating agent minoxidil (lysyl hydroxylase inhibitor) (Ishida et al 2001) can inhibit metaplasia and proliferation of LECs. Inducing apoptosis of the residual LECs has been tried in



experimental studies. The agents include bacteriochlorin A (Van Tenten et al 2002), fas ligand activating monoclonal antibody (Nishi O et al 2001), ricin A (Meacock et al 2000), ricin A conjugated to an anti-LEC antibody (Tarsio et al 1997), and 1% preservative free lidocaine (Vargas et al 2003). Adenovirus mediated Bax, procaspase 3 gene transfer, and distilled water have led to a reduction of PCO in the rabbit model (Malecaze et al 2006). Indocyanine green and trypan blue have shown to kill LECs in a dose-dependent manner due to their photosensitization (Melendez et al 2005; Nanavaty et al 2006).

#### 6.4.5. Delivery of drugs

The drugs can be delivered within the capsular bag to the residual LECs by coating the IOL, modifying the irrigating medium, and during cortical cleaving hydrodissection, the majority of which are still in the experimental phase.

#### **Coating the IOL**

The delivery via the IOL could provide a more controlled means of drug delivery that can concentrate an agent at the site of the potentially proliferating cells more efficiently. A heparin-coated PMMA IOL reduces inflammation and the incidence of PCO (Koraszewska-Matuszewska et al 2003). A thapsigargin (endoplasmic reticulum based Ca-ATPase inhibitor) coated IOL is also shown to reduce PCO (Duncan et al 1997). An indomethacin-coated IOL also reduces mitosis (Nishi et al 1995). Behar-Cohen has reported the effects of an FGF-saporin complex bound to a heparin surface modified IOL in rabbits (Behar-Cohen et al 1995). A hydrophobic soft acrylic IOL coated with MPC polymer has been seen to suppress adhesion and proliferation of LECs (Okajima et al 2006).

#### **Irradiation and photodynamic therapy**

Active oxygen processing by ultraviolet/ozone irradiation and argon plasma irradiation on the surface of acrylic IOLs have been effective in preventing secondary PCO in 8-week-old albino rabbits (Xia et al 1994). Photodynamic therapy with bacteriochlorin A (BCA) has induced lens epithelial cell death and greatly reduced the formation of a Soemmering's ring (Koh et al 2002). However, the corneas of the PDT-treated animals were opaque and swollen and had lost their endothelial lining (Van Tenten et al 2002).

#### **Irrigating solution**

Low molecular weight heparin added to the irrigating fluid during cataract surgery has resulted in less fibrin and pigment deposits on the lens (Xia et al 1994).

#### **Cortical cleaving hydro-dissection**

In-vitro experiments showed that hydrodissection with 1% preservative-free lidocaine may help diminish the number of live LECs in the anterior capsule by facilitating cortical clean-up, by loosening the desmosomal area of cell-cell adhesion with decreased cellular adherence, or by a direct toxic effect (Vargas et al 2003).

Despite these in-vitro and in-vivo efforts, these agents are yet not implicated for use in humans. With these drugs, there is a possibility of improper delivery or diffusion of these agents outside the capsular bag and this may adversely affect other surrounding tissues of the eye. The tissue most susceptible to these effects is the corneal endothelium (Van Tenten et al 2002). Other complications observed in the rabbit model are retinal necrosis and anterior chamber reaction (Behar-Cohen et al 1995). Therefore, the targeted delivery of these agents inside the capsular bag is important. Recently, a device which can selectively apply certain agents to the residual LECs without harming other tissues of the eye has been created (Maloof et al 2003).

### **7. Treatment**

Central PCO obscuring the visual axis can be treated with either surgical intervention such as posterior capsule scraping or with a non-surgical neodymium:YAG (Nd:YAG) laser capsulotomy. Figures 3A and 3B show an eye before and after Nd:YAG posterior capsulotomy. The latter method has received wide acceptance. Performing Nd:YAG capsulotomy of an appropriate size and at an appropriate site is challenging. A capsulotomy that is larger than the pupil diameter under scotopic conditions may prevent disturbances of vision such as monocular diplopia (Sundelin et al 2005). The clinical complications from Nd:YAG laser capsulotomy include a rise in intraocular pressure, glaucoma, cystoid macular edema, and retinal detachment (Billotte et al 2004). Therefore, it is important that strategies developed to retard and prevent PCO contribute to preserving visual acuity in patients over their lifetimes.

Figure 3: An eye with posterior capsule opacification before (A) and after Nd:YAG posterior capsulotomy (B).

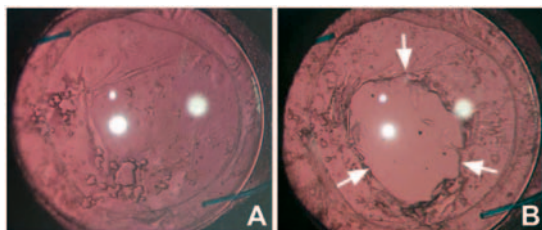


Figure 4: An eye at the 4 years follow-up with AcrySof IOL implanted in the bag. There is no central PCO.



## 8. PCO in children

Children display a significantly higher incidence of postoperative PCO and a higher Nd:YAG laser posterior capsulotomy rate (Dholakia et al 2005). In children, the re-operation rate following congenital cataract surgery is significantly higher than in age-related cataracts and especially higher with an intact posterior capsule (Tuncer et al 2005). An in-vitro experiment of human capsules with a central hole of 5 mm (PCCC) placed in a culture showed that even in the absence of the posterior capsule, their natural substrate, LECs that remain after cataract extraction have the potential to proliferate and form a monolayer of LECs on a basal lamina of vitreous origin. These LECs are able to close the posterior capsulorrhexis partially or totally in approximately one-third of cases (De Groot et al 2003).

### 8.1 Surgical prevention

In children, multi-quadrant cortical cleaving hydrodissection ensures thorough, complete, easy, and rapid removal of the nucleus in eyes with an intact capsule (Vasavada et al 2003). Primary posterior

continuous curvilinear capsulorhexis may delay the onset of central PCO and primary anterior vitrectomy may be necessary to prevent or eliminate the onset of central PCO (Vasavada et al 2003; Vasavada et al 2001). In pediatric eyes, AcrySof IOL implantation with appropriate management of the posterior capsule helps in retarding the development of central PCO maintaining a clear visual axis in a majority of the cases (Vasavada et al 2003; Vasavada et al 2006). The PCO profile following AcrySof IOL implantation was different from that of PMMA IOL implantation. With PMMA, the opacification sets in rapidly in the first few weeks. The type of PCO seen with PMMA is fibrous. It is fierce, not only in its appearance but also in its impact on the development of amblyopia. In contrast, following AcrySof implantation, the type of PCO is predominantly proliferative. PCO sets in at a later stage, typically at 14-16 months. Visual obstruction produced with AcrySof IOL is less severe than with PMMA IOL and is therefore less amblyogenic (Vasavada et al 2003). Grieshaber et al have suggested anterior and posterior vertical capsulotomy, with optic entrapment of the intraocular lens to avoid vitrectomy in infants under the age of 5 years. The fusion of the anterior and posterior capsules in front of the IOL limits the proliferation and migration of Elschnig pearls (Grieshaber et al 2005).

### 8.2 Treatment

In younger children, visual axis obscuration due to PCO can be treated with pars plana vitrectomy and membranectomy. In older children and adults, an Nd:Yag posterior capsulotomy is an acceptable option for the management of PCO (Stager et al 2006). Retinal detachment after Nd:YAG capsulotomy for PCO is rare in eyes that had previous uneventful phacoemulsification and PC IOL implantation (Jahn et al 2003). A second Nd:YAG posterior capsulotomy that could be required can also be carried out. Recently, a transconjunctival sutureless vitrectomy system has been employed (Lam et al 2005).

### Conclusion

In conclusion, capsular opacification, in particular PCO, still remains a physiological complication of an uneventful cataract surgery. The quest for its eradication goes on. Different patient-related factors, ocular and systemic conditions, surgical techniques to remove the residual LECs, and residual cortical fibers

and adjuncts influence the development of PCO. The use of intraocular lenses with different biomaterials and edge designs can influence the progression of visually significant PCO. At present, meticulous use of surgical techniques and appropriate intraocular lens remain the mainstay for retarding the development of post-operative capsular opacification in humans.

## References

- Alio JL, Chipont E, BenEzra D, Fakhry MA (2002). International Ocular Inflammation Society, Study Group of Uveitic Cataract Surgery. Comparative performance of intraocular lenses in eyes with cataract and uveitis. *J Cataract Refract Surg* 28(12):2096
- Apple DJ, Solomon KD, Tetz MR, Assia EI et al (1992). Posterior capsule opacification. *Surv Ophthalmol* 37(2):73 Review.
- Apple DJ, Ram J, Foster A, et al (2000). Posterior capsule opacification (secondary cataract). *Surv Ophthalmol* 45(Suppl):S100.
- Apple DJ, Peng Q, Visessook N et al (2001). Eradication of posterior capsule opacification. Documentation of a marked decrease in ND:YAG laser posterior capsulotomy rates noted in an analysis of 5416 pseudophakic human eyes obtained postmortem. *Ophthalmology* 106:505.
- Aslam TM, Patton N, Graham J (2005). A freely accessible, evidence based, objective system of analysis of posterior capsular opacification; evidence for its validity and reliability. *BMC Ophthalmol* 7:9.
- Aslam TM, Patton N, Rose C (2006). OSCA: A comprehensive open-access system of analysis of posterior capsular opacification. *BMC Ophthalmol* 28; 6(1):30.
- Auffarth GU, Brezin A, Caporossi A, Lafuma A, Mendicute J, Berdeaux G, Smith AF (2004). European PCO Study Group. Comparison of Nd : YAG capsulotomy rates following phacoemulsification with implantation of PMMA, silicone, or acrylic intra-ocular lenses in four European countries. *Ophthalmic Epidemiol* 11(4):319-29.
- Auffarth GU, Nimsgern C, Tetz MR, Krastel H et al (1997). [Increased cataract rate and characteristics of Nd:YAG laser capsulotomy in retinitis pigmentosa. *Ophthalmologie* 94(11):791.
- Awasthi N, Wagner BJ (2006). Suppression of human lens epithelial cell proliferation by proteasome inhibition, a potential defense against posterior capsular opacification. *Invest Ophthalmol Vis Sci* 47:4482.
- Ayaki M, Ishida Y, Nishimura E, Yaguchi S (2003). Lens epithelial cell migration between posterior capsule and intraocular lens with variously finished posterior optic edge and two haptic angulations. *Ophthalmic Res* 35(5):261.
- Barman SA, Hollick EJ, Boyce JF, Spalton DJ, Uyyanonvara B, Sanguinetti G, Meacock W (2000). Quantification of posterior capsular opacification in digital images after cataract surgery. *Invest Ophthalmol Vis Sci* 41(12):3882-92.
- Baumeister M, Neidhardt B, Strobel J, Kohnen T (2005). Tilt and decentration of three-piece foldable high-refractive silicone and hydrophobic acrylic intraocular lenses with 6-mm optics in an intra-individual comparison. *Am J Ophthalmol* 140(6):1051.
- Behar-Cohen FF, David T, D'Hermies F, Pouliquen YM et al (1995). In vivo inhibition of lens regrowth by fibroblast growth factor 2-saporin. *Invest Ophthalmol Vis Sci* 36:2434.
- Bhermi GS, Spalton DJ, El-Osta AA, Marshall J (2002). Failure of a discontinuous bend to prevent lens epithelial cell migration in vitro. *J Cataract Refract Surg* 28(7):1256.
- Billotte C, Berdeaux G (2004). Adverse clinical consequences of neodymium:YAG laser treatment of posterior capsule opacification. *J Cataract Refract Surg* 30(10):2064.
- Born CP, Ryan DK (1990). Effect of intraocular lens optic design on posterior capsular opacification. *J Cataract Refract Surg* 16:188.
- Boyce JF, Bhermi GS, Spalton DJ, El-Osta AR (2002). Mathematical modeling of the forces between an intraocular lens and the capsule. *J Cataract Refract Surg* 28(10):1853.
- Bretton RH, Kash RL, Schanzlin DJ (2002). Use of bipolar diathermy to prevent posterior capsule opacification(1). *J Cataract Refract Surg* 28(5):866.
- Buehl W, Sacu S, Findl O (2005). Association between intensity of posterior capsule opacification and visual acuity. *J Cataract Refract Surg* 31(3):543.
- Buehl W, Sacu S, Findl O (2005). Association between intensity of posterior capsule opacification and contrast sensitivity. *Am J Ophthalmol* 140(5):927.



- Buehl W, Findl O, Menapace R, Georgopoulos M, Rainer G, Wirtitsch M, Siegl H, Pinz A (2002). Reproducibility of standardized retroillumination photography for quantification of posterior capsule opacification. *J Cataract Refract Surg* 28(2):265-70.
- Choi J, Park SY, Joo CK (2004). Hepatocyte growth factor induces proliferation of lens epithelial cells through activation of ERK1/2 and JNK/SAPK. *Invest Ophthalmol Vis Sci* 45(8):2696.
- Chung HS, Lim SJ, Kim HB (2000). Effect of mitomycin-C on posterior capsule opacification in rabbit eyes. *J Cataract Refract Surg* 26:1537.
- Cobo LM, Ohsawa E, Chandler D, Arguella R et al (1984). Pathogenesis of capsular opacification after extracapsular cataract extraction. An animal model. *Ophthalmology* 91: 857.
- Cortina P, Gomez-Lechon MJ, Navea A, Menezo JL et al (1997). Diclofenac sodium and cyclosporin A inhibit human lens epithelial cell proliferation in culture. *Graefes Arch Clin Exp Ophthalmol* 35:180.
- Daynes T, Spencer TS, Doan K, et al (2002). Three-year clinical comparison of 3-piece AcrySof and SI-40 silicone intraocular lenses. *J Cataract Refract Surg* 28:1124.
- De Groot V, Tassignon MJ, Vrensen GF (2005). Effect of bag-in-the-lens implantation on posterior capsule opacification in human donor eyes and rabbit eyes. *J Cataract Refract Surg* 31(2):398.
- De Groot V, Vrensen GF, Willekens B, Van Tenten Y et al (2003). In vitro study on the closure of posterior capsulorhexis in the human eye. *Invest Ophthalmol Vis Sci* 44(5):2076.
- De Jong-Hesse Y, Kampmeier J, Lang GK, Lang GE (2005). Effect of extracellular matrix on proliferation and differentiation of porcine lens epithelial cells. *Graefes Arch Clin Exp Ophthalmol* 43(7):695.
- De Jongh RU, Wederell E, Lovicu FJ, McAvoy JW (2005). Transforming growth factor-beta-induced epithelial-mesenchymal transition in the lens: a model for cataract formation. *Cells Tissues Organs* 179(1-2):43.
- Dholakia SA, Vasavada AR (2004). Intraoperative performance and longterm outcome of phacoemulsification in age-related cataract. *Indian J Ophthalmol* 52(4):311.
- Dholakia SA, Vasavada AR, Singh R (2005). Prospective evaluation of phacoemulsification in adults younger than 50 years. *J Cataract Refract Surg* 31(7):1327.
- Duncan G, Wormstone IM, Liu CS, Marcantonio JM et al (1997). Thapsigargin-coated intraocular lenses inhibit human lens cell growth. *Nat Med* 3:1026.
- Ebihara Y, Kato S, Oshika T, Yoshizaki M et al (2006). Posterior capsule opacification after cataract surgery in patients with diabetes mellitus. *J Cataract Refract Surg* 32(7):1184.
- Elgohary MA, Hollick EJ, Bender LE, Heatley CJ et al (2006). Hydrophobic acrylic and plate-haptic silicone intraocular lens implantation in diabetic patients: pilot randomized clinical trial. *J Cataract Refract Surg* 32(7):1188.
- El-Osta AA, Spalton DJ, Marshall J (2003). In vitro model for the study of human posterior capsule opacification. *J Cataract Refract Surg* 29(8):1593.
- Ernest PH (2003). Posterior capsule opacification and neodymium: YAG capsulotomy rates with AcrySof acrylic and PhacoFlex II silicone intraocular lenses. *J Cataract Refract Surg* 29(8):1546.
- Findl O, Buehl W, Menapace R, Georgopoulos M, Rainer G, Siegl H, Kaider A, Pinz A (2003). Comparison of 4 methods for quantifying posterior capsule opacification. *J Cataract Refract Surg* 29(1):106-11.
- Fine IH (2000). Cortical cleaving hydrodissection (letter) *J Cataract Refract Surg* 26:943.
- Garrott HM, Walland MJ, O'Day J (2004). Recurrent posterior capsular opacification and capsulorhexis contracture after cataract surgery in myotonic dystrophy. *Clin Experiment Ophthalmol* 32(6):653.
- Grieshaber MC, Pienaar A, Stegmann R (2005). Posterior vertical capsulotomy with optic entrapment of the intraocular lens in congenital cataracts--prevention of capsule opacification. *J Cataract Refract Surg* 31(5):886.
- Georgopoulos M, Menapace R, Findl O, Petternel V et al (2003). After-cataract in adults with primary posterior capsulorhexis: comparison of hydrogel and silicone intraocular lenses with round edges after 2 years. *J Cataract Refract Surg* 29(5):955.
- Hara T, Azuma N, Chiba K, Ueda Y. (1992). Anterior capsular opacification after endocapsular cataract surgery. *Ophthalmic Surg* 23(2):94.
- Harding, JJ(1991). *Cataract: Biochemistry,*



- Epidemiology and Pharmacology. London: Chapman and Hall.
- Hanson RJ, Rubinstein A, Sarangapani S, Benjamin L et al (2006). Effect of lens epithelial cell aspiration on postoperative capsulorhexis contraction with the use of the AcrySof intraocular lens: randomized clinical trial. *J Cataract Refract Surg* 32(10):1621.
- Hayashi K, Hayashi H, Nakao F, Hayashi F (2002). Posterior capsule opacification after cataract surgery in patients with diabetes mellitus. *Am J Ophthalmol* 134(1):10.
- Hayashi K, Yoshida M, Hayashi H (2006). Posterior capsule opacification in myopic eyes. *J Cataract Refract Surg* 32(4):634
- Hayashi Y, Kato S, Fukushima H, Numaga J et al (2004). Relationship between anterior capsule contraction and posterior capsule opacification after cataract surgery in patients with diabetes mellitus. *J Cataract Refract Surg* 30(7):1517.
- Inan UU, Ozturk F, Kaynak S, Ilker SS et al (2001). Prevention of posterior capsule opacification by retinoic acid and mitomycin. *Graefes Arch Clin Exp Ophthalmol* 239:693.
- Ishibashi T, Araki H, Sugai S, Tawara A et al (1993). Anterior capsule opacification in monkey eyes with posterior chamber intraocular lenses. *Arch Ophthalmol* 111(12):1685.
- Ishibashi T, Araki H, Sugai S, Tawara A et al (1995). Detection of proteoglycans in human posterior capsule opacification. *Ophthalmic Res* 27:208.
- Ishida I, Saika S, Ohnishi Y (2001). Effect of minoxidil on rabbit lens epithelial cell behavior in vitro and in situ. *Graefes Arch Clin Exp Ophthalmol* 239: 770.
- Izak AM, Werner L, Pandey SK, Apple DJ (2004). Pathological evaluation of postmortem human eyes implanted with a new single-piece hydrophobic acrylic lens. *J Cataract Refract Surg*. 30(7):1537.
- Jacob TJ (1987). Human lens epithelial cells in culture: a quantitative evaluation of growth rate and proliferative capacity. *Exp Eye Res*. 45(1):93.
- Jackson H, Garway-Heath D, Rosen P, Bird AC et al (2001). Outcome of cataract surgery in patients with retinitis pigmentosa. *Br J Ophthalmol* 85(8):936.
- Johar K, Vasavada AR, Praveen MR, Nishi O (In peer review). Confirmation of the presence of lens epithelial cells in the anterior chamber post phacoemulsification.
- Jahn CE, Richter J, Jahn AH, Kremer G et al (2003). Pseudophakic retinal detachment after uneventful phacoemulsification and subsequent neodymium: YAG capsulotomy for capsule opacification. *J Cataract Refract Surg* 29(5):925.
- Kim JT, Lee DH, Chung KH, Kang IC et al (2002). Inhibitory effects of salmosin, a disintegrin, on posterior capsular opacification in vitro and in vivo. *Exp Eye Res* 74:585.
- Kimura W, Yamanishi S, Kimura T, Sawada T et al (1998). Measuring the anterior capsule opening after cataract surgery to assess capsule shrinkage. *J Cataract Refract Surg* 24(9):1235.
- Koh HJ, Kang SJ, Lim SJ, Chu YK et al (2002). The effect of photodynamic therapy with rose bengal on posterior capsule opacification in rabbit eyes. *Ophthalmic Res* 34(3):107.
- Koraszevska-Matuszewska B, Samochowiec-Donocik E, Pieczara E, Filipek E (2003). Heparin-surface-modified PMMA intraocular lenses in children in early and late follow-up. *Klin Oczna* 105:273.
- Krishnamachary M, Rath V, Gupta S (1997). Management of traumatic cataract in children. *J Cataract Refract Surg* 23 Suppl 1:681.
- Kurosaka D, Kato K, Nagamoto T (1996). Presence of alpha smooth muscle actin in lens epithelial cells of aphakic rabbit eyes. *Br J Ophthalmol* 80:906.
- Lam DS, Fan DS, Mohamed S, Yu CB et al (2005). 25-gauge transconjunctival sutureless vitrectomy system in the surgical management of children with posterior capsular opacification. *Clin Experiment Ophthalmol* 33(5):495.
- Lois N, Taylor J, McKinnon AD, Smith GC et al (2005). Effect of TGF-beta2 and anti-TGF-beta2 antibody in a new in vivo rodent model of posterior capsule opacification. *Invest Ophthalmol Vis Sci* 46:4260.
- Legler UF, Apple DJ, Assia EI, Bluestein EC et al (1993). Inhibition of posterior capsule opacification: the effect of colchicine in a sustained drug delivery system. *J Cataract Refract Surg* 19:462.
- Linnola RJ, Findl O, Hermann B, Sattmann H et al (2005). Intraocular lens-capsular bag imaging with ultrahigh-resolution optical coherence tomography Pseudophakic human autopsy eyes. *J Cataract Refract Surg* 31(4):818.
- Linnola RJ (1997). Sandwich theory: bioactivity-based explanation for posterior capsule opacification. *J Cataract Refract Surg* 23:1539.

- Linnola RJ, Werner L, Pandey SK, et al (2000). Adhesion of fibronectin, vitronectin, laminin, and collagen type IV to intraocular lens materials in pseudophakic human autopsy eyes. Part-1: histological sections. *J Cataract Refract Surg* 26:1792.
- Mathew MR, McLean SM, Murray SB, Bennett HG et al (2003). Expression of CD18, CD49b, CD49c and CD49e on lens anterior capsules in human cataracts. *Eye* 17:473.
- McDonnell PJ, Krause W, Glaser BM (1988). In vitro inhibition of lens epithelial cell proliferation and migration. *Ophthalmic Surg* 19 25.
- McDonnell PJ, Patel A, Green WR (1985). Comparison of intracapsular and extracapsular cataract surgery. Histopathologic study of eyes obtained postmortem. *Ophthalmology* 92: 1208.
- Malecaze F, Decha A, Serre B, Penary M et al (2006). Prevention of posterior capsule opacification by the induction of therapeutic apoptosis of residual lens cells. *Gene Ther* 13:440.
- Matsushima H, Iwamoto H, Mukai K, Obara Y (2006). Active oxygen processing for acrylic intraocular lenses to prevent posterior capsule opacification. *J Cataract Refract Surg* 32(6):1035.
- Maloof A, Neilson G, Milverton EJ, Pandey SK (2003). Selective and specific targeting of lens epithelial cells during cataract surgery using sealed-capsule irrigation. *J Cataract Refract Surg* 29(8):1566.
- Meacock WR, Spalton DJ, Boyce J, Marshall J (2003). The effect of posterior capsule opacification on visual function. *Invest Ophthalmol Vis Sci* 44(11):4665.
- Meacock WR, Spalton DJ, Hollick EJ, et al (2001). The effect of polymethylmethacrylate and AcrySof intraocular lenses on the posterior capsule in patients with a large capsulorhexis. *Jpn J Ophthalmol* 45:348.
- Meacock WR, Spalton DJ, Boyce JF, Jose RM (2001). Effect of optic size on posterior capsule opacification: 5.5 mm versus 6.0 mm AcrySof intraocular lenses. *J Cataract Refract Surg* 27(8):1194.
- Meacock WR, Spalton DJ, Stanford MR (2000). Role of cytokines in the pathogenesis of posterior capsule opacification. *Br J Ophthalmol* 84:332.
- Meacock WR, Spalton DJ, Hollick EJ, Boyce JF et al (2000). Double-masked prospective ocular safety study of a lens epithelial cell antibody to prevent posterior capsule opacification. *J Cataract Refract Surg* 26:716.
- Mansfield KJ, Cerra A, Chamberlain CG (2004). FGF-2 counteracts loss of TGFbeta affected cells from rat lens explants: implications for PCO (after cataract). *Mol Vis* 22; 10:521.
- McCarty CA, Taylor HR (2002). A review of the epidemiologic evidence linking ultraviolet radiation and cataracts. *Dev Ophthalmol* 35:21.
- McLean SM, Mathew MR, Kelly JB, Murray SB et al (2005). Detection of integrins in human cataract lens epithelial cells and two mammalian lens epithelial cell lines. *Br J Ophthalmol* 89(11):1506.
- Menapace R, Wirtitsch M, Findl O, Buehl W et al (2005). Effect of anterior capsule polishing on posterior capsule opacification and neodymium: YAG capsulotomy rates: three-year randomized trial. *J Cataract Refract Surg* Nov; 31(11):2067.
- Menapace R (2006). Routine posterior optic buttonholing for eradication of posterior capsule opacification in adults: report of 500 consecutive cases. *J Cataract Refract Surg* 32(6):929.
- Melendez RF, Kumar N, Maswadi SM, Zaslow K et al (2005). Photodynamic actions of indocyanine green and trypan blue on human lens epithelial cells in vitro. *Am J Ophthalmol* 140(1):132.
- Moreno-Montanes J, Alvarez A, Maldonado MJ (2005). Objective quantification of posterior capsule opacification after cataract surgery, with optical coherence tomography. *Invest Ophthalmol Vis Sci* 46(11):3999.
- Nanavaty MA, Johar K, Sivasankaran MA, Vasavada AR, et al (2006). Effect of trypan blue staining on the density and viability of lens epithelial cells in white cataract. *J Cataract Refract Surg* 32:1483.
- Nebe B, Kunz F, Peters A, Rychly J et al (2004). Induction of apoptosis by the calcium antagonist mibefradil correlates with depolarization of the membrane potential and decreased integrin expression in human lens epithelial cells. *Graefes Arch Clin Exp Ophthalmol* 242:597.
- Nishi O, Nishi K, Mano C, Ichihara M et al (1997). Inhibition of migrating lens epithelial cells by blocking the adhesion molecule integrin: a preliminary report. *J Cataract Refract Surg* 23:860.
- Nishi O, Nishi K, Wickstrom K (2000). Preventing lens epithelial cell migration using intraocular lenses with

- sharp rectangular edges. *J Cataract Refract Surg* 26:1543.
- Nishi O, Nishi K, Menapace R, Akura J (2001). Capsular bending ring to prevent posterior capsule opacification: 2 year follow-up. *J Cataract Refract Surg*. 27(9):1359.
- Nishi O, Nishi K, Akaishi T, Shirasawa E (1997). Detection of cell adhesion molecules in lens epithelial cells of human cataracts. *Invest Ophthalmol Vis Sci* 38: 579.
- Nishi O, Nishi K, Fujiwara T, Shirasawa E (1995). Types of collagen synthesised by the lens epithelial cells of human cataracts. *Br J Ophthalmol* 79:939.
- Nishi O, Nishi K, Sakanishi K (1998). Inhibition of migrating lens epithelial cells at the capsular bend created by the rectangular optic edge of a posterior chamber intraocular lens. *Ophthalmic Surg Lasers* 29:587-94
- Nishi O, Nishi K, Fujiwara T, Shirasawa E (1995). Effects of diclofenac sodium and indomethacin on proliferation and collagen synthesis of lens epithelial cells in vitro. *J Cataract Refract Surg* 21: 461.
- Nishi O, Nishi K, Saitoh I, Sakanishi K (1996). Inhibition of migrating lens epithelial cells by sustained release of ethylenediaminetetraacetic acid. *J Cataract Refract Surg* 22 Suppl 1:863.
- Nishi O, Nishi K, Wada K, Ohmoto Y et al (2001). Inhibition of lens epithelial cells by Fas-specific antibody activating Fas-Fas ligand system. *Curr Eye Res* 23:192.
- Nishi O, Nishi K, Yamada Y, Mizumoto Y (1995). Effect of indomethacin-coated posterior chamber intraocular lenses on postoperative inflammation and posterior capsule opacification. *J Cataract Refract Surg* 21:574.
- Neumayer T, Findl O, Buehl W, Georgopoulos M (2006). Daily changes in the morphology of Elschnig pearls. *Am J Ophthalmol* 141(3):517-523.
- Obstbaum SA (1998). The anterior capsulotomy revisited. *J Cataract Refract Surg* 24(2):143.
- Oharazawa H, Ibaraki N, Ohara K, Reddy VN (2005). Inhibitory effects of Arg-Gly-Asp (RGD) peptide on cell attachment and migration in a human lens epithelial cell line. *Ophthalmic Res* 37(4):191.
- Okajima Y, Saika S, Sawa M (2006). Effect of surface coating an acrylic intraocular lens with poly(2-methacryloyloxyethyl phosphorylcholine) polymer on lens epithelial cell line behavior. *J Cataract Refract Surg* 32(4):666.
- Pandey SK, Ram J, Werner L, Brar GS et al (1999). Visual results and postoperative complications of capsular bag and ciliary sulcus fixation of posterior chamber intraocular lenses in children with traumatic cataracts. *J Cataract Refract Surg* 25:1576.
- Peng Q, Visessook N, Apple DJ et al (2000). Surgical prevention of posterior capsule opacification. Part-3: intraocular lens optic barrier effect as a second line of defense. *J Cataract Refract Surg* 26:198.
- Peng Q, Apple DJ, Visessook N, et al (2000). Surgical prevention of posterior capsule opacification. Part II: enhancement of cortical cleanup by focusing on hydrodissection. *J Cataract Refract Surg* 26:188.
- Power WJ, Neylan D, Collum LM (1994). Daunomycin as an inhibitor of human lens epithelial cell proliferation in culture. *J Cataract Refract Surg* 20:287.
- Praveen MR, Shah AR, Vasavada AR, Spalton DJ (2008). Effect of a square edged acrylic and polymethylmethacrylate intraocular lens on the development of posterior capsule opacification after extracapsular cataract extraction. *J Cataract and Refract Surg*.
- Prosdocimo G, Tassinari G, Sala M, Di Biase A et al (2003). Posterior capsule opacification after phacoemulsification: silicone CeeOn Edge versus acrylic AcrySof intraocular lens. *J Cataract Refract Surg* 29(8):1551.
- Rakic JM, Galand A, Vrensen GF (1997). Separation of fibres from the capsule enhances mitotic activity of human lens epithelium. *Exp Eye Res* 64: 67.
- Rahman I, Jones NP (2005). Long-term results of cataract extraction with intraocular lens implantation in patients with uveitis. *Eye* 19(2):191.
- Rieck PW, Kriegsch J, Jaeckel C, Hartmann C (2004). [Effect of suramin on proliferation and migration of lens epithelial cells in vitro] *Ophthalmologie* 101:73.
- Spalton DJ (2003). Methods of quantifying posterior capsule opacification. *J Cataract Refract Surg* 29(7):1247.
- Saika S, Miyamoto T, Ishida I, Tanaka T et al (2001). Comparison of Scheimpflug images of posterior capsule opacification and histological findings in rabbits and humans. *J Cataract Refract Surg*

- 27(7):1088.
- Sacu S, Findl O, Linnola RJ (2005). Optical coherence tomography assessment of capsule closure after cataract surgery. *J Cataract Refract Surg* 31:330.
- Sacu S, Menapace R, Wirtitsch M, Buehl W et al (2004). Effect of anterior capsule polishing on fibrotic capsule opacification: three-year results. *J Cataract Refract Surg* 30:2322.
- Sacu S, Menapace R, Buehl W, Rainer G F et al (2004). Effect of intraocular lens optic edge design and material on fibrotic capsule opacification and capsulorhexis contraction. *J Cataract Refract Surg* 30(9):1875.
- Saika S, Kawashima Y, Miyamoto T, Okada Y et al (1998). Immunolocalization of hyaluronan and CD44 in quiescent and proliferating human lens epithelial cells. *J Cataract Refract Surg* 24:1266.
- Saika S, Miyamoto T, Ohnishi Y (2003). Histology of anterior capsule opacification with a polyHEMA/HOHEXMA hydrophilic hydrogel intraocular lens compared to poly(methyl methacrylate), silicone, and acrylic lenses. *J Cataract Refract Surg* 29(6):1198.
- Schmidbauer JM, Vargas LG, Apple DJ, Escobar-Gomez M et al (2002). Valuation of neodymium:yttrium-aluminum-garnet capsulotomies in eyes implanted with AcrySof intraocular lenses. *Ophthalmology* 109 (8):1421.
- Shirai K, Saika S, Okada Y, Oda S et al (2004). Histology and immunohistochemistry of fibrous posterior capsule opacification in an infant. *J Cataract Refract Surg* 30:523.
- Spencer TS, Mamalis N, Lane SS (2002). Interlenticular opacification of piggyback acrylic intraocular lenses. *J Cataract Refract Surg* 28(7):1287.
- Stager DR Jr, Wang X, Weakley DR Jr, Felius J (2006). The effectiveness of Nd:YAG laser capsulotomy for the treatment of posterior capsule opacification in children with acrylic intraocular lenses. *J AAPOS* 10(2):159.
- Sundelin K, Lundstrom M, Stenevi U (2005). Self-assessed visual function for patients with posterior capsule opacification before and after capsulotomy. *Acta Ophthalmol Scand* 83(6):729.
- Symonds JG, Lovicu FJ, Chamberlain CG (2006). Posterior capsule opacification-like changes in rat lens explants cultured with TGFbeta and FGF: effects of cell coverage and regional differences. *Exp Eye Res* 82(4):693.
- Tanaka Y, Kato S, Miyata K, Honbo M et al (2004). Limitation of Scheimpflug videophotography system in quantifying posterior capsule opacification after intraocular lens implantation. *Am J Ophthalmol* 137:732.
- Tan DT, Chee SP. Early central posterior capsular fibrosis in sulcus-fixated biconvex intraocular lenses. *J Cataract Refract Surg* 1993 Jul; 19(4):471.
- Trivedi RH, Werner L, Apple DJ et al (2002). Post cataract-intraocular lens (IOL) surgery opacification. *Eye* 16:217.
- Tassignon MJ, De Groot V, Vrensen GF (2002). Bag-in-the-lens implantation of intraocular lenses. *J Cataract Refract Surg* 28(7):1182.
- Tarsio JF, Kelleher PJ, Tarsio M, Emery JM et al (1997). Inhibition of cell proliferation on lens capsules by 4197X-ricin A immunoconjugate. *J Cataract Refract Surg* 23:260.
- Tetz M, Wildeck A (2005). Evaluating and defining the sharpness of intraocular lenses: part 1: Influence of optic design on the growth of the lens epithelial cells in vitro. *J Cataract Refract Surg* 31(11):2172.
- Tuncer S, Gucukoglu A, Gozum N (2005). Cataract extraction and primary hydrophobic acrylic intraocular lens implantation in infants. *J AAPOS* 9(3):250.
- Thompson AM, Sachdev N, Wong T, Riley AF et al (2004). The Auckland Cataract Study: 2 year postoperative assessment of aspects of clinical, visual, corneal topographic and satisfaction outcomes. *Br J Ophthalmol* 88(8):1042.
- Taylor HR, West SK, Rosenthal FS, Munoz B et al (1988). Effect of ultraviolet radiation on cataract formation. *N Engl J Med* 319:1429.
- Van Tenten Y, Schuitmaker HJ, De Groot V, Willekens B et al (2002). A preliminary study on the prevention of posterior capsule opacification by photodynamic therapy with bacteriochlorin A in rabbits. *Ophthalmic Res* 34:113.
- Vasavada AR, Singh R, Apple DJ, et al (2002). A randomized study of the efficacy of hydrodissection-special reference to intraoperative performance. *J Cataract Refract Surg* 28:1623.
- Vasavada AR, Dholakia SA, Raj SM, Singh R (2006). Effect of cortical cleaving hydrodissection on posterior capsule opacification in age-related



- nuclear cataract. *J Cataract Refract Surg* 32(7):1196.
- Vasavada AR, Raj SM, Johar K, Nanavaty MA (2006). Effect of hydrodissection alone and hydrodissection combined with rotation on lens epithelial cells: surgical approach for the prevention of posterior capsule opacification. *J Cataract Refract Surg* 32(1):145.
- Vasavada AR, Raj SM (2004). Anterior capsule relationship of the Acrysof Intraocular Lens optic and posterior capsule opacification. A prospective randomized clinical trial. *Ophthalmology* 111:886.
- Vasavada AR, Trivedi RH (1999). Posterior capsule striae. *J Cataract Refract Surg* 25(11):1527.
- Vasavada AR, Praveen MR, Shah SK, Nihalani BR (2008). Anterior capsule opacification in eyes with and without anterior LEC scrapping. In Peer review
- Vasavada AR, Chauhan H, Shah G (1997). Incidence of posterior capsular plaque in cataract surgery. *J Cataract Refract Surg* 23(5):798.
- Vasavada AR, Nath VC, Trivedi RH (2003). Anterior vitreous face behavior with AcrySof in pediatric cataract surgery. *J AAPOS* 7(6):384.
- Vasavada AR, Trivedi RH, Singh R (2001). Necessity of vitrectomy when optic capture is performed in children older than 5 years. *J Cataract Refract Surg* 27(8):1185.
- Vasavada AR, Nihalani BR (2006). Pediatric cataract surgery. *Curr Opin Ophthalmol* 17(1):54.
- Vetrugno M, Masselli F, Greco G, Sisto D, et al (2007). The influence of posterior capsule opacification on scanning laser polarimetry. *Eye* 21(6):760.
- Volk T, Geiger B (1986). A-CAM: a 135-kD receptor of intercellular adherens junctions. I. Immunoelectron microscopic localization and biochemical studies. *J Cell Biol* 103:1441.
- Vargas LG, Escobar-Gomez M, Apple DJ, Hoddinott DS et al (2003). Pharmacologic prevention of posterior capsule opacification: in vitro effects of preservative -free lidocaine 1% on lens epithelial cells. *J Cataract Refract Surg* 29(8):1585.
- Wormstone IM (2002). Posterior capsule opacification: a cell biological perspective. *Exp Eye Res* 74(3):337.
- Wormstone IM, Del Rio-Tsonis K, McMahon G, Tamiya S et al (2001). FGF: an autocrine regulator of human lens cell growth independent of added stimuli. *Invest Ophthalmol Vis Sci* 42:1305.
- Wallentin N, Wickstrom K, Lundberg C (1998). Effect of cataract surgery on aqueous TGF-beta and lens epithelial cell proliferation. *Invest Ophthalmol Vis Sci* 39:1410.
- Wormstone IM, Liu CS, Rakic JM, Marcantonio JM et al (1997). Human lens epithelial cell proliferation in a protein-free medium. *Invest Ophthalmol Vis Sci* 38: 396.
- Wallentin N, Lundgren B, Holmen JB, Lundberg C (2002). Development of posterior capsule opacification in the rabbit. *Ophthalmic Res* 34(1):14.
- Werner L, Pandey SK, Apple DJ, Escobar-Gomez M et al (2001). Anterior capsule opacification: correlation of pathologic findings with clinical sequelae. *Ophthalmology* 108(9):1675.
- Werner L, Hickman MS, LeBoyer RM, Mamalis N (2005). Experimental evaluation of the Corneal Concept 360 intraocular lens with the Miyake-Apple view. *J Cataract Refract Surg* 31(6):1231.
- Wong TT, Daniels JT, Crowston JG, Khaw PT (2004). MMP inhibition prevents human lens epithelial cell migration and contraction of the lens capsule. *Br J Ophthalmol* 88(7):868.
- Wolken MA, Oetting TA (2001). Linear posterior capsule opacification with the AcrySof intraocular lens. *J Cataract Refract Surg* 27(11):1889.
- Xia XP, Lu DY, Wang LT (1994). A clinical study of inhibition of secondary cataract with heparin [in Chinese]. *J Chung Hua Yen Ko Tsa Chih* 30:405.
- Zaczek A, Laurell CG, Zetterstrom C (2004). Posterior capsule opacification after phacoemulsification in patients with postoperative steroidal and nonsteroidal treatment. *J Cataract Refract Surg* 30:316.