

## Corneal Perforation Secondary to Rosacea Keratitis Managed with Excellent Visual Outcome

Bharat Gurnani<sup>1</sup> , Josephine Christy<sup>1</sup>  , Shivananda Narayana<sup>1</sup>, Kirandeep Kaur<sup>1</sup>, Fredrick Moutappa<sup>1</sup>

<sup>1</sup>Aravind Eye Hospital and Post Graduate Institute of Ophthalmology, Thavalukuppam, Pondicherry, India

### ABSTRACT

**Introduction:** Ocular Rosacea is a poly etiological chronic inflammatory disease with heterogeneous clinical manifestations. It is primarily a dermatologic disease, which often manifests in the eyes affecting eyelids, conjunctiva, and cornea. The leading role in the pathological process belongs to the disruption of regulatory mechanisms in the vascular, immune, and nervous systems. The varied manifestation can be erythematous pustular lesions on the face, chronic blepharitis, meibomian gland dysfunction, evaporative dry eye, peripheral corneal ulceration, corneal scarring, perforation, and neovascularization.

**Case:** We describe a rare case report of a 43-year-old male with progressive ocular manifestations of rosacea keratitis. Slit-lamp biomicroscopic examination revealed squamous blepharitis, telangiectatic vessels with obliterated meibomian glands, circumcorneal congestion, peripheral corneal perforation of 2x2 mm at 4 o'clock, shallow anterior chamber(AC) with positive seidel's in the left eye. Fundoscopy showed serous choroidal detachment(CD). Snellen's Best Corrected Visual Acuity(BCVA) was 20/240 with Intraocular pressure measured was 5 mmhg. The patient was managed with topical loteprednol, moxifloxacin, carboxymethylcellulose medications along with cyanoacrylate glue and bandage contact lens and had excellent visual acuity of 20/20 with a follow-up of 1 year.

**Conclusion:** Ocular rosacea perforation has been reported in chronic cases and may not always require amniotic membrane transplant, patch grafting, or keratoplasty. If managed meticulously with cyanoacrylate glue and BCL can have excellent outcomes. Eye specialists should be alerted that the key to a successful outcome is excellent control of inflammatory activity and differentiating this non-infectious keratitis from other keratitis before commencing treatment.

**Key words:** Bandage contact lens, Cyanoacrylate glue, Ocular rosacea.

Financial Interest : Nil

Received : 12.10.2021

Conflict of Interest : Nil

Accepted : 25.12.2021

#### Corresponding Author

Dr. Josephine Christy  
Aravind Eye Hospital and Post Graduate Institute of Ophthalmology,  
Pondicherry, India.  
E-mail: josyfred@gmail.com



Access this article online

Website: [www.nepjol.info/index.php/NEPJO](http://www.nepjol.info/index.php/NEPJO)

DOI: <https://doi.org/10.3126/nepjoph.v14i1.36454>

Copyright © 2022 Nepal Ophthalmic Society

ISSN: 2072-6805, E-ISSN: 2091-0320



This work is licensed under a Creative Commons Attribution-NonCommercial-NoDerivatives 4.0 International License (CC BY-NC-ND).

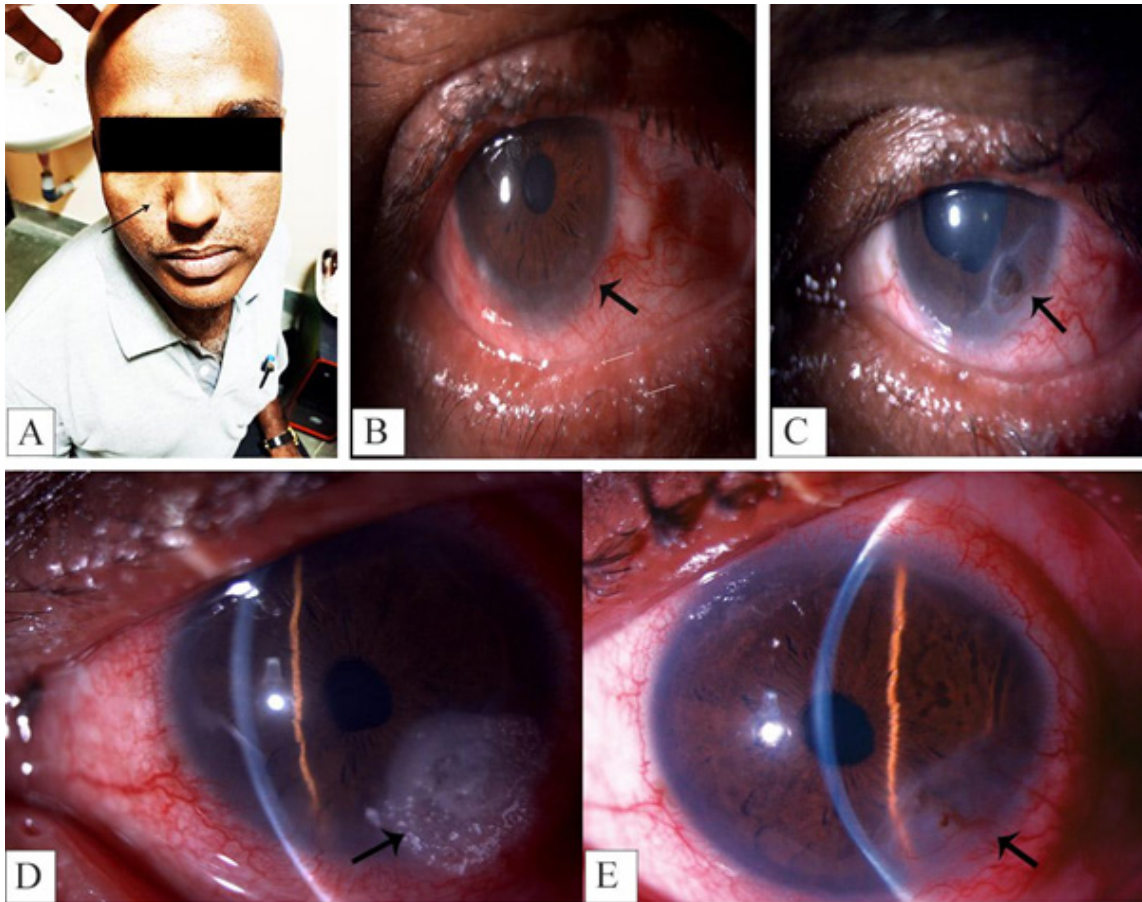
## INTRODUCTION

Ocular Rosacea is a chronic inflammatory acneiform dermatologic condition. The most common clinical manifestation is erythema of the skin on the face and neck. Rosacea can frequently manifest with ocular involvement in up to 6 to 58% of patients. (Trufanov et al., 2019) (Wladis and Adam, 2018) It can also involve face and neck and manifest as malar rash, or papules and pustules. The telltale sign of ocular Rosacea is bilateral chronic blepharitis associated with meibomian gland dysfunction. Meticulous slit lamp evaluation frequently reveals telangiectasia of the eyelid margins, along with inspissated meibomian glands. Patients frequently present with evaporative dry eyes. (Awais et al., 2015) Recurrent chalazia are a common complication in some patients. Patients often complain of burning in the eyes and foreign body sensations. If patients are left untreated or do not comply with the treatment advised, it can often lead to recurrent episodes. This can lead to complications like peripheral corneal ulceration, corneal scarring, perforation, and neovascularization. (Oge' et al., 2015) We report a rare case of a 43-year-old male with progressive ocular sequelae of ocular Rosacea associated with peripheral corneal perforation in the left eye (OS). The patient was medically managed with eyelid hygiene, hot fomentation, tablet doxycycline 100 mg BD for 3 weeks, eye drop combination of 0.5% moxifloxacin with 0.5% loteprednol 4 times/day, eye drops carboxymethylcellulose 4 times/day in OS with cyanoacrylate glue application with bandage

contact lens (BCL) to seal the perforation. The patient had an excellent visual outcome with conservative management.

## CASE

A 43-year-old young male presented with sudden onset painful defective vision in OS for the last 3 days. Past history revealed recurrent episodes of pain and redness in both eyes (OU), along with erythematous reddish papulopustular lesions on the face (**Figure 1a**). The Snellen's best-corrected visual acuity (BCVA) was recorded as 20/20 in the right eye (OD) and 20/240 in OS at the time of presentation. The noncontact tonometry revealed an intraocular pressure of 14 mm Hg and 5 mm Hg in OD and OS, respectively. Anterior segment examination of OD revealed squamous blepharitis, telangiectatic vessels with obliterated meibomian glands, and superficial vascularization from 4 to 7'o clock with marginal infiltrate at 7'o clock rest of the examination was normal (**Figure 1b**). Anterior segment examination of OS revealed squamous blepharitis, telangiectatic vessels with obliterated meibomian glands, circumcorneal congestion, corneal thinning with peripheral paralimbal perforation of 2x2 mm at 4 to 5'o clock associated with iris prolapse, shallow anterior chamber, and seidel's test was positive, the pupil reaction to light was sluggish and irregular, and the lens was clear (**Figure 1c**). Dilated funduscopy with an indirect ophthalmoscope of OD was within normal limits, and OS revealed choroidal folds with serous choroidal detachment.



**Figure 1a:** The gross image of the patient depicting grade 1 acne and facial flushing.

**Figure 1b:** Image of the right eye depicting squamous blepharitis, telangiectatic vessels with obliterated meibomian glands (white arrows), superficial vascularization from 4 to 7 o'clock along with marginal infiltrate at 7 o'clock (black arrow).

**Figure 1c:** Image of the left eye depicting squamous blepharitis, telangiectatic vessels with obliterated meibomian glands, circumcorneal congestion, corneal perforation at 4 to 5 o'clock associated with iris prolapse and shallow anterior chamber (black arrow).

**Figure 1d:** Image of the left eye post cyanoacrylate glue (black arrow) and bandage contact lens application.

**Figure 1e:** Image of the left eye at 1-year follow-up post cyanoacrylate glue removal and complete sealing of perforation (black arrow).

Since the perforation was small (2X2 mm) and peripheral, not involving the visual axis, we managed the patient with cyanoacrylate glue and BCL. The patient was managed conservatively with eyelid hygiene, hot fomentation, tablet doxycycline 100 mg twice a day for 3 weeks, eye drops 0.5% moxifloxacin with 0.5% loteprednol 4 times/day, eye drops carboxymethylcellulose 4 times/day in OS with cyanoacrylate glue application with BCL to seal the perforation (**Figure 1d**). The cyanoacrylate glue was applied under topical anesthesia under all necessary aseptic precautions. The glue was applied to the back portion of a corneal microsurgical wet sponge and was then gently placed over the perforation site as a thin uniform layer. Precautions were taken to avoid the excess spread of glue over the normal cornea, and then a BCL was placed over the cornea. OD patient was advised regarding eyelid hygiene, hot fomentation, eye ointment tobramycin two times/day with topical 0.5% carboxymethylcellulose 4 times/day. The patient was referred to a dermatologist for acne management and was advised to follow up after 3 days. The systemic evaluation confirmed the diagnosis, and he was started on oral Prednisolone in tapering doses of 40 mg, 30 mg, 20 mg, and 10 mg 5 days each along with antipruritic (1% Hydrocortisone) and antibacterial (0.5 gm Bacitracin) ointment. On follow-up after 3 days, OS examination revealed resolving blepharitis, minimal circumciliary congestion, sealed corneal perforation, a well-formed anterior chamber, and a clear lens.

Fundoscopy revealed self-resolved choroidal detachment. Visual acuity improved to 20/30. Since then, the patient has been on follow-up with topical medications for 1 year and is maintaining an excellent visual acuity of 20/20 OU (**Figure 1e**). The BCL was removed after 2 months of initial glue application, and in the same sitting, glue was removed as plaque under topical anesthesia. Corneal epithelialization was noted, and when needed, steroids were started and tapered timely based on the clinical response. The patient was counseled in detail regarding hygienic measures to avoid trauma in any form and excessive rubbing of the eye.

## DISCUSSION

Rosacea is a chronic skin pathology that often involves the face and chest. The disease usually develops in the 3rd to 6th decades of life. Characteristics features include erythema, telangiectasia, and recurrent flushing. Apart from these, other manifestations include papules, pustules, and swelling. Ocular involvement is reported to occur between 3-58% of patients with skin changes. (Lai et al., 2004) The most common ocular signs include chronic blepharoconjunctivitis, meibomitis, and evaporative dry eyes. Rosacea keratitis, coexisting with perforation, has a poor prognosis and can result in blindness. (Djaković et al., 2003) On reviewing the literature, we found that few cases of corneal perforation (Trufanov et al., 2019) have been reported in Rosacea, and only one case of scleral perforation (Barankin and Guenther, 2002) has been reported to date.

Trufanov, SV et al., in their case report of rosacea keratitis complicated by corneal perforation, suggested an innovative technique of mushroom keratoplasty with successful outcome. (Trufanov et al., 2019) Saade et al. depicted the use of emergent full-thickness tectonic corneal patch graft for peripheral corneal perforation. (“Ocular Rosacea Causing Corneal Melt in an African American Patient and a Hispanic Patient - PubMed,” n.d.) Medsinge et al., in the case series, highlighted the importance of Penetrating Keratoplasty (PKP) over conservative management in the management of corneal perforation. (Medsinge et al., 2016) In another case series of 3 patients by Park JC et al., they highlighted the surgical technique of tectonic lamellar keratoplasty for rosacea keratitis with peripheral corneal perforation over conservative approach. (Park and Habib, 2015)

Rosacea corneal perforation is a rare complication that can occur in chronic cases. Although patch grafting or penetrating keratoplasty is the terminal treatment for corneal perforations, meticulous examination, prompt intervention, and planned management can give excellent outcomes conservatively in

ocular rosacea perforation. In our case, there was a 2x2 mm peripheral corneal melt with perforation due to uncontrolled inflammation. We demonstrated that if managed meticulously with cyanoacrylate glue and BCL, the patient can have excellent visual outcomes. Through this case, we also want to highlight that the judicious and timely use of steroids, antibiotics, and copious lubricants is vital to check on inflammatory activity. As per the detailed literature review, almost all the previous cases have highlighted the importance of surgical intervention in the form of amniotic membrane grafting, patch grafting, or penetrating keratoplasty over conservative management. Ours is a rare case of ocular rosacea perforation managed conservatively with cyanoacrylate glue and BCL with the longest follow-up of one year. The differentiating points in our case from other published case reports are the use of cyanoacrylate glue, follow-up of one year, excellent control of inflammation, and visual outcome of 20/20.



## REFERENCES

- Awais, M., Anwar, M.I., Iftikhar, R., Iqbal, Z., Shehzad, N., Akbar, B. (2015) 'Rosacea - the ophthalmic perspective', *Cutaneous and Ocular Toxicology*, 34(2), pp. 161–166. doi:10.3109/15569527.2014.930749.
- Barankin, B. and Guenther, L. (2002) 'Rosacea and atopic dermatitis. Two common oculocutaneous disorders', *Canadian Family Physician Medecin De Famille Canadien*, 48, pp. 721–724. PMID: 12046367
- Djaković Z, Milenković S, Pesko P, Djukić N . (2003) '[Rosacea as a multisystemic disease]', *Srpski Arhiv Za Celokupno Lekarstvo*, 131(11–12), pp. 474–478. PMID: 15114791.
- Lai TF, Leibovitch I, James C, Huilgol SC, Selva D (2004) 'Rosacea lymphoedema of the eyelid', *Acta Ophthalmologica Scandinavica*, 82(6), pp. 765–767. doi:10.1111/j.1600-0420.2004.00335.x. PMID: 15606479
- Medsing A, Gajdosova E, Moore W, Nischal KK (2016) 'Management of inflammatory corneal melt leading to central perforation in children: a retrospective study and review of literature', *Eye (London, England)*, 30(4), pp. 593–601. doi: 10.1038/eye.2015.278. Epub 2016 Jan 29. PMID: 26821761; PMCID: PMC5108539
- Saade JS, Abiad B, Jan J, Saadeh D, McCulley JP, Bartley J (2017) 'Ocular Rosacea Causing Corneal Melt in an African American Patient and a Hispanic Patient', *Case Reports in Ophthalmological Medicine*, 2017, p. 2834031. doi: 10.1155/2017/2834031. Epub 2017 Oct 11. PMID: 29158934; PMCID: PMC5660782.
- Oge', L.K., Muncie, H.L. and Phillips-Savoy, A.R. (2015) 'Rosacea: Diagnosis and Treatment', *American Family Physician*, 92(3), pp. 187–196. PMID: 26280139.
- Park, J.C. and Habib, N.E. (2015) 'Tectonic lamellar keratoplasty: simplified management of corneal perforations with an automated microkeratome', *Canadian Journal of Ophthalmology. Journal Canadien D'ophtalmologie*, 50(1), pp. 80–84. doi: 10.1016/j.cjjo.2014.09.011. PMID: 25677289.
- Richter, S. (1965) '[SCLERAL PERFORATION IN ROSACEA KERATITIS]', *Klinische Monatsblätter Fur Augenheilkunde*, 146, pp. 422–424. PMID: 14306807.
- Trufanov SV, Krakhmaleva DA, Zaitsev AV, Salovarova EP, Tekeeva LY, Budnikova EA. (2019) '[Mushroom keratoplasty in rosacea keratitis complicated by corneal perforation (a clinical case)]', *Vestnik Oftalmologii*, 135(5. Vyp. 2), pp. 215–219. doi: 10.17116/oftalma2019135052215. PMID: 31691663
- Wladis, E.J. and Adam, A.P. (2018) 'Treatment of ocular rosacea', *Survey of Ophthalmology*, 63(3), pp. 340–346. doi: 10.1016/j.survophthal.2017.07.005. Epub 2017 Aug 4. PMID: 28782548.