

Case Report

Branch Retinal Vein Occlusion in a Case of Sarcoidosis

Ruchi Shrestha¹  , Ranju Kharel (Sitaula)², Pratap Karki², Sagun Narayan Joshi²

¹Reiyukai Eiko Masunaga Eye Hospital, Banepa, Kavre, Nepal

²B.P. Koirala Lions Centre for Ophthalmic Studies (BPKLCOS), Maharajgunj, Kathmandu, Nepal

Abstract

Introduction: Sarcoidosis is a chronic inflammatory disorder of unknown etiology which is characterized by non-caseating granuloma.. Its ocular presentation varies from anterior uveitis to rare venous occlusions.

Case: We present a rare case of sarcoidosis with bilateral hilar lymphadenopathy and a compatible uveitis. Presence of branch retinal vein occlusion in sarcoidosis is rare. In this case of sarcoidosis positive findings of mutton fat keratic precipitates, Koeppe's nodule, posterior synechiae, trabecular meshwork nodules, Candle wax dripping sign, Branch retinal vein occlusion and choroidal granuloma in one eye supported the diagnosis of sarcoidosis. Elevated serum acetylcholinesterase and bilateral hilar lymphadenopathy also confirmed the diagnosis of sarcoidosis.

Observations: The patient responded well to oral steroids and laser photocoagulation of the vein occlusion area. The patient developed complications of steroids like Herpes Zoster of abdomen and avascular necrosis of femur.

Conclusion: Branch Retinal Vein Occlusion is a rare vascular complication in ocular sarcoidosis. Systemic steroids and lasers for vein occlusion are the mainstay of treatment. Physicians must be aware of serious complications of steroid therapy, as seen in this case.

Key words: Branch retinal vein occlusion, Sarcoidosis, Steroids.

Financial Interest: Nil

Conflict of Interest: Nil

Received: 28.04.2020

Accepted: 03.11.2020

Corresponding author

Dr. Ruchi Shrestha

Reiyukai Eiko Masunaga Eye Hospital

Banepa, Kavre, Nepal

E-mail: drruchishrestha@gmail.com

Access this article online

Website: www.nepjol.info/index.php/NEPJOPH

DOI: <https://doi.org/10.3126/nepjoph.v13i1.28640>

Copyright © 2021 Nepal Ophthalmic Society

ISSN: 2072-6805, E-ISSN: 2091-0320



This work is licensed under a Creative Commons Attribution-NonCommercial-NoDerivatives 4.0 International License (CC BY-NC-ND).

Introduction

Sarcoidosis is a chronic inflammatory disorder of unknown etiology characterized by non-caseating granuloma. Sarcoidosis has variable ocular presentations from anterior uveitis to rare venous occlusions. Branch retinal vein occlusion is a rare vascular complication of sarcoidosis (Ohara K et al, 1995). The mainstay of treatment of ocular sarcoidosis is steroids which leads to serious complications. We report a case of ocular sarcoidosis with a rare presentation of supero-temporal branch retinal vein occlusion.

Case History

A forty-one-years-old male presented with the chief complaints of redness and blurred vision in left eye since the last two days. The patient had similar episodes of intermittent redness since the last two months, which was associated with frontal headache. There was no history of lumpy mass, whitish patches of rashes in the body. There was no history of fever, cough, swelling joint pain and weight loss. There were no systemic diseases like diabetes mellitus, hypertension and tuberculosis. The patient was plumber by occupation. The patient was a non-vegetarian and had never smoked or consumed alcohol. The patient was using an eye drop containing a combination of dexamethasone and chloramphenicol and also gentamicin eye drop for 2 days with no improvement before visiting us. On ocular examination the best corrected visual acuity (BCVA) in the right eye was 6/6 and left eye was 6/12. The intraocular pressure in the right and left eye was 16 mmHg and 18mmHg respectively. The anterior segment examination of the right eye was normal. The anterior segment examination of left eye showed diffuse conjunctival congestion; multiple medium to large mutton fat keratic precipitates (Figure 1) on the corneal endothelium; and there were multiple koeppe's nodules in the iris (Figure 1). There was 3+ anterior chamber reaction along with 2+ anterior chamber flare. Posterior synechiae was present at 3, 5, 9 and 11 o'clock positions. On dilatation the pupil appeared festooned. The lens was clear but there was 0.5+ vitreous haze was present.

Gonioscopy identified 3 trabecular meshwork nodules in the inferior quadrant of the left eye. The media was clear and the posterior segment in the right eye was normal. The posterior segment of left eye showed multiple dot and blot hemorrhages in the superotemporal quadrant sparing the macula. Yellowish peri-venous exudates were seen in the inferotemporal

quadrant suggestive of candle wax dripping sign. Multiple solitary yellowish choroidal lesions were seen in the inferior quadrant below the Inferotemporal arcade indicative of choroidal granulomas (Figure 2).

Blood investigations showed hemoglobin: 14.5gm/dl and total leucocyte count of 5800/mm³ with neutrophil 60%, lymphocyte 36%, eosinophil 1%, monocyte 3% and basophil 0%. The erythrocyte sedimentation rate was 12mm/hour and platelet count was 1,80,00/mm³. Biochemistry investigations showed random blood sugar: 6 mmol/litre serum uric acid: 315 micromol and serum calcium: 2.50mmol. The serum acetylcholinesterase was 72 unit/millilitre [Normal range 8-18 units/millilitre]. The liver function test was normal and serology tests including the Venereal Disease Research laboratory test (VDRL) were negative. The Mantoux test was negative with less than 5 mm induration. The routine urine microscopy was normal. Fundus fluorescein angiography (FFA) was done which confirmed venous occlusion at the site of superotemporal retinal vein. FFA showed hyperfluorescent area in the superotemporal quadrant of left eye due to blockage of choroidal fluorescence by hemorrhage (Figure 3). Chest X-Ray postero-anterior (PA) view showed bilateral hilar lymphadenopathy without parenchymal involvement (Figure 4). We consulted the chest physician and a high resolution computer tomography was performed, which revealed multiple enlarged mediastinal lymph nodes suggestive of sarcoidosis.

According to the International workshop on ocular sarcoidosis criteria definite sarcoidosis needs to be proven by tissue biopsy. The diagnosis of clinical sarcoidosis is based on clinical features and other ancillary investigations which consist of probable, possible or presumed sarcoidosis (Agrawal R et al, 2015). In our case presence of mutton fat keratic precipitates, Koeppe's nodules,

posterior synechiae, trabecular meshwork nodules, candle wax dripping sign, branch retinal vein occlusion and choroidal granuloma along with elevated serum acetylcholinesterase and bilateral hilar lymphadenopathy confirmed the diagnosis of presumed ocular sarcoidosis according to the international workshop on ocular sarcoidosis criteria.

Treatment was started with oral prednisolone at a dose of 1mg/kg body weight. The starting dose of oral steroid was 60 mg once daily which was tapered weekly. Oral prednisolone 55mg, 50mg, 40mg, 35mg, 30mg, 25mg, 20mg, 15mg, 10mg, 5mg was tapered each week with once a daily dose. Oral pantoprazole 40 mg was prescribed along with oral steroids. Topical prednisolone acetate eye drop was started 2 hourly and tapered as 6 hourly per week, 8 hourly per week, 12 hourly per week and 24 hourly per week. Topical tropicamide was started thrice weekly. The follow up was at 1 week and medicines were tapered for 1 month. At 2 months follow-up,

the signs of uveitis had disappeared (Figure 5) and the BCVA of left eye was 6/9. The retinal haemorrhages of the supero-temporal quadrant (Figure 6, a) had decreased at 2 months and the FFA revealed corresponding capillary drop out. (Figure 6, b). We then performed sectoral retinal laser photocoagulation in supero-temporal quadrant of the left eye and the final best corrected visual acuity at 3 months follow-up was 6/6 partial.

Figure 5 shows the disappearance of uveitis signs after treatment.

During the course of treatment with oral steroids the patient developed painful rashes in the abdomen. The patient also developed pain in the joints. Dermatology and orthopaedic consultation was done. The patient was diagnosed with herpes zoster of abdomen and received oral acyclovir as treatment. The patient also developed an avascular necrosis of head of femur which was treated by the orthopaedic surgeon.

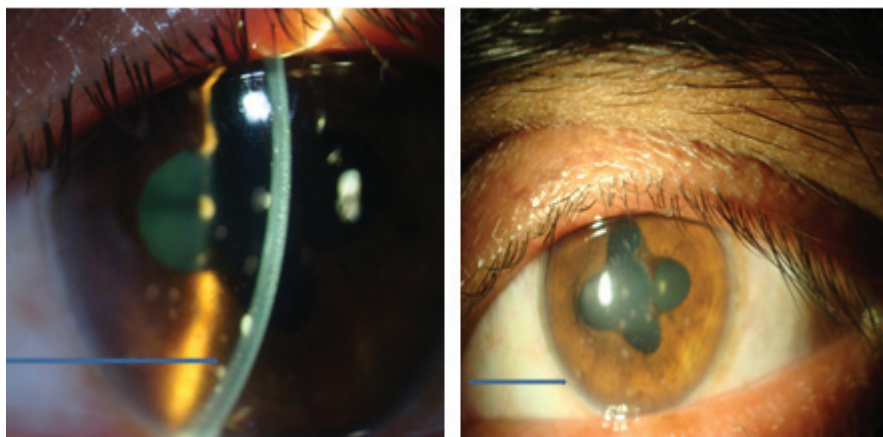


Figure 1: Anterior segment Left Eye. A: arrow showing Keratic precipitates in the corneal endothelium. B: arrow showing koeppes nodule and posterior synechiae.

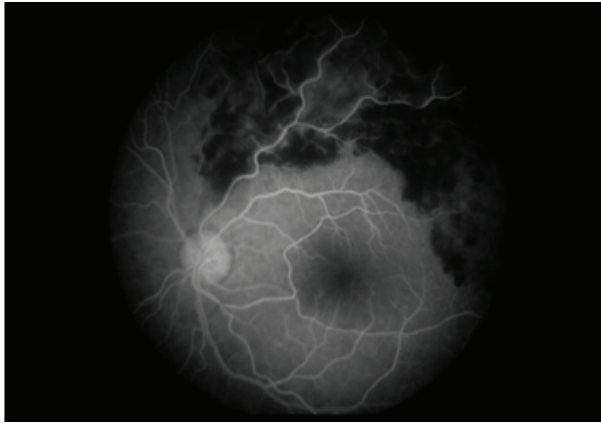

Figure 3: FFA shows blockage of choroidal fluorescence in superotemporal area.

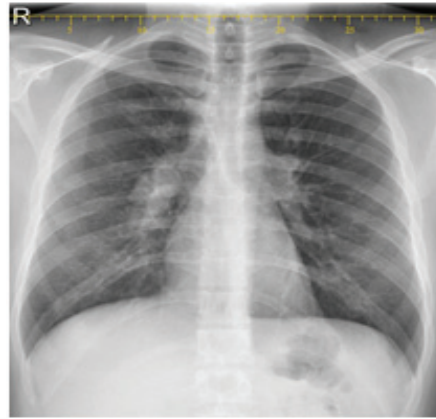


Figure 4: Chest X-ray PA view showing bilateral hilar lymphadenopathy

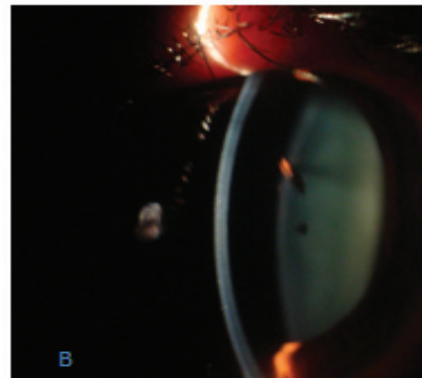
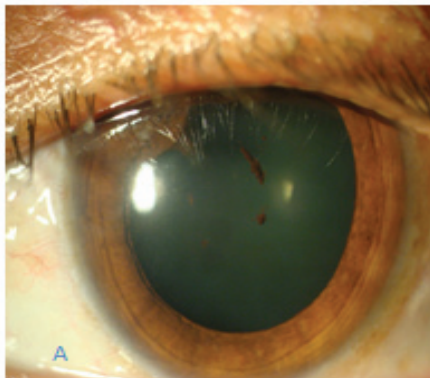


Figure 5: A. Demonstrates release of posterior synechiae and reduced keratic precipitates. B. Demonstrates reduced anterior chamber reaction

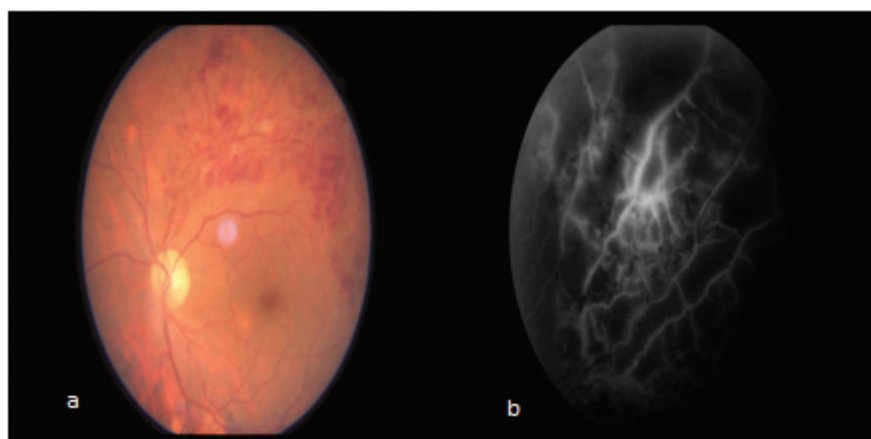


Figure 6: a. Fundus photo showing decreased hemorrhage.
b. Fluorescein angiogram showing capillary drop out areas

Discussion

Sarcoidosis has variable ocular presentations from anterior uveitis to rare venous occlusions. Branch retinal vein occlusion is rare in sarcoidosis but it may occur in rare cases like ours.

The patient in our case had features of bilateral hilar lymphadenopathy with compatible uveitis which confirmed the diagnosis of presumed sarcoidosis in the absence of tissue biopsy based on the International workshop on ocular sarcoidosis criteria (Agrawal R et al, 2015). Biopsy was not done in our case. The presence of non-caseating granuloma on tissue biopsy is the gold standard for the diagnosis of sarcoidosis. Tissue biopsy is invasive in nature and has limited indications in the eye. The diagnosis of ocular sarcoidosis is mostly clinical and supported by ancillary investigations (Chan AS et al, 2010).

There was branch retinal vein occlusion in the supero-temporal quadrant in this case which is very rare. The exact pathogenesis of vein occlusion in sarcoidosis is unknown. It may be a clinical manifestation of micro-angiopathy which is also found in other organs affected by sarcoidosis (Mikami R et al, 1986). The lumen of the retinal vessels may be compressed and occluded by perivascular proliferation and infiltration of the retinal vessels by sarcoid granulomas with lymphocytes and epithelioid cells. (Gould H et al, 1961).

A case of unilateral iridocyclitis, retinal periphlebitis, and severe branch retinal vein occlusion was reported (Okara et al, 1995) similar to our study but unlike our case the symptoms were present in a 13 year old child. This case responded well to systemic steroids similar to ours. Another case report presented unilateral superotemporal branch retinal vein occlusion in a case of sarcoidosis (Erdoğan Aydin et al, 2015) similar to ours. But unlike our case there was presence of bilateral acute retinopathy with vitreous hemorrhage and had

to undergo surgery for treatment.

Even mild symptoms of ocular sarcoidosis are treated to minimize the risk of vision loss. The mainstay of treatment of sarcoidosis are corticosteroids (Baughman RP et al, 2010). We treated our patient with both topical and oral steroids. We observed a dramatic improvement in the clinical symptoms and signs at 2 months. Areas of capillary drop out were seen in the supero-temporal retina at 2 months which improved with sectoral laser at 3 months follow-up.

Complications of oral steroids like Herpes Zoster of abdomen and avascular necrosis of femur developed in our case. This case was managed by the combined effort of an ophthalmologist, physician, dermatologist, and orthopedician.

Conclusion

Branch retinal vein occlusion may present as a rare vascular complication of ocular sarcoidosis for which the mainstay of treatment is systemic steroids and laser therapy. The treating ophthalmologist must remain vigilant about the serious complications of high dose systemic steroid therapy.

References

- Kunitoshi O, Akira O, Hiroshi S, Keiko K (1995). Branch Retinal Vein Occlusion in a Child with Ocular Sarcoidosis. *American Journal of Ophthalmology*;119(6): 806-807. DOI: <https://doi.org/10.1016/S0002-9394>
- Agrawal R, Julio J, Gonzalez L, Meier F, Gupta B, Carlos P (2015). Ocular and systemic features of sarcoidosis and correlation with the International Workshop for Ocular Sarcoidosis diagnostic criteria, Sarcoidosis vasculitis and diffuse lung diseases;32: 237-245.
- Chan AS, Sharma OP, Rao NA (2010) Review for disease of the year: immunopathogenesis of ocular sarcoidosis. *Ocular immunology and*

inflammation;18(3):143-151 DOI:<https://doi.org/10.3109/09273948.2010.481772>.

Mikami R, Sekiguchi M, Ryuzin Y, Kobayashi F, Hiraga Y, Shimada Y et al (1986). Changes in the peripheral vasculature of various organs in patients with sarcoidosis-possible role of microangiopathy. *Heart Vessels*;2:129-39.

Gould H, Kaufman HE (1961). Sarcoid of the fundus. *Arch Ophthalmol*;65(3):453-456. DOI:10.1001/archophth.1961.01840020455023

Baughman RP, Lower EE, Kaufman AH (2010). Ocular sarcoidosis. *Semin Respir Crit Care Med*;31(4):452-62. DOI: 10.1055/s-0030-1262213.

Erdinç A, Erkaan C (2015). Bilateral acute retinopathy with vitreous hemorrhage as a first manifestation of Sarcoidosis: A case report. *Turkiye Klinikleri J Ophthalmol*;24(1):50-54. DOI: 10.5336/ophthal.2014-39723.