

Case Report

Tick infestation masquerading as a nodule in the eye lid

Nirsara Shrestha¹, Sangeeta Shrestha¹, Arjun Shrestha¹, Barsha Suwal¹, Samata Sharma¹
¹Hospital for Children, Eye, ENT and Rehabilitation Services (CHEERS)

Abstract

Introduction: Ticks are ectoparasites which can lead to various blood borne diseases. Tick bite may resemble pigmented nevi, mole or nodule resulting a diagnostic dilemma. Tick bite in eye lid is rare and this case report describes tick bite in lower eye lid mimicking a traumatized pigmented nodule where the tick was identified only on magnification and was successfully removed mechanically.

Case: A 61-year-old man presented to the eye out patient department with a sudden and painful black pigmented lesion on the right lower lid for four days. The tick was manually removed with forceps

Conclusion: This case report explains the need for a high index of suspicion as tick bite in sudden or recent onset pigmented lesions especially in endemic areas.

Key words: Nodule, Tick bite, Eye lid.

Introduction

Ticks are ectoparasites which live by sucking blood of mammals, birds and reptiles. They act as vectors of various diseases. They transmit very serious diseases, including Crimean-Congo hemorrhagic fever, tick-borne rickettsiosis, and Lyme disease (Celebi and Orkun, 2016).

Tick infestation of ocular tissues is a rare occurrence. All areas of the eye are susceptible to tick infestation. Most common manifestation of globe involvement are conjunctivitis, uveitis, keratitis, and vasculitis. Eyelids have more limited effect (Rai et al, 2016). The most common eyelid manifestations of ticks

are transient pruritis, blepharitis, granuloma or abscess formation (Park and Suh, 2016). This report describes a male who presented complaining of painful, sudden onset nodular lesion on the eyelid. This report shows the ability of a blood-engorged tick to clinically simulate a traumatized or infarcting skin nodule.

Case report

A 61-year-old man presented to the eye out patient department with a black pigmented lesion on the right lower lid for four days. This nodule had developed suddenly and was very painful. He gave history of recent travelling to terai region of Nepal which is endemic for tick bite. There was no history of any trauma to eye. Examination revealed erythema of the left lower lid, at the centre of which was a black raised lesion which resembled traumatized skin nodule (Figure 1a and 1b).

On magnification under slit lamp, a body of tick with mobile legs adhering to the skin of lower eye lid was found (Figure 2).

Financial Interest: Nil

Conflict of Interest: Nil

Received: 02.11.2019

Accepted: 30.12.2019

Corresponding author

Dr. Nirsara Shrestha, MD

Department of Ophthalmology

Children's Hospital for Eye Ear and Rehabilitation

Service (CHEERS), Bhaktapur, Nepal.

ORCID ID: 0000-0001-6052-1201

E-mail: nirsara.shrestha@gmail.com

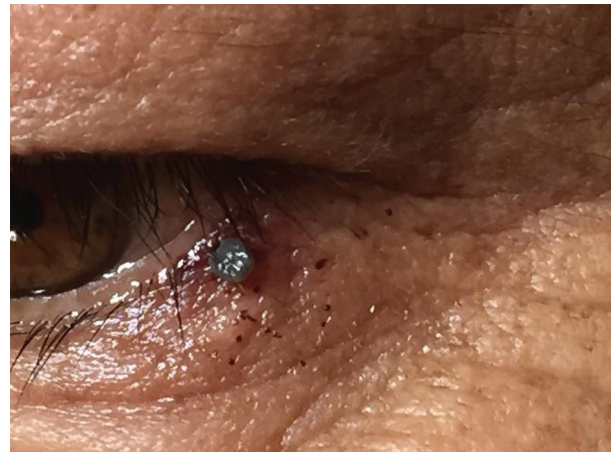
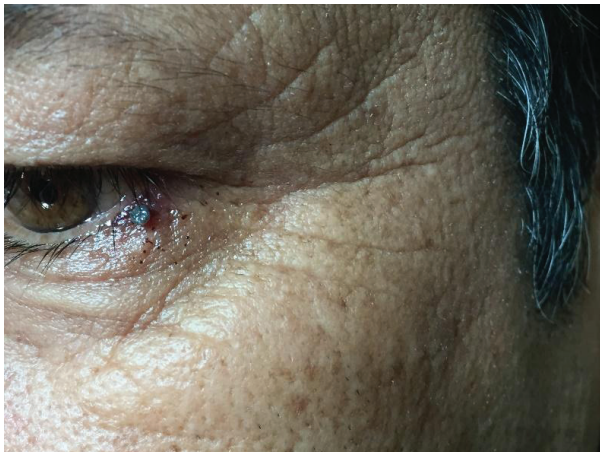


Figure 1a and 1b: Bluish black nodule on lower eyelid

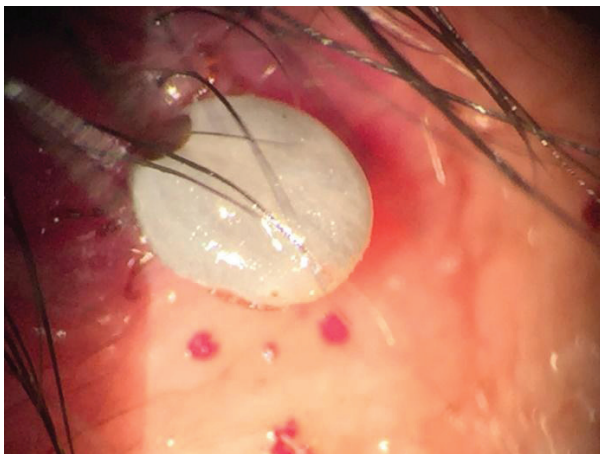


Figure 2: Tick mite (white body) with legs (black) adhered to the skin under slit lamp microscopy magnification

The anterior segment and the posterior segment of eye were normal. The patient was afebrile and no other systemic symptoms were observed.

Tick was manually removed with forceps. He was treated with ointment chloramphenicol and dexamethasone sodium phosphate applied twice daily for two weeks. He was informed in detail about ocular and systemic symptoms and signs of tick bite related disease and was referred to a physician. He made an uneventful recovery, the skin lesion healed and the erythema subsided. He did not develop any systemic or ocular complications on follow up.

Discussion

Ticks can intervene in different ways in several human diseases. They act as vectors for rickettsia and other types of bacteria, viruses and protozoa, and sometimes they produce toxins which can intoxicate humans (Santos-Bueso et al, 2006). There are two classes of ticks responsible for disease in humans: hard ticks (Family Ixodidae) and soft ticks (Family Argasidae). Hard ticks are more common than soft ticks. They are more likely to transmit disease to human and difficult to remove compared to soft ticks (Pitches, 2006).

Tick infestations of ocular tissue are rare. Ocular tick infestation can occur in any age group or sex with exposure in an endemic region. All parts of the ocular tissue are susceptible to tick related diseases (Park and Suh, 2016).

Most of times patients are unaware about tick bite and come with complaint of sudden growth on eye lid, however the clinical presentation of growth may vary. In Duke Eye clinic, a patient presented with dark growth in upper lid which doubled its size within two weeks. There was swelling and redness in the area surrounding the growth (Price and Woodward, 2009). Similarly, in another report, a child presented with dark raised lesion associated with surrounding erythema over lower eye

lid which had developed over one day. The body of a tick was obvious only on close examination (McLeod BK, 1986). At times, patient may assume as a mole as reported. There was itching and swelling of lower eye lid which appeared as a skin nodule with crusting on local examination. A swollen tick attached to eye lid was identified only on magnification (John et al, 2017).

In another report, patient presented with erythema and mild swelling of the right upper lid with a yellowish lesion at the centre. The body of a tick with four pairs of legs was visible only on close examination (Park and Suh, 2016).

Lin et al reported similar case of right lower eyelid pigmented nodule associated with pain, tingling and numbness of cheek for 1 week. Ticks along with its waste was identified and removed successfully. After a month she developed a localized pruritic erythematous rash. Later she was diagnosed as tick bite-related contact dermatitis (Lin et al, 2016).

Another case of ticks which the patient discovered on his right upper eyelid. He attempted to remove a portion of parasite with his fingers and some portion was retained subcutaneously. After a few weeks, he presented with a firm, mobile, nontender, subcutaneous nodule directly beneath the skin. There was no tenderness, erythema, fluctuance, or expression of material with pressure (Rai et al, 2016).

Many methods of tick removal have been reported in the literature while some are accepted from controlled studies whereas some not recommended due to an increase in the risk of infection (Gammons and Salam, 2002). Application of a hot match, lidocaine gasoline, alcohol, or nail polish to the tick body, covering the tick with petroleum jelly and passing a suture needle through the tick are dangerous as they may induce the tick to salivate and regurgitate into the attachment

site. In addition, use of sharp forceps, and twisting off the head should be avoided, as they may result in leakage of the ticks' potentially infectious body fluids (Needham, 1985). The best options for removal of ticks are either using a blunt, medium-tipped, angled forceps, or en bloc excision in case of retained mouth parts (Gammons and Salam, 2002; Bowes et al, 2015). The bite area should be examined carefully for any retained mouthparts after removal of tick. All the methods of removal are directed toward complete elimination to prevent late complications (Price and Woodward, 2009).

Clinicians should be aware of possible local and systemic diseases that may arise after tick infestation of the eye and its adjacent structures. Extraction of the whole tick using blunt forceps is an effective treatment option and was applied in this case.

This patient did not receive oral antibiotic prophylaxis and was counseled regarding clinical features of Lyme disease and was advised for follow up with physician. The role of antibiotic prophylaxis to prevent Lyme disease following tick bite remains uncertain (Warshafsky et al, 1996). However, doxycycline prophylaxis is recommended in selected patients (Wormser et al, 2006).

Conclusion

This report illustrates the need for a high index of suspicion as tick bite in sudden or recent onset pigmented lesions especially in endemic areas. Tick should be removed mechanically with gentle traction or punch biopsy depending on clinical presentation and site of tick bite.

References

- Bowes OM, Legg G, Haines R, Vardy SJ (2015). Tick infestation of the upper eyelid. *Can J Ophthalmol*;50:e39-40.
- Celebi ARC, Orkun O (2016). A rare case of tick infestation of the eyelid: case report

and literature review. *Revista Brasileira de Oftalmologia*;75:144-146.

Gammons M, Salam G (2002). Tick removal. *Am Fam Physician*; 66:643-5.

John M, Raman M, Ryan K (2017). A tiny tick can cause a big health problem. *Indian Journal of Ophthalmology*;65:1228-1232.

Lin Y-H, Yeung L, Sun C-C, Ku W-C, Yang J-W (2016). Contact dermatitis on the lower eyelid related to tick infestation: A case report in Taiwan. *Taiwan journal of ophthalmology*; 6: 201-203.

McLeod BK (1986). Sheep tick in the eyelid. *British Journal of Ophthalmology*;70:75-76.

Needham GR (1985). Evaluation of five popular methods for tick removal. *Pediatrics*;75:997-1002.

Park J, Suh E (2016). Tick Infestation of the Eyelid and Removal With Forceps and Punch Biopsy. *J Craniofac Surg*;27:2098-2100.

Pitches DW (2006). Removal of ticks: a review of the literature. *Euro Surveill*;11:E060817.4.

Price KM, Woodward JA (2009). Management of tick infestation of the eyelid. *Ophthalmic Plast Reconstr Surg*;25:328-30.

Rai R, Yoon MK, Stacy R C (2016). Tick Infestation of the Eyelid With Histopathologic Characterization. *Ophthalmic Plast Reconstr Surg*;32:e55-8.

Santos-Bueso E, Calvo-Gonzalez C, Diaz-Valle D, Benitez-Del-Castillo JM, Garcia-Sanchez J (2006). Eyelid tick bite. *Arch Soc Esp Oftalmol*;81:173-5.

Warshafsky S, Nowakowski J, Nadelman RB, Kamer RS, Peterson SJ, Wormser GP (1996). Efficacy of antibiotic prophylaxis for prevention of Lyme disease. *J Gen Intern Med*;11:329-33.

Wormser GP, Dattwyler RJ, Shapiro ED, Halperin JJ, et al (2006). The clinical assessment, treatment, and prevention of Lyme disease, human granulocytic anaplasmosis, and babesiosis: clinical practice guidelines by the Infectious Diseases Society of America. *Clin Infect Dis*;43:1089-134.