


Use of Bedside Ultrasound for Ophthalmic Evaluation in a Case of Traumatic Brain Injury: A Case Report

Bipin Karki¹ , Ninadini Shrestha¹, Ashru Neupane², Hony KC³, Pramesh Sunder Shrestha¹, Santosh Acharya⁴

¹Maharajgunj Medical Campus, Institute of Medicine, Maharajgunj, Kathmandu, Nepal

²Om Hospital and Research Center, Chabahil Kathmandu, Nepal

³Birat Eye Hospital, Biratnagar, Morang, Nepal

⁴Hospital for Advanced Medicine and Surgery, Dhumbarahi, Kathmandu, Nepal

ABSTRACT

Background: Ophthalmological examination is an important aspect of the neurological assessment in a patient with traumatic brain injury (TBI). However, significant periorbital swelling can make direct visualization of the pupils difficult. Ultrasonic examination can be a valuable bedside tool when direct visualization fails.

Case: A case of a seven-year-old female child who had presented with a history of TBI is reported here.

Observations: The periorbital swelling prevented the direct visualization of the eyes. Bedside evaluation with a multipurpose ultrasound (USG) was used to monitor the pupillary diameter (PD) and the consensual pupillary light reflex (PLR) at regular intervals. The PD was measured in the B-mode while the PLR was monitored in M-mode of the USG. The optic nerve sheath diameter (ONSD) was also monitored as a correlate of intracranial pressure (ICP).

Conclusion: Ophthalmic evaluation of PD and PLR can be easily and objectively done on the bedside using USG especially in cases where the direct visualization of the pupils is difficult due to injuries and swelling of the periorbital tissues. Furthermore, ONSD measurements can also be done to monitor the changes in the ICP.

Key words: Consensual light reflex, Optic nerve sheath diameter, Pupillary size, Traumatic brain injury, Ultrasound.

Financial Interest : Nil

Received : 29.12.2021

Conflict of Interest : Nil

Accepted : 05.05.2022

Corresponding Author

Dr. Bipin Karki
Department of Critical Care Medicine,
Maharajgunj Medical Campus, Institute of Medicine,
Maharajgunj, Kathmandu, Nepal.
E-mail: karki_bipin@yahoo.com



Access this article online

Website: www.nepjol.info/index.php/NEPJOPH

DOI: <https://doi.org/10.3126/nepjoph.v15i1.27187>

Copyright © 2022 Nepal Ophthalmic Society

ISSN: 2072-6805, **E-ISSN:** 2091-0320



This work is licensed under a Creative Commons Attribution-NonCommercial-NoDerivatives 4.0 International License (CC BY-NC-ND).

INTRODUCTION

Ophthalmic evaluation for the size and reaction to light of pupils is an important aspect in the management of any case of traumatic brain injury (TBI) (Goebert, 1970; Ciuffreda et al., 2017). However, direct visualization which is the usual method, is often very difficult due to the associated injuries which can cause significant periorbital bruises and swellings. A similar case of TBI is reported here in which we had used a bedside ultrasound to assess the pupils due to inability to directly visualize the pupils.

CASE REPORT

A seven-year-female had presented to the emergency department (ED) with the chief complaints of decreased responsiveness following an alleged history of fall from a one story building over a concrete floor half an hour back. On arrival, her Glasgow Coma Scale

(GCS) was E3V4M5 (12/15). She had swelling and ecchymosis of bilateral upper and lower eyelids with a few bruises over the cheeks. However retraction of the lids was possible which revealed bilaterally equal, round, regular, and reactive pupils of 3 mm diameter. She was maintaining an arterial oxygen saturation of 95% in ambient air. Her heart rate was 130 beats per minute and blood pressure was 130/80 mm of mercury. During her stay in the ED, she developed two episodes of generalized tonic-clonic seizure (GTCS) in the ED which was managed with intravenous midazolam 2 mg intravenous (IV) boluses and injection levetiracetam 300 mg was administered IV for an estimated body weight of 28 kgs. Injection mannitol 20%, 60 ml was also administered IV and an urgent computed tomography (CT) scan - head was obtained which revealed a lineal undisplaced fracture of frontal bone extending to the left parietal bone with a small right frontoparietal extradural hematoma (EDH) without mass effects (Figure 1a and 1b).

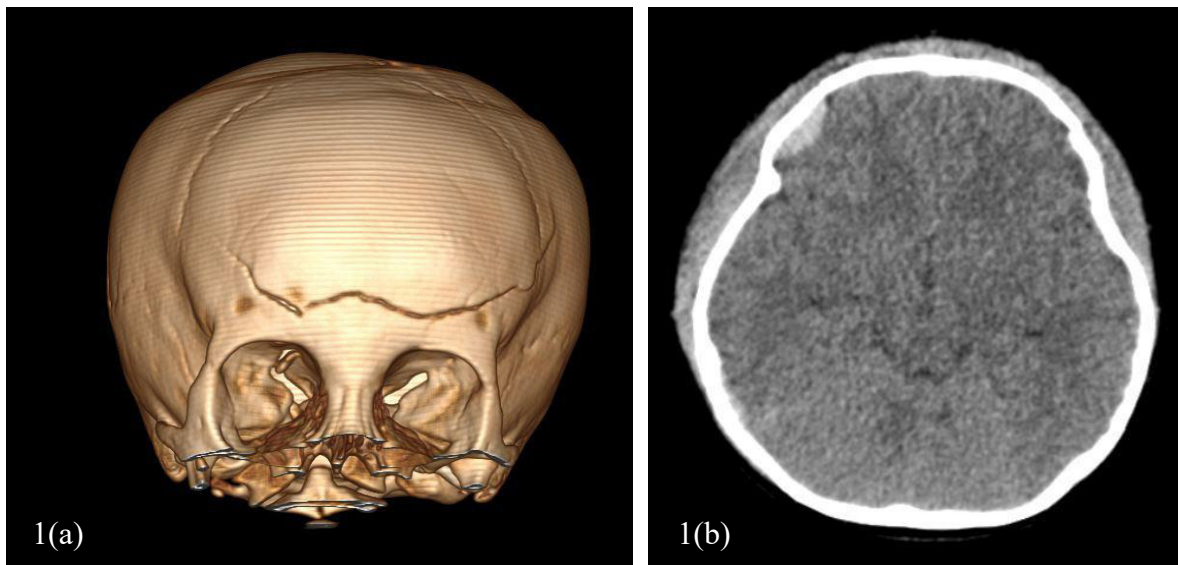


Figure 1(a): 3D reconstruction image showing the undisplaced fractured frontal bone

Figure 1(b): Small right frontal EDH

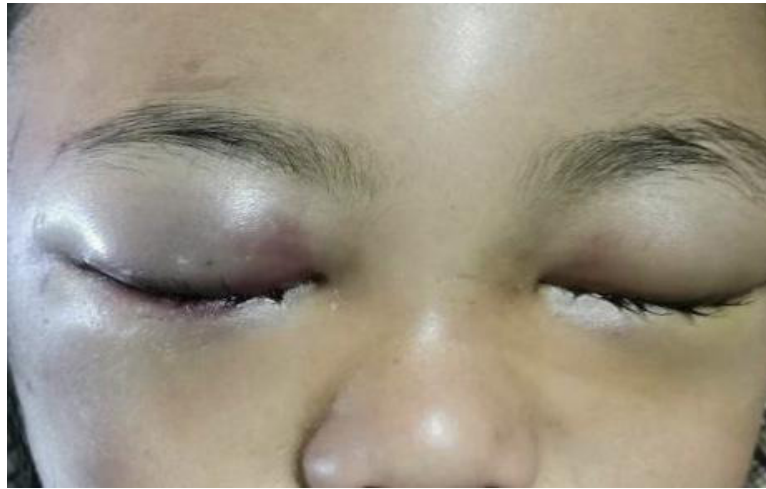

Figure 2: Periorbital swelling and raccoon eyes as a result of the cranial bone fracture.

She had a negative focused assessment with sonography for trauma (FAST) scan with normal complete blood counts, renal and liver function tests, and a normal X-ray of cervical spine. She was then shifted to the intensive care unit (ICU) for further management. She was treated with injection mannitol, levetiracetam, paracetamol, and ondansetron. By the time she reached the ICU, the periorbital swellings had increased to an extent that the pupils could not be directly visualized by retraction of the eyelids (Figure 2).

Since direct visualization was not possible, we performed an ultrasonogram (USG) of the eyes. The pupillary diameter (PD) and consensual pupillary light reflex (PLR) were monitored using the B and M modes respectively every six hours and as needed. The optic nerve sheath diameter (ONSD) was also measured every six hours for monitoring of the intracranial pressure.

Cold compression was applied to both eyes. She was monitored for two more days with no major issues. On day three, she was shifted to the ward from where she was discharged home on day six.

DISCUSSION

Traumatic brain injury is a major cause of morbidity and mortality. As a part of the clinical evaluation of a patient with TBI, ophthalmic examination for the size and the reaction of the pupils (both direct and consensual) to light is a very important aspect and have been linked to the outcomes (Chen et al, 2011; Goebert, 1970). A common problem encountered in the assessment however, is the associated periorbital swelling and 'the raccoon eyes' because of cranial bone fractures which often make it impossible to directly visualize the pupils for examination. Use of ultrasound for the ophthalmologic examinations can have an advantage in these situations (Schmidt et al., 2017; Sargsyan et al., 2009; Fledelius, 1997). Numerous ultrasonographic measurements have been developed and validated for neuro-monitoring. Some of which include transcranial Doppler and pulsatility index, pupillary constriction velocity, and consensual sonographic PLR (Kasapas et al, 2014). Here we used the USG to monitor PD and consensual

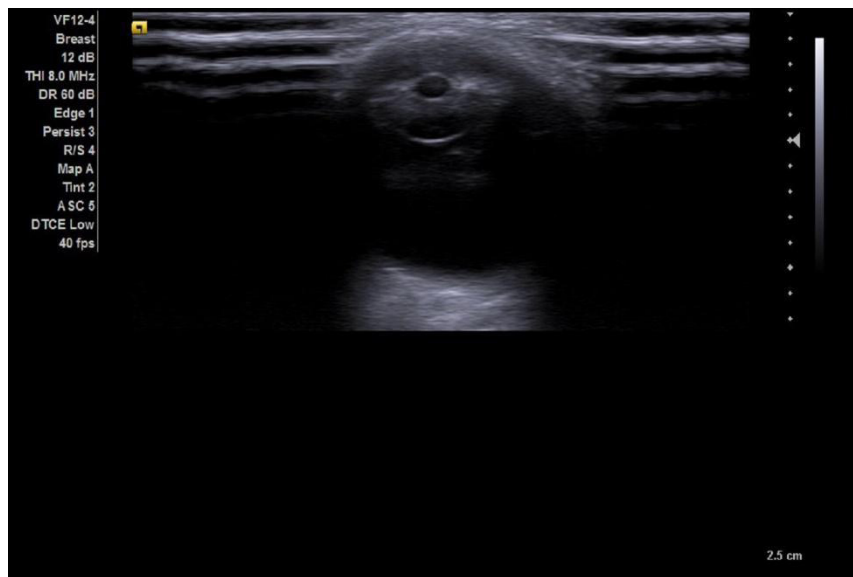

Figure 3: Ultrasonogram visualization of the pupil in B-mode. Note the significant thickness of soft tissue echo-texture anterior to the iris due to the eyelid swelling.

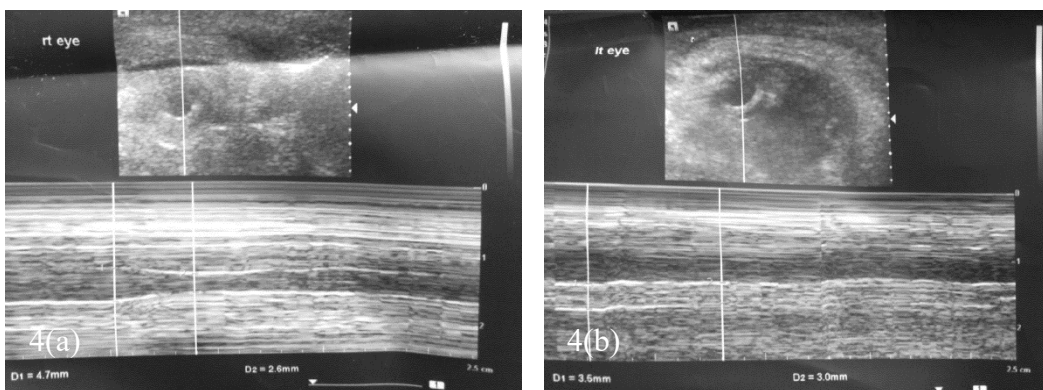


Figure 4 (a, b): M-mode scan of the right and left eyes showing the real time change in the pupillary diameter.

PLR. For this, a high frequency linear probe (4-12Hz) from a multipurpose USG machine was used. The probe was positioned tangentially from either of the orbital margins to visualize the pupil in a coronal plane. B-mode was used for the direct measurement of PD whereas the M-mode was used to elicit the real time changes with consensual PLR (Figures 3 and 4).

Furthermore, the assessment in M-mode can be used to objectify the PLR in terms of the degree of constriction of the pupils and the reaction time as well. Similarly, ONSD was also measured periodically which has been found to closely correlate with ICP (Wang et al., 2019). The measurements are more objective and the findings recordable with USG as compared to direct visualization which can be subjected to interobserver variations (Chen et al., 2011).

CONCLUSION

Examination of the eyes and pupils are some of the most important clinical examination tools available for neuro-monitoring. Inability to examine the pupils in some patients due to various reasons can be blinding to a treating clinician. Use of ultrasound to measure the PD, PLR, and ONSD can circumvent these problems.

Furthermore, the findings are more objective, semi-quantitative, have lower interobserver variability on top of being non-invasive and easy to use in the bedside as compared with direct visualization which may have subjective biases.



List of abbreviations

ED	Emergency Department
EDH	Extradural Hematoma
FAST	Focused Assessment with Sonography for Trauma
GCS	Glasgow Coma Scale
GTCS	Generalized Tonic Clonic Seizures
ICP	Intracranial Pressure
ICU	Intensive Care Unit
IV	Intravenous
ONSD	Optic Nerve Sheath Diameter
PLR	Pupillary Light Reflex
TBI	Traumatic Brain Injury
USG	Ultrasonography/ Ultrasonogram/ Ultrasound

REFERENCES

- Chen J, Gombert ZJ, Rogers S, Gardiner SK, Cecil S, Bullock RM (2011). Pupillary reactivity as an early indicator of increased intracranial pressure: The introduction of the neurological pupil index. *Surgical Neurology International*; 2(1): 82. DOI: [10.4103/2152-7806.82248](https://doi.org/10.4103/2152-7806.82248)
- Ciuffreda KJ, Joshi NR, Truong JQ (2017). Understanding the effects of mild traumatic brain injury on the pupillary light reflex. *Concussion*; 2(3): 36. DOI: [10.2217/cnc-2016-0029](https://doi.org/10.2217/cnc-2016-0029)
- Fledelius HC (1997). Ultrasound in ophthalmology. *Ultrasound in Medicine and Biology*; 23(3): 365–375. DOI: [10.1016/S0301-5629\(96\)00213-X](https://doi.org/10.1016/S0301-5629(96)00213-X).
- Goebert HW (1970). Head injury associated with a dilated pupil. *The Surgical clinics of North America*; 50(2): 427–432. DOI: [10.1016/S0039-6109\(16\)39090-9](https://doi.org/10.1016/S0039-6109(16)39090-9)
- Kasapas K, Diamantopoulou A, Pentilas N, Papalois A, Douzinas E, Kouraklis G, Slama M et al (2014). Invasive and ultrasound based monitoring of the intracranial pressure in an experimental model of epidural hematoma progressing towards brain tamponade on rabbits. *Scientific World Journal*;14:1-10. DOI: [10.1155/2014/504248](https://doi.org/10.1155/2014/504248)
- Sargsyan AE, Hamilton DR, Melton SL, Amponsah D, Marshall NE, Dulchavsky SA (2009). Ultrasonic evaluation of pupillary light reflex. *Critical Ultrasound Journal*;1(2):53–57w. DOI: [10.1007/s13089-009-0012-9](https://doi.org/10.1007/s13089-009-0012-9)
- Schmidt FA, Ruprecht K, Connolly F, Maas MB, Paul F, Hoffmann J, et al. (2017). B-mode ultrasound assessment of pupillary function: Feasibility, reliability and normal values. *PLoS One*;12(12):1–10. DOI: [10.1371/journal.pone.0189016](https://doi.org/10.1371/journal.pone.0189016)
- Wang J, Li K, Li H, Ji C, Wu Z, Chen H, et al. (2019). Ultrasonographic optic nerve sheath diameter correlation with ICP and accuracy as a tool for noninvasive surrogate ICP measurement in patients with decompressive craniotomy. *Journal of Neurosurgery*;133(2):1–7. DOI: [10.3171/2019.4.jns183297](https://doi.org/10.3171/2019.4.jns183297)