

## Original Article

# Efficacy of Topical Cyclosporine 0.05% the Treatment of Vernal Keratoconjunctivitis

Kumudini Subedi<sup>1</sup>, Binita Sharma<sup>2</sup>, Sabina Shrestha<sup>3</sup>

<sup>1</sup>Chitwan Eye Hospital, Chitwan, Nepal

<sup>2</sup>Kirtipur Eye Hospital, Kathmandu, Nepal

<sup>3</sup>Kathmandu Medical College Teaching Hospital, Kathmandu, Nepal

## Abstract

**Introduction:** Vernal Keratoconjunctivitis is a chronic bilateral seasonally exacerbated allergy affecting the conjunctiva and cornea of children. As technology has advanced, newer medications have been developed for the control of the disease.

**Purpose:** To assess the effectiveness of an immunomodulator, cyclosporine, in the treatment of vernal keratoconjunctivitis.

**Materials and methods:** Fifty patients of moderate, severe to very severe vernal keratoconjunctivitis were selected for the study. They were given cyclosporine 0.05% eye drops in loading dose followed by gradual tapering. Symptoms and signs were recorded at presentation, after two weeks, after four weeks, after two months and after three months.

**Results:** Vernal keratoconjunctivitis, being a chronic disease showed marked improvement with immunomodulator therapy. There was significant improvement in the symptom and sign score initially, at the first follow up itself with symptom score reduction from median of mean of 2.4 to 0.6 ( $p=0.00$ ) and a similar sign score reduction from 1.75 to 0.625 ( $p=0.00$ ). There was gradually more improvement as therapy continued and the beneficial effects were maintained till the end point of the study at three months where median of mean symptom score was 0.4 ( $p=0.00$ ) and similar sign score of 0.375 ( $p=0.000$ ).

**Conclusion:** Topical cyclosporine proved to be an effective and safe treatment strategy to treat cases of moderate, severe and very severe vernal keratoconjunctivitis.

**Key words:** Vernal keratoconjunctivitis, Cyclosporine, Immunomodulator.

## Introduction

Vernal keratoconjunctivitis (VKC) is a chronic, bilateral, seasonally exacerbated allergic inflammation of the conjunctiva and cornea. It is characterized by intense ocular symptoms, including itching, photophobia, foreign body sensation, burning, and thick mucus hypersecretion with sticky filaments called "ropy discharge." In addition to a type 1 hypersensitivity reaction, a type 4

**Financial Interest:** Nil  
**Conflict of Interest:** Nil

Received: 17.07.2019

Accepted: 10.10.2019

**Corresponding author**

Dr. Kumudini Subedi  
Ophthalmologist, Chitwan Eye Hospital, Nepal  
E-mail: kumusubedi@gmail.com



hypersensitivity reaction also seems to play an important role. Genetic and environmental factors are also considered to be important at the onset and through the progression of the disease (Oray & Toker, 2013). It may involve the cornea and can be sight threatening (Ozcan et al, 2007).

Major and minor criteria have been defined for diagnosis of VKC (Leonardi A, 2002; Leonardi A et al, 2006). Major clinical features are those which are present in more than 80% of patients. They are: bilateral presentation, age <20 years, symptom of itching, signs including presence of papillae, bilaterality, conjunctival hyperemia, superficial keratopathy and a conjunctival cytology showing eosinophils in conjunctival scrapings. Minor clinical features are those present in less than 80% of patients. They are: seasonal presentation, male sex, symptoms of photophobia, mucous discharge, tearing, burning; signs including Horner-Trantas dots, corneal shield ulcer and ptosis.

The prevalence of vernal keratoconjunctivitis has been found to vary as reported from 1 in 2000 in temperate climates to 33% in children and up to 90% in adolescents in tropical climates especially in the Mediterranean region and Indian subcontinent as also in many parts of Africa, Latin America and Asia (Smedt et al, 2012; Arbab & Mirza, 2011; Ozcan et al, 2007; Leonardi et al, 2006; Leonardi, 2002; Buckley, 1988). A population prevalence of 4% to 5% has been found among African children (Smedt et al, 2012; Daniell et al, 2006). In large European and Asian case series boys appear to be affected more than girls, but this sex distribution is not found uniformly in Africa, and becomes less obvious with age (Oray & Toker, 2013; Ozcan et al, 2007; Arbab & Mirza, 2011; Smedt et al, 2012; Leonardi, 2002; Daniell et al, 2006; BenEzra et al, 1986; Kashani & Mearza, 2008; BenEzra, 1993).

Ciclosporin A (Cyclosporine A) is a non-steroidal immunomodulator that inhibits antigen

dependent T cell activation. Ciclosporin also has a direct inhibitory effect on eosinophil and mast cell activation and release of mediators, which is likely to be important in allergic inflammation (Daniell et al, 2006).

Cyclosporine A 0.05% treatment significantly reduces the tear levels of IL-4, IL-5, IL-17,

TNF- $\alpha$ , IFN- $\gamma$  and eotaxin compared with baseline. Cyclosporine A is effective in controlling ocular inflammation by blocking Th2 lymphocyte proliferation and IL-2 production. It also inhibits histamine release from mast cells and basophils, and through a reduction of IL-5 production, it may reduce the recruitment of eosinophils to the site of inflammation (Oray & Toker, 2013).

Topical cyclosporine 0.05% has been shown to have a low side effect profile. There is an absence of lid skin maceration, blurring, burning and stinging in a study done with four hourly applications done for two weeks followed by six hourly applications for next ten weeks (a total duration of three months). This has been the highest dosage regimen of 0.05% cyclosporine applied for the treatment of vernal keratoconjunctivitis in recent literature. No side effects attributed to Cyclosporine A were encountered during the study period. This is important in maintaining patient compliance, especially in children (Oray & Toker, 2013).

This study aims to study the response of cases of moderate, severe or very severe vernal keratoconjunctivitis by application of topical cyclosporine 0.05%. As the side effect profile of topical steroids are well known and may be permanently visually incapacitating, this study aims to establish cyclosporine 0.05% as a viable alternative to topical steroids in the treatment of vernal keratoconjunctivitis.

### **Materials and methods**

This was a prospective, hospital-based study done by convenient sampling at the out-

patient department of Nepal Eye Hospital, Tripureshwor, Kathmandu. The duration of the study was one and a half years (August 2013 to March 2015).

50 patients of moderate, severe or very severe VKC were included in the study. Inclusion criteria used were- patients with clinically diagnosed VKC on the basis of signs and symptoms at presentation, had adequate follow up and had not used topical steroids in the past 2 weeks. Only children above the age of 6 years were eligible for the study. Only patients who were able to complete follow-up of 3 months duration were included in the study and for analysis of results. All patients who could not complete the follow up protocol were excluded from this study.

Diagnosis and grading of signs and symptoms of vernal keratoconjunctivitis was made on the basis of symptoms and signs, as a combination of parameters used in previous studies at presentation and at each follow up ( Ozcan et al, 2007; Arbab & Mirza, 2011; Akpek et al, 2004).

Treatment protocol was the same for all patients included in the study and stratification of results based on disease severity was not done. On the basis of the scoring system, a total score (sum of signs and symptom score) of 10-20 was considered as moderate, 20-30 was considered severe and more than 30 was considered very severe. The study included 6 cases of moderate, 35 cases of severe disease and 9 cases of very severe VKC.

Treatment protocol included topical cyclosporine 0.05% (SUN pharmaceuticals) in a loading dose of four times a day for two weeks followed by gradual tapering to three times a day for a week then twice a day for the next week and finally once a day for a week. Maintenance dose of one drop/day on alternate days was continued until the final follow up. The basis of this was to maintain a loading dose

and maintenance dose schedule considering the minimum schedule used amongst all previous studies and also to prevent a rebound phenomenon on sudden stopping of medication.

## Results

There were 50 patients of moderate, severe and very severe vernal keratoconjunctivitis included in this study. Amongst them 36 were males and 14 were females, a gender ratio of (2.57:1), which is consistent with the male predominance seen in previous studies.

Considering the rural: urban distribution of patients, 25 patients belonged to rural background and 25 patients to urban background. In terms of duration of the disease, 2 patients had had the disease for less than 6 months, 7 for 6-12 months, 10 for 12-18 months, 5 for 18-24 months and 26 patients had been suffering from VKC for more than 24 months (2 years).

The Wilcoxon signed rank test was used to compute statistics for this data set.

At first follow-up, there was a significant decrease in symptom score from a median of mean of 2.4 (range 1.2-3) to 0.6 (range 0-1.6) with p value of 0.000. Also, sign score decreased from a median of mean of 1.75 (range 0.5-2.63) to 0.625 (range 0.25-1.38) with a p value of 0.000.

At the one month visit, this improvement was more marked with a median of mean symptom score of 0.2 (range 0-0.8), with a p value of 0.000. Median (of mean) sign score was 0.25 (range 0-0.88), with a p value of 0.000.

At third follow-up, at two months, the median of mean symptom score was 0.2 (range 0-0.8) which was still significantly better than the initial score of 2.4 (p value of 0.000). The median of mean of sign score at this time frame was 0.25 (range-0-0.63), which was also statistically significant (p value 0.000).

**Grading of symptoms was done as follows:**

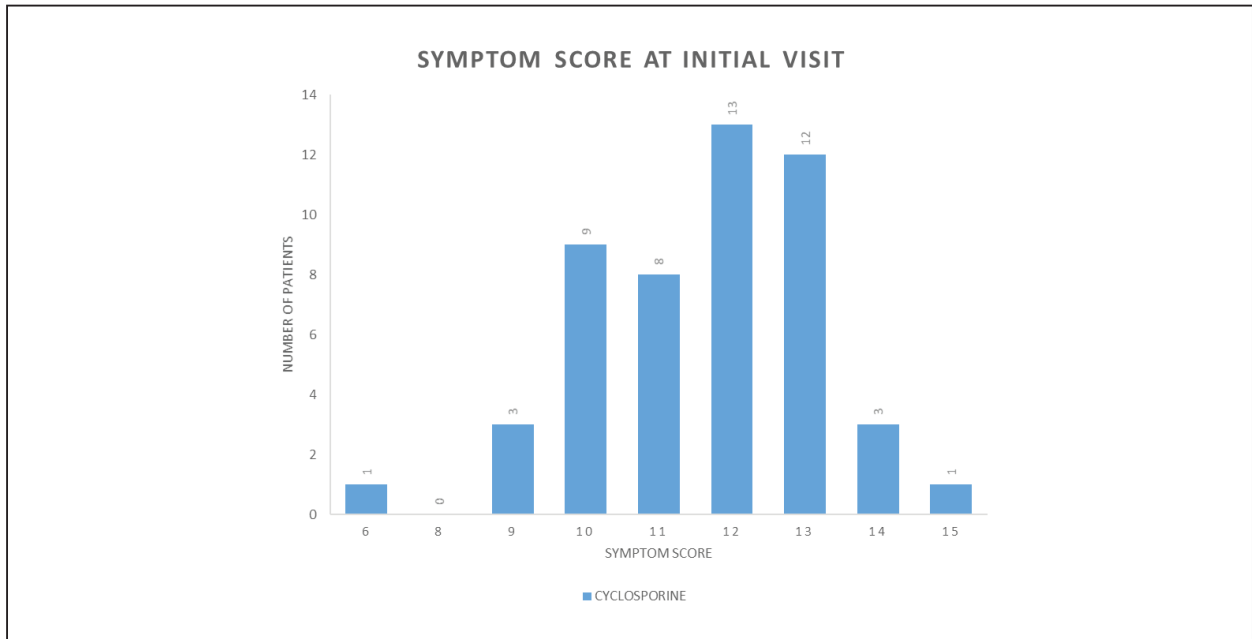
Symptom score/ Symptom	0	1	2	3
Itching	No	Occasional	Frequent	Constant
Tearing	Normal tear	Sensation of fullness of conjunctival sac	Infrequent spilling of tears over the lid margin	Constant spilling of tears over the lid margin
Discomfort(burning, stinging and foreign body sensation)	Absent	Mild	Moderate	Severe
Discharge	No	Small amount of mucoid discharge	Moderate amount of mucoid discharge, presence of crust upon awakening	Eyelids tightly matted together on awakening, warm soaks necessary to clean eyelids during day
Photophobia	No	Mild	Moderate, necessitating dark glasses	Extreme photophobia, even with dark glasses

**Grading of the clinical signs was done as follows:**

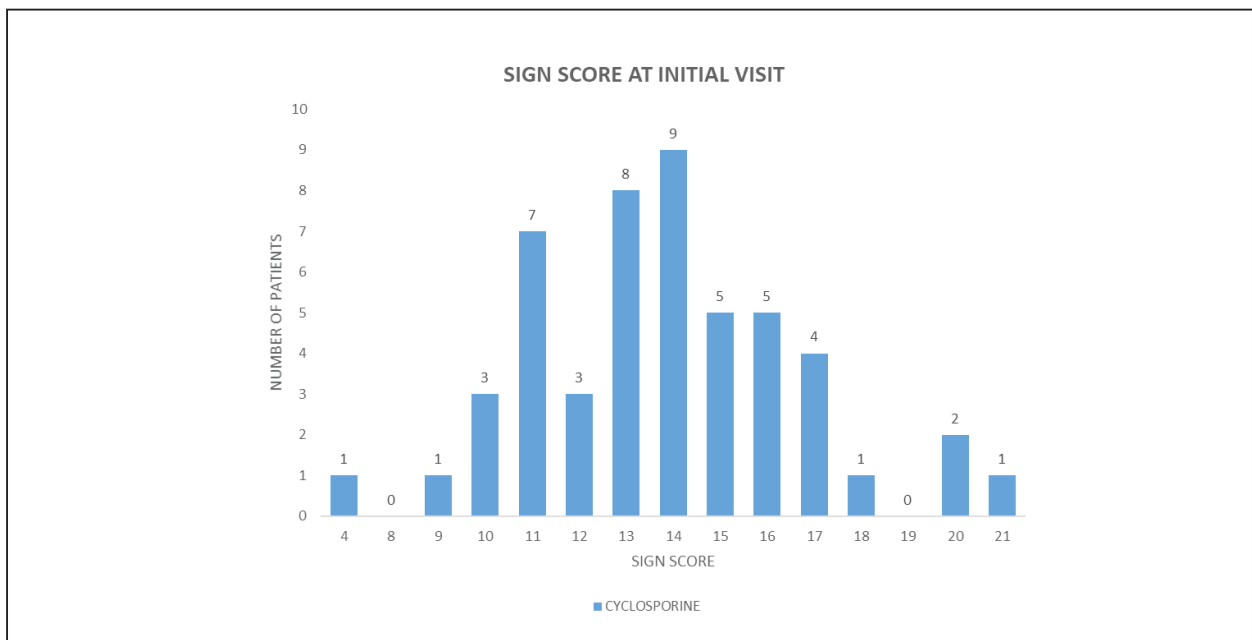
Sign score/Sign	0	1	2	3
Limbal hypertrophy	No	One quadrant	Two quadrants	Three or more
Bulbar Conjunctival Hyperemia	Absent	Mild	Moderate	Severe
Tarsal Conjunctival papillary hypertrophy	No	Mild	Moderate (edema of palpebral conjunctiva with hazy view of deep tarsal vessels)	Severe, obscuring visualization of deep tarsal vessels
Tranta's dots	No	1-2 dots	3-4 dots	More than 4 dots
Keratitis(Superficial epithelial keratitis, punctate staining of the cornea with fluorescein, erosions, ulcer)	No	One quadrant	Two quadrants, macro erosion	Three or more quadrants, vernal ulcer
Neovascularization of cornea	No new vessel formation	Neovascularization in one quadrant of cornea	Neovascularization in two quadrants of cornea	Neovascularization in 3 or more quadrants of cornea
Cicatrizing conjunctivitis (superficial scarring of the conjunctiva)	No	Presence of subepithelial fibrosis	Presence of fornix foreshortening	Symblepharon formation
Blepharitis	No	Mild redness and edema of the eyelid with meibomian gland dysfunction	Moderate inflammation with hyperemia, scales and scurf of eyelid skin	Severe inflammation, with cracks in the eyelid skin, loss of eyelashes, and lid edema

At the final follow up at three months, the final median of mean symptom score was 0.4 (range 0-1) which was still a statistically significant improvement (p value 0.000) as compared

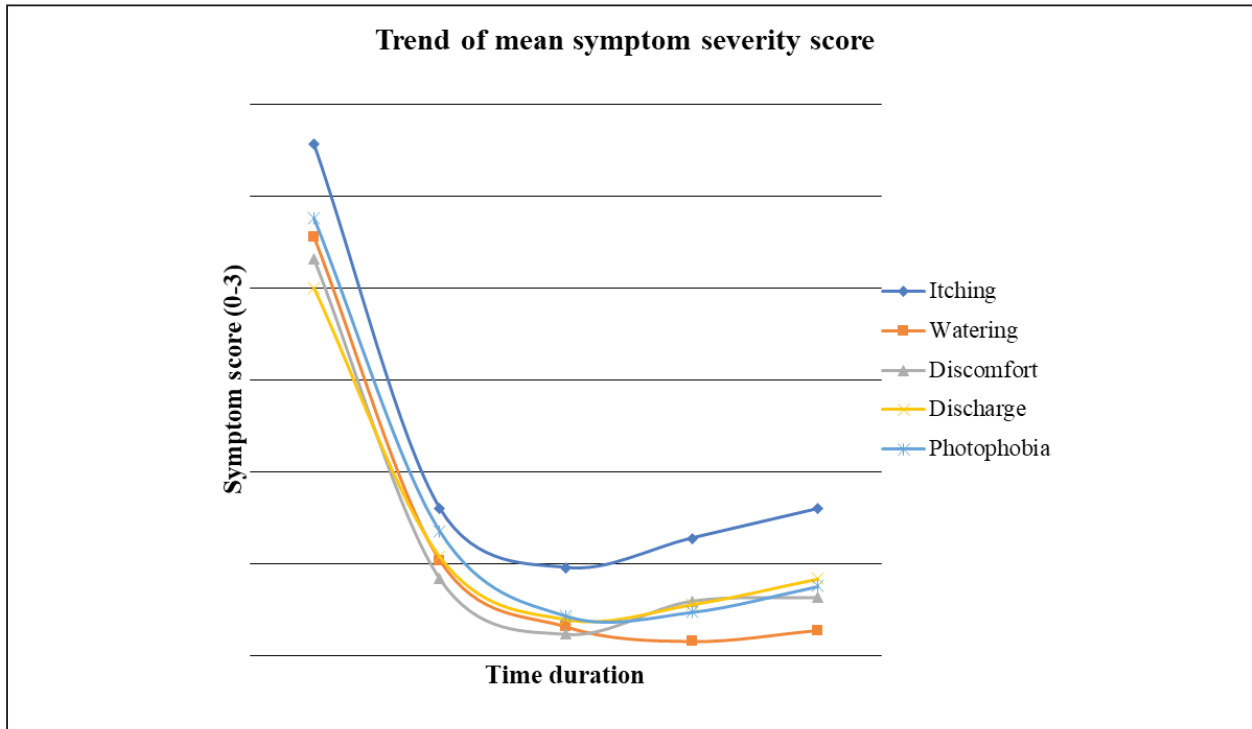
to the median of mean of 2.4 at presentation. The median of mean of sign score at three months was 0.375 (range 0-0.75) which was also a statistically significant improvement (p value 0.000) as compared to that at presentation.



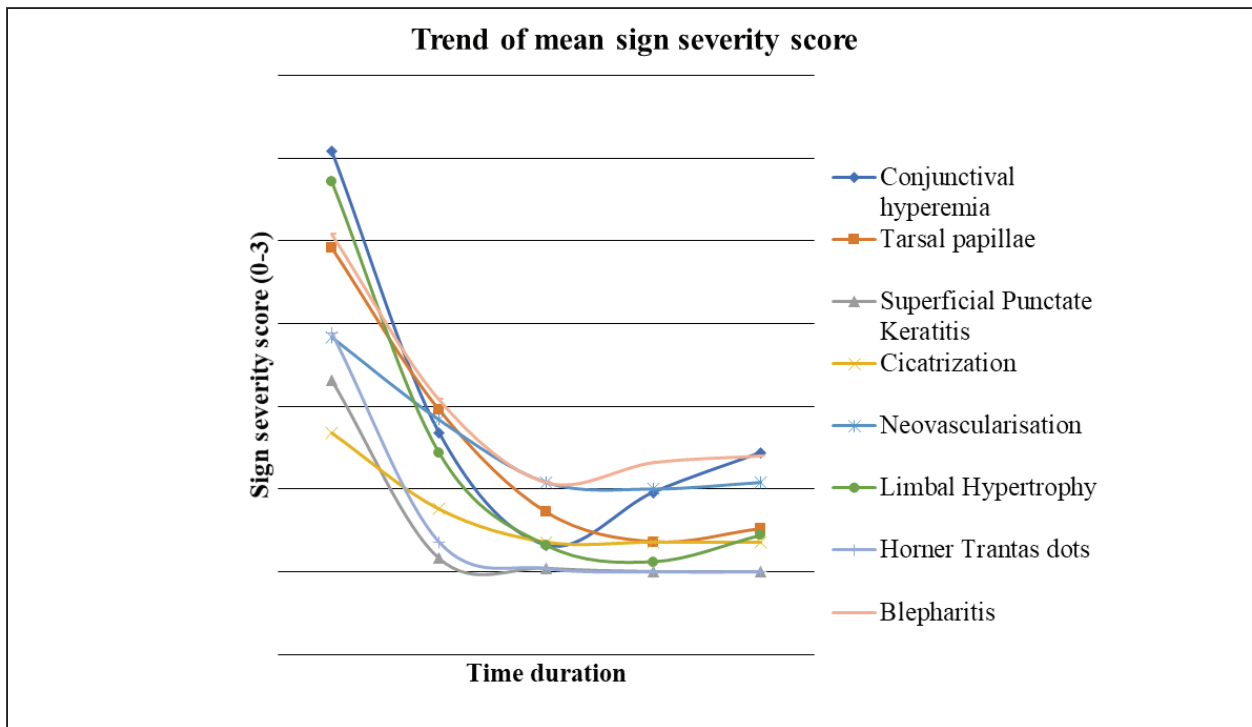
**Figure 1:** Symptom score at presentation



**Figure 2:** Sign score at presentation



**Figure 3:** Trend of mean symptom severity score



**Figure 4:** Trend of mean sign severity score

## Discussion

Topical steroids have so far been the most effective medication for the control of signs and symptoms of VKC. However alternative therapy needs to be strongly considered due to the many unwanted side effects of steroids including cataract and steroid induced glaucoma. This study attempts to assess the effectiveness of an immunomodulator, cyclosporine, in the treatment of VKC.

This study showed a beneficial effect of cyclosporine 0.05% eye drops starting from the first follow up at two weeks. This concurs with the previous study by BenEzra (1986) who used 2% cyclosporine in a similar dosage regimen in 12 children. In that study, the beneficial effects of therapy began from the third day of therapy. Only one patient showed no benefit of therapy. Seven children were completely symptom free at six weeks of follow up (Ben Ezra, 1986). Similarly, another study by Gupta and Sahu (2010), using 2% cyclosporine in olive oil found marked reduction in symptoms (91%) starting from the first week of therapy. They compared the effects with plain olive oil (placebo) and found the difference to be statistically significant.

This study showed reduction in signs (from 2.4 to 0.6 median of mean score) and symptoms (from median of mean score of 1.75 to 0.625 mean) at two weeks follow up. This improvement was maintained at one month follow up with a median of mean symptom score of 0.2 and 0.25 sign score.

In this study, after two months too, the improvement was maintained. The median of mean symptom score was only 0.2 compared to the score at presentation (2.4) and the difference was statistically significant ( $p=0.000$ ). The improvement in median of mean sign score was from 1.75 to 0.25 at this time frame. All the individual symptom scores and sign scores improved consistently. After three months also,

the improvement was maintained. There was a total improvement of 2 points in median of mean symptom score (2.4-0.4) as compared to the median of mean symptom score at presentation ( $p$  value-0.000). The improvement in median of mean sign score was 1.375 (1.75 to 0.375). All individual symptoms and signs showed good improvement.

A study by Ozcan et al (2007) in which topical cyclosporine 0.05% was used for steroid sparing purposes, demonstrated significant beneficial effect of topical cyclosporine to the extent that the steroid was tapered and later stopped altogether. The study even reported healing of the shield ulcer present in one case at one month of initiation of therapy with cyclosporine. There was a reduction in the total sign score from  $7.3\pm 1.8$  to  $2.4\pm 1.3$  after six months of initiation of therapy. The study reported significant improvement in upper tarsal conjunctival papillae with regression of limbal vascularisation.

A study by De Smedt et al (2012) compared topical cyclosporine 2% with 0.1% Dexamethasone in two treatment groups among 366 patients in Rwanda previously. At the end of the 2-week time frame, dexamethasone showed better improvement (46.2% reduction) in signs and symptoms than cyclosporine (41.2% reduction) and the difference was statistically significant ( $p=0.009$ ). However, at four weeks' time frame, the effects were comparable with reduction in mean composite scores by 47.5% and 49.9% for the cyclosporine and dexamethasone groups respectively, the difference between groups no longer being significant ( $p=0.20$ ). This study concluded that both medications have similar reduction in signs of disease but dexamethasone, being a potent steroid, had an earlier effect.

Another study by Oray & Toker (2013) demonstrated the effect of topical cyclosporine 0.05% in decreasing tear film levels of cytokines,

precisely IL-2, IL-4, IL-5, IL-17 as well as TNF  $\alpha$  and IFN  $\gamma$ . The receptor for IL-2, sIL-2R, was also down regulated. These cytokines had been shown to be significantly increased in the tear films of patients with VKC (21 patients) in comparison with normal controls (15 patients). The dosage schedule included a monotherapy of cyclosporine 0.05% eye drops, one drop six times a day for two weeks, followed by one drop four times a day for the rest of the duration of the study (3 months). After the initial one month of therapy itself, there was a statistically significant reduction in the symptoms of itching, watery discharge, mucus hypersecretion, photophobia as well as discomfort. This benefit persisted till the end of the study period of three months. There was also a concomitant reduction in the signs of the disease which was statistically significant for limbal thickening and limbal hyperemia at the first month of therapy itself. There was an added significant reduction in punctate epitheliopathy and neovascularization at three months. However, the reduction in Horner Trantas dots and tarsal papillary hypertrophy were not statistically significant at both time frames. The overall reduction in symptoms and signs were significant at both the one month follow up and three month follow up following initiation of therapy.

However, a study by Daniell et al (2006) comparing the steroid sparing effect of topical cyclosporine 0.05% against placebo failed to demonstrate a statistically significant beneficial effect of cyclosporine as a steroid sparing drug. In the double blind study, four times a day dosage schedule was used and patients with atopic and vernal keratoconjunctivitis were included. Of the symptoms, the patients only reported a significant reduction in redness of the eyes ( $p=0.01$ ) and itching ( $p=0.04$ ) whereas patients in the placebo group had significant reduction in mucoid discharge ( $p=0.01$ ) and redness ( $p=0.01$ ). There was also no significant

reduction in the final clinical sign score ( $p=0.6$ ). However, individual clinical signs did achieve a significant reduction. These signs were lid margin thickening ( $p=0.02$ ), inferior and superior conjunctival hyperemia ( $p=0.01$ ), inferior conjunctival papillae ( $p=0.03$ ) and corneal tear film deficiency ( $p=0.05$ ). The study was reported to have 80% power to detect a 0.045 difference in the steroid sparing effect of cyclosporine 0.05% as compared to placebo.

### Conclusion

Thus, cyclosporine 0.05% was shown to be of benefit in the treatment of vernal keratoconjunctivitis in terms of both signs and symptoms. The minimal side effect profile, with only mild stinging sensation to the patient and low dosage schedule for prevention of seasonal exacerbation further aids its advantage profile.

### Limitations of the study

Dosage regimen of topical cyclosporine may need to be altered depending upon the severity of disease. Loading a dose of only four times a day may have masked further additional benefit of the drug in the disease. Loading a dose of six times a day for two weeks may add further benefit.

Further studies may be needed for stratification of severity of disease and cyclosporine role in terms of individual grades of severity.

The use of cold compresses, dark tinted glasses for allergen avoidance and limitation of outdoor activity may have had added benefit to the study and further biased the study results.

There was only a verbal account of the compliance of the patients to the study protocol. The exact results may have had individual patient compliance factors involved.

### Acknowledgement

Sincere gratitude to Mr. Manish Poudel, statistician, Tilganga Institute of Ophthalmology for computing statistics in this data set.



## References

Akpek EK, Dart JK, Watson S et al (2004). A Randomized Trial of Topical Cyclosporine 0.05% in Topical Steroid-Resistant Atopic Keratoconjunctivitis. *Ophthalmol*; 111: 476-82.

Arbab TM, Mirza MA (2011). Topical Use of Cyclosporine in the Treatment of Vernal Keratoconjunctivitis. *Pak J Ophthalmol*; 27(3):121-7.

Arlt F. Physiologisch und pathologisch anatomische Bemerkungen über die Bindehaut des Auges (1846). *Prager Vierteljahrschrift*; 4:73.

Ben Ezra D, Pe'er J, Brodsky M, Cohen E (1986). Cyclosporine eye drops for the treatment of severe vernal keratoconjunctivitis. *Am J Ophthalmol*; 101:278-82.

Ben Ezra D (1993). The role of cyclosporin eye drops in ocular inflammatory diseases. *Ocular Immunology and Inflammation*; 1 (112):159-62.

Bonini S, Sacchetti M, Mantelli F, Lambiase A (2007). Clinical grading of vernal keratoconjunctivitis. *Curr Opin Allergy Clin Immunol*; 7:436-41.

Buckley RJ (1988). Vernal Keratoconjunctivitis. *International Ophthalmology Clinics*; 28(4):303-8.

Daniell M, Constantinou M, Vu H T, Taylor H R (2006). Randomised controlled trial of topical cyclosporin A in steroid dependent allergic conjunctivitis. *Br J Ophthalmol*; 90: 461-4.

De Smedt S, Nkurikiye J, Fonteyne Yet al (2012). Topical cyclosporin in the treatment of vernal keratoconjunctivitis in Rwanda, Central Africa: a prospective, randomised, double-masked, controlled clinical trial. *Br J Ophthalmol*; 96: 323-8.

Gupta V, Sahu PK (2001). Topical Cyclosporin A in the management of vernal keratoconjunctivitis. *Eye*; 15: 39-41.

Kashani S, Mearza AA (2008). Uses and safety profile of cyclosporine in ophthalmology: Expert Opin. *Drug Saf*; 7(1):79-89.

Leonardi A (2002). Vernal keratoconjunctivitis: pathogenesis and treatment. *Progress in Retinal and Eye Research*; 21: 319-39.

Leonardi A, Busca F, Motterle L, Cavazzeran F, Fregona IA, Plebani M, Secchi AG (2006). Case series of 406 vernal keratoconjunctivitis patients: a demographic and Epidemiological study. *Acta Ophthalmol. Scand*; 84: 406-10.

Oray M, Toker E (2013). Tear Cytokine Levels in Vernal Keratoconjunctivitis: The Effect of Topical 0.05% Cyclosporine A Therapy. *Cornea*; 32(8):1149-56.

Ozcan A, Ersoz T.R, Dulger E (2007). Management of Severe Allergic Conjunctivitis with Topical Cyclosporin A 0.05% Eyedrops. *Cornea*; 26(9):1035-8.

Smedt SD, Wildner G, Kestelyn P (2012). Vernal Keratoconjunctivitis: an update. *Br J Ophthalmol*; 97(1):9-14.