

## Case Report

# A Case of Descemet's Membrane Endothelial Keratoplasty in a failed Penetrating Keratoplasty

Sanjay Kumar Singh<sup>1</sup>, Reena Yadav<sup>1</sup>, Ashmita Sharma<sup>1</sup>

<sup>1</sup>Biratnagar Eye Hospital, EREC-P

### Abstract

**Background:** Descemet's membrane endothelial keratoplasty (DMEK) is an evolving option for failed penetrating keratoplasty (PK) as it has shown promising results compared to repeat PK. **Case description:** A 22 years young gentleman presented with gradual diminution of vision in the left eye (LE) for six months following therapeutic PK for a perforated fungal corneal ulcer. His best spectacle corrected visual acuity (BSCVA) was 6/60 in LE. Slit-lamp examination of LE revealed circumcorneal congestion with full thickness corneal graft with micro and macrobullae, diffuse stromal edema, DM folds and seven well-buried sutures. Intraocular pressure was 20 mmHg in the right eye whereas it could not be assessed in the left eye. The diagnosis of LE failed PK was made and the patient underwent DMEK. At four months postoperative follow up visit, BSCVA improved to 6/9. This is the first reported case of DMEK after a failed PK in a young patient from Nepal which was successfully treated without any complications. **Conclusion:** DMEK has a higher potential for better visual rehabilitation compared to DSEK and PK. It has also proved its efficacy in the treatment of endothelial graft failure following PK as it is a less invasive procedure.

**Key words:** Descemet membrane endothelial keratoplasty, Penetrating keratoplasty

### Introduction

Despite many advances in corneal transplantation surgery, graft failure is one of the leading indications for penetrating keratoplasty (Liu E et al, 1996; Maeno E et al, 2000). Recent practice has introduced Endothelial keratoplasty (EK) used as an alternative to repeat full-thickness transplantation (Ang M et al, 2014; Mitry D et al, 2014). Anshu A and

colleagues (2011) suggested that EK can be chosen when the corneal stroma and epithelium of the previous penetrating keratoplasty (PK) are still healthy, but when endothelial cell loss or failure has led to the loss of vision. As the rejection risk of EK over PK is comparatively lesser, recent practice has changed to lamellar keratoplasty in cases of failed PK (Anshu A et al, 2012; Ezon I et al, 2013).

### Case Description

A 22-years gentleman presented in Cornea Outpatient Department of Biratnagar Eye Hospital with gradual diminution of vision in left eye for last six months. Unaided visual acuity was 1/60 in the left eye (LE) and 6/6 in the right eye. The vision in the left eye

**Conflicts of Interest:** Nil

**Financial Interest:** Nil

Received: 13/02/18 Accepted: 22/04/18

**Corresponding author**

Dr Reena Yadav

MBBS, MD, Cornea (BEH) and Anterior Segment fellowship

(SCEH), EREC-P

E-mail: [reenapinl@gmail.com](mailto:reenapinl@gmail.com)

improved to 6/60 with -1.00 DC x 135°. Slit-lamp examination revealed diffuse and circumcorneal congestion with full thickness corneal graft. There were 7 well-buried sutures in situ. Micro and macro bullae were present on the donor cornea with diffuse stromal edema, DM folds and endothelial dusting. Right eye examination did not reveal any abnormality. Fundus examination was normal in both eyes. The intraocular pressure on Goldmann applanation tonometry was 20 mmHg in right eye whereas it could not be assessed in the left eye. He had undergone uneventful therapeutic penetrating keratoplasty (PK) in the left eye with donor corneal size of 8.25mm for perforated fungal corneal ulcer six months back with an unsatisfactory postoperative gain of vision. The diagnosis of left eye failed PK was made and the patient underwent DMEK.

**Donor preparation:** Donor Descemet's membrane was prepared just before the operation. A gentle trephination with 9.5 mm trephine was done in donor corneoscleral button. This was then immersed in Ringer lactate solution. With the help of scorer Descemet's membrane was separated at edges throughout 360° and was gently pulled to separate it about 70% of the area from the stroma. One "S" stamp was applied on the stromal surface and then, it was punched with 8 mm corneal trephine and separated gently with suture tying forceps till completion. This membrane spontaneously rolls immediately, was stained with trypan blue 0.06% (Auroblue) and loaded in a glass pipette injector (Figure 1).

### Operative procedure

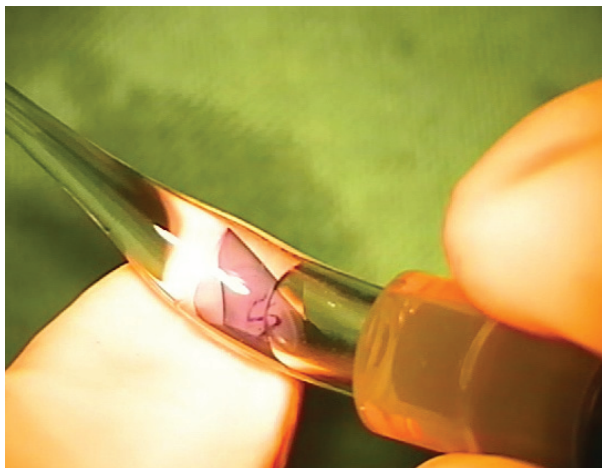
Surgery was performed under peribulbar anesthesia (3-4 ml of lignocaine Hydrochloride 2% with adrenaline 1:200,000 was mixed with hyaluronidase) followed by an ocular massage for about ten minutes.

Two side ports were made at 6 and 12 o'clock position and a temporal corneal incision of

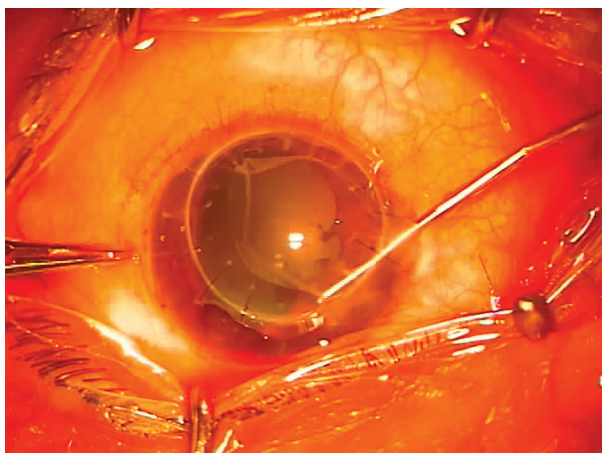
2.5 mm size were created with a keratome. Anterior chamber (AC) was filled with cohesive viscoelastic (sodium hyaluronate). A descematorrhexis of 8 mm in size was made with a reverse Sinsky hook (Figure 2) and recipient's Descemet's membrane along with cohesive viscoelastic was aspirated with the bimanual cannula. Donor Descemet membrane was injected gently into AC. AC was shallowed by ejecting some fluid out through the side port. Donor graft was unrolled with no touch two cannula techniques by tapping over the host cornea and making sure the stroma side faces towards the recipient stroma. Once fully unrolled and centered, the air was injected beneath donor Descemet's membrane to attach to the host stroma. The anterior chamber was completely filled with air and left in AC for about 3 hours. After 3 hours 50% of the air was replaced with ringer lactate solution under topical anesthesia in operation theatre.

The patient was prescribed topical prednisolone 1% four-times-a-day and tapered at 1-week interval along with topical antibiotics and tear substitute four times a day for two weeks. At one month follow-up, visual acuity improved to 6/12 with -1.25 DC x 90°. Micro and macro bullae disappeared and stroma was clear with the absence of DM folds. DMEK graft was clear and well attached to overlying host PK graft. At two months' follow-up, there was a tuft of new vessels at the graft-host junction at 10-12 o'clock position. There was loose suture at 1 and 2 o'clock along with broken suture at 9 o'clock position. Graft was clear and well attached. Two loose sutures along with broken suture was removed and subconjunctival bevacizumab (Avastin) 2.5mg/0.1ml was given. Patient was discharged with topical prednisolone 1% in tapering dose along with topical antibiotics, antiglaucoma medications for 2 weeks. The patient is under regular follow-up. At four months follow-up, best corrected visual acuity recorded was 6/9. DMEK graft

was clear and well attached to overlying host PK graft (Figure 3). No Vascularization noted. Patient was prescribed glass and was asked to follow up after three months.



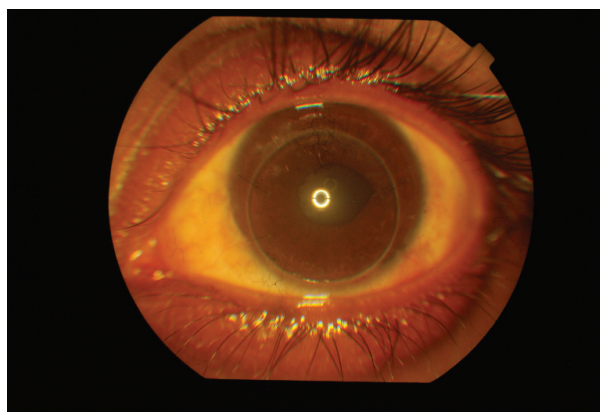
**Figure 1:** Prepared donor graft stained with trypan blue and S mark, ready for insertion in a glass injector



**Figure 2:** Descemetorrhexis being performed in recipient cornea

### Discussion

Corneal transplantation is one of the most successful organ transplantation with penetrating keratoplasty being the most widely performed keratoplasty. Yalniz-Akkaya Z et al (2009) and MacEwen CJ et al (1988) proposed that repeat PK for failed graft has poor prognosis in terms of visual outcome as well as graft survival. Over the years there has been



**Figure 3:** Postoperative period (at 4 month) showing clear PK and DMEK graft with clear demarcation between host and donor cornea, two suture in situ and peaked pupil temporally at 3 o'clock.

rapid advancement in the techniques of cornea transplantation. EK has evolved as a promising technique in dealing with the posterior corneal surface pathologies. There are various advantages over repeat PK such as avoidance of full-thickness incisions, multiple sutures on the cornea, induction of ocular surface complications from a totally anesthetic anterior corneal surface of the graft, risk of expulsive bleeding or the development of phthisis bulbi (Anshu A et al, 2013, Heinzelmann S et al, 2017), DJ C et al (2007), Price FW Jr et al (2006 and 2011) have shown promising results for DSEK in dealing with posterior corneal surface pathologies and in failing donor endothelium cases. In recent years the newer technique DMEK has outraged DSEK because there is no stromal interface and significantly less posterior surface aberrations leading to better results and faster visual recovery (Anshu et al 2013, Price MO et al 2013). Heinzelmann S and colleagues (2017) suggested that a thinner graft in DMEK has a lower rejection rate than DSAEK for failed PK graft. In a study conducted by Schlo GLA and friends (2016), the rejection episode was 15 times lesser than DSEK and 20 times lesser than PK. In the same study, the cumulative probability of 5-year graft

survival was 95%. Anshu et al (2012) proposed that this low rejection rate may be due to a reduction in antigenic load in the absence of donor epithelium, stroma, and sutures.

Very recently, Melles GR (2017) histologically examined the eyes with DMEK after PK and found “near-normal corneal anatomy” at the interface between the donor Descemet and the host posterior stroma similar to primary DMEK eyes.

Melles GRJ and colleagues (2015) have also proved the efficacy of DMEK in failed PK graft in the presence of a long Glaucoma Drainage Device tube. In our case, there was persistent corneal edema after primary PK and was not responding to consecutive four months of medical management but the cornea was clear after DMEK. Our patient achieved BSCVA of 6/9 at four-month follow-up. All the literature have emphasized on the importance of performing the DMEK by the experienced surgeon for the better visual outcome as it is more challenging technically than other as the adherence property of DM is less than stroma (Anshu A et al, 2013; Heinzelmann S et al, 2017; Gundlach E et al 2015).

In Nepal, though PK was started about five decades ago but increased number of keratoplasty surgeries were performed after the establishment of Nepal Eye Bank. Despite the availability of increased donor tissues there is a long waiting list for patients needing corneal tissues. We believe that increasing experience in DMEK surgeries will increase the donor pool of available tissues as the remaining donor stromal tissues can be used for deep anterior lamellar corneal surgeries or in other ophthalmic surgeries.

### Conclusion

DMEK has a higher potential for better visual rehabilitation compared to DSEK and PK. It has also proved its efficacy in the treatment of endothelial graft failure following PK as it is a

less invasive procedure.

### References

Ang M, Ho H, Wong C, Htoon HM, Mehta JS, Tan D (2014). Endothelial keratoplasty after failed penetrating keratoplasty: an alternative to repeat penetrating keratoplasty. *Am J Ophthalmol*; 158:1221–7.

Anshu A, Price MO, Price FWJ (2011). Descemet’s stripping endothelial keratoplasty under failed penetrating keratoplasty: visual rehabilitation and graft survival rate. *Ophthalmology*; 118:2155–60.

Anshu A, Price MO, Price FW Jr (2012). Risk of corneal transplant rejection significantly reduced with Descemet’s membrane endothelial keratoplasty. *Ophthalmology*; 119(3):536–540.

Anshu A, Price MO, Price FW (2013). Descemet Membrane Endothelial Keratoplasty and Hybrid Techniques for Managing Failed Penetrating Grafts. *Cornea*; 32:1–4.

DJ C, SB K (2007). Descemet stripping and automated endothelial keratoplasty (DSAEK) in eyes with failed penetrating keratoplasty. *Cornea*; 26:692–696.

Ezon I, Shih CY, Rosen LM, Suthar T, Udell IJ (2013). Immunologic graft rejection in Descemet’s stripping endothelial keratoplasty and penetrating keratoplasty for endothelial disease. *Ophthalmology*; 120(7):1360–1365.

Gerrit R.J. Melles, Itay Lavy, Vasilios S. Liarakos, Robert M. Verdijk, Jack Parker, Thomas M. Muller, Marieke Bruinsma, Perry S. Binder (2017). Outcome and Histopathology of Secondary Penetrating Keratoplasty Graft Failure Managed by Descemet Membrane Endothelial Keratoplasty. *Cornea*; 0:1–8.

Gerrit R. J. Melles, Vasilios S. Liarakos, Maria Satue, Eitan Livny, Korine van Dijk, Lisanne Ham, Lamis Baydoun, Isabel Dapena (2015). Descemet Membrane Endothelial Keratoplasty for a Decompensated Penetrating



Keratoplasty Graft in the Presence of a Long Glaucoma Tube. *Cornea*; 34: 1613-1616.

Gundlach E, B. Maier A-K, Riechardt A.I, Brockmann T, Bertelmann E, Jousen A, Torun N (2015). Descemet Membrane Endothelial Keratoplasty as a Secondary Approach after Failure of Penetrating Keratoplasty. *Exp Clin Transplant*; 13:350–354.

Heinzelmann S, Bohringer D, Eberwein P, Lapp P, Reinhard T, Maier P (2017). Descemet membrane endothelial keratoplasty for graft failure following penetrating keratoplasty. *Graefes Arch Clin Exp Ophthalmol*; 255(5):979-985.

Liu E, Slomovic AR (1997). Indications for penetrating keratoplasty in Canada, 1986–1995. *Cornea*; 16:414–419.

MacEwen CJ, Khan ZU, Anderson E, MacEwen CG (1988). Corneal re-graft: indications and outcomes. *Ophthalmic Surg*; 19:706–712.

Maeno A, Naor J, Lee HM, Hunter WS, Rootman DS (2000). Three decades of corneal transplantation; indications and patient's characteristics. *Cornea*; 19:7–11.

Mitry D, Bhogal M, Patel AK, Lee BS, Chai SM, Price MO, Price FW Jr, Jun

AS, Aldave AJ, Mehta JS, Busin M, Allan BD (2014). Descemet stripping automated endothelial keratoplasty after failed penetrating keratoplasty: survival, rejection risk, and visual outcome. *JAMA Ophthalmol*; 132:742–9.

Price FW Jr, Price MO (2006). Endothelial keratoplasty to restore clarity to a failed penetrating graft. *Cornea*; 5:895–899.

Price FW Jr, Price MO, Arundhati A (2011). Descemet stripping automated endothelial keratoplasty under failed penetrating keratoplasty: How to avoid complications.

*Am J Ophthalmol*; 151:187–188.

Price M O and Price F.W Jr. (2013). Descemet's membrane endothelial keratoplasty surgery: update on the evidence and hurdles to acceptance. *Curr Opin Ophthalmol*; 24:329–335.

Schlo GL A, Tourtas T, Krause F.E, and Weller J.M. (2016). Long-term Clinical Outcome after Descemet Membrane Endothelial Keratoplasty. *Am J Ophthalmol*; 169:218–226.

Yalniz-Akkaya Z, Nurozler AB, Ylidiz EH, Onat M, Budak K, Duman S (2009). Repeat penetrating keratoplasty: indications and prognosis, 1995–2005. *Eur J Ophthalmol*; 19:362–368.