

Original Article

Refractive and Visual Outcomes after Scleral Fixated Intraocular Lens Implantation in Children with Ectopia Lentis

Regina Lalramhluni¹, Soveeta Rath², Ankita Shrivastav³, Prem Kumar Singh⁴, Rahul Mayor⁵,
Shalini Singh⁶, Manisha Agarwal⁷, Suma Ganesh⁸, Chandra Gurung⁹

¹⁻⁸ Dr. Shroff's Charity Eye Hospital, New Delhi, India

⁹ Nepal Eye Hospital, Kathmandu, Nepal

Abstract

Introduction: This study was conducted to report the refractive and visual outcome after Scleral Fixated Intraocular Lens (SFIOL) implantation in children with non-traumatic ectopia lentis.

Methods: Retrospective review of the medical records of 25 eyes of 15 patients who underwent SFIOL implantation in children with non-traumatic ectopia lentis.

Results: The mean best corrected visual acuity (BCVA) before SFIOL implantation was 1.07 ± 0.9 logMar units [median: 0.9, Interquartile range (IQR): 0.415 to 1.555] which improved to 0.41 ± 0.33 logMar units (median: 0.22, IQR: 0.180 to 1.555) at two months postoperative follow up. In phakic group, the mean spherical refraction preoperatively was -12.04 ± 7.82 DS (dioptr sphere) (IQR: +16 to -5.875) and postoperatively was $+0.93 \pm 2.67$ DS (IQR: -0.375 to +2). In aphakic group, the mean spherical refraction preoperatively was $+12.22 \pm 2.05$ DS and postoperatively was $+1.2 \pm 1.9$ DS. The mean total astigmatism preoperatively was -6.44 ± 4.95 DC (dioptr cylinder) (median: 6, IQR: -10.50 to +2) and postoperatively was -1.47 ± 0.98 DC (median: -1.5, IQR: -2 to - 0.625). The mean IOL induced astigmatism was -1.01 ± 0.95 DC (median -0.75, IQR: -1.33 to - 0.25). The spherical refractive equivalent was within 2 Diopter (D) of the target refraction calculated preoperatively in 20 eyes and in five eyes it was more than 2 D.

Conclusion: SFIOL implantation is associated with good visual outcome with a significant improvement in the refractive error. However, a longer follow up is required to assess the change of refraction and the stability of the SFIOL.

Key words: Astigmatism, Ectopia lentis, Scleral fixated intraocular lens, Visual outcome.

Key message: Scleral fixated intraocular lens implantation in paediatric eyes with non-traumatic ectopia lentis has good visual and refractive outcomes.

Financial Interest: Nil

Conflict of Interest: Nil

Received: 06.01.2019

Accepted: 10.11.2019

Corresponding author

Dr. Soveeta Rath

Dr. Shroffs Charity Eye hospital

Tel.: +91-9437400405

Fax: +91 11 43524400

E-mail: soveetarath1@gmail.com

Introduction

Ectopia lentis is defined as malposition of crystalline lens of the eye.(Jarrett, 1967) If there is no trauma, presence of ectopia lentis may be due to concomitant hereditary systemic disease or other associated ocular disorders.



(Streeten, 2000). It may present at any age. Children with ectopia lentis may present with marked visual disturbance secondary to astigmatism or myopia, poor near vision and loss of accommodation which may vary with the degree of lens displacement. Optical correction of irregular astigmatism and higher order aberrations is difficult leading to suboptimal visual outcomes and amblyopia. Lensectomy is indicated in these children, however rehabilitation is difficult due to poor compliance with aphakic glass and contact lenses. Several studies have shown Scleral Fixated Intraocular Lens (SFIOL) implantation as a safe and effective procedure in the pediatric age group for the treatment of ectopia lentis. (Kumar et al, 1999; Mittelviefhaus et al, 2000; Bardorf et al, 2004; Asadi and Kheirkhah, 2008; Hyun et al, 2009; Hsu et al, 2012; Bhutto et al, 2013). This study evaluates the refractive and visual outcomes of children with ectopia lentis who underwent lensectomy and SFIOL implantation.

Methodology

This retrospective study was approved by the institute's review board and the procedures conformed to the tenets of the Declaration of Helsinki. Medical records of 25 eyes of 15 children (3 to 18 years) with non-traumatic ectopia lentis who underwent SFIOL implantation between 2008 to 2017 at a tertiary eye care institute in North India were retrospectively evaluated. SFIOL implantation was either done as a primary or secondary procedure. A primary procedure was defined when lens aspiration and SFIOL were done in the same sitting and secondary if SFIOL implantation was performed later as a staged procedure after six weeks. In cases needing bilateral surgery, a 4-6 week interval was maintained.

The indication for surgery was lens subluxation of grade 3 and grade 4 according to the lens subluxation grading system. (Waiswol and

Kasahara, 2009). The demographic profile of all the children was noted and other parameters like age at the time of surgery, preoperative refraction, spherical equivalent of pre-operative best corrected visual acuity (BCVA), axial length, keratometry readings, measurement of intraocular pressure (IOP), slit-lamp examination and funduscopy were recorded. All patients underwent a complete systemic evaluation by an internist to rule out other comorbidities.

Based on the refraction, 25 eyes were divided into two groups, aphakic and phakic groups depending on whether a portion of the lens was within the visual axis during refraction. Spherical equivalent was calculated by adding half of the cylindrical power to the spherical power. Visual acuity was examined by Snellen and Allens visual acuity chart. For the purpose of analysis the visual acuity was converted to logMAR. The SFIOL power was calculated using the SRK II formula using A scan biometry (Alcon Ocuscan RXP). In those children where the pre-operative biometry was not possible, intraocular SFIOL power calculation was done with A-scan biometry and hand held auto keratometry (Nidek KM 500) under general anaesthesia. The post-operative refraction was targeted for emmetropia or undercorrection according to the age of the child. (Enyedi LB et al. 1998). The post-operative data recorded included BCVA, refraction and the final glass prescription at two months follow up. An increase in the BCVA was defined as a change of greater than or equal to two lines. On refraction the spherical equivalent obtained post-operatively was compared with the target refraction calculated preoperatively. All eyes underwent a keratometry at two months follow up and if there was presence of significant corneal astigmatism, removal of limbal sutures was done. Intraocular pressure and any other ocular complications were noted. Part time occlusion therapy was advocated to all children with amblyopia. A home based calendar was

distributed to all parents, which was assessed at every visit to monitor compliance.

Surgical procedure: In all cases an infusion cannula was fixed and a pars plana anterior vitrectomy was performed. The SFIOL was a polymethylmethacrylate (PMMA) lens of 6.5mm diameter. It is a single piece lens with two haptics, both bearing eyelets 180 degrees apart for ease of maneuvering the lens. Two sclera flaps were made at 2 and 8 o'clock positions and an ab-externo technique was used to introduce the 10-0 prolene suture on straight needles 1.5 mm posterior to the limbus under each scleral flap and brought out through the limbal incision using the rail road technique. The suture was then looped to the eyelet on the SFIOL haptic and retrieved back under the scleral flap on the same side. The same procedure was repeated on the other side however the passing of the suture through the eyelet of the IOL was upside down on one side and reverse on the other side to avoid the tilting of the lens and postoperative astigmatism. The SFIOL was then slipped in through the limbal section into the ciliary sulcus and the prolene sutures were then tightened under the sclera flaps after the limbal section was sutured with interrupted 10-0 monofilament nylon sutures. The scleral flaps were then sutured to avoid exposure of the prolene sutures. A four point fixation of the SFIOL was thus achieved. Conjunctiva was closed using 7-0 vicryl.

Statistical analysis: Categorical variables were presented in number and percentage (%) and continuous variables were presented as mean \pm standard deviation (SD) or median. Normality of data was tested by Kolmogorov-Smirnov test. If the normality was rejected then non parametric test was used. Quantitative variables were compared using paired t-test/Wilcoxon Test (when the data sets were not normally distributed) across follow up. A p value of <0.05 was considered statistically significant. The data was entered in MS EXCEL spreadsheet

and analysis was done using Statistical Package for Social Sciences (SPSS) version 21.0.

Results

Twenty-five eyes of 15 patients were included in this study. The baseline demographic details and clinical characteristics are described (Table 1). The mean follow up was 30.36 months (range 2 to 96 months). Six eyes were associated with Marfan's syndrome clinically and 4 eyes had microspherophakia. None of the eyes had microcornea

Visual acuity:

Visual acuity was converted to logMAR units using conversion software between Snellen and logMAR acuity. The mean BCVA before SFIOL implantation was 1.07 ± 0.9 logMar units (median 0.9, IQR: 0.415 to 1.555) which improved to 0.41 ± 0.33 logMar units (median 0.22, IQR: 0.180 to 1.555) after two months of surgery (p-value 0.0001). Eighteen eyes showed improvement by two or more lines at two months post-operative follow up. The BCVA improved further in five eyes at the final follow up visit [Figure1].

Three eyes showed deterioration due to late post-operative complications in the form of retinal detachment, dislocated IOL and excessive tilting of the lens respectively.

Refractive outcomes:

The refractive outcomes were analyzed at two months postoperatively when spectacles were prescribed. Four eyes had dull glow on retinoscopy due to cataractous lens. These eyes were not associated with any metabolic syndrome neither were mentally challenged. In phakic group (n=11), the mean spherical refraction preoperatively was -12.04 ± 7.82 DS (median -8, IQR: -16 to 5.875) and postoperatively was $+0.93 \pm 2.67$ DS (median 1.25, IQR: -0.375 to 2). In aphakic group (n=10), the mean spherical refraction preoperatively was $+12.22 \pm 2.05$ DS (median

11.62, IQR: 10.50 to 14.50) and postoperatively was $+1.2 \pm 1.9$ DS (median 1, IQR: 0 to 3). The difference between the pre and the post-operative spherical refraction in both phakic and aphakic group was highly significant with a p value of 0.001 and <0.0001 respectively [Figure 2].

The mean total astigmatism preoperatively was -6.44 ± 4.95 DC (median 6, IQR: -10.50 to 2) and postoperatively was -1.47 ± 0.98 DC (median -1.5, IQR: -2 to - 0.625) with a statistically significant difference (p value 0.018) [Figure 3].

The mean pre-operative corneal astigmatism calculated by keratometry was -1.23 ± 0.89

DC (median -1, IQR: -2 to - 0.437) while mean post-operative corneal astigmatism was -1.11 ± 0.98 DC (median -0.75, IQR: -1.37 to - 0.5). The difference between the pre and post corneal astigmatism was not statistically significant (p value 0.56). The mean difference between total and mean corneal astigmatism (IOL induced astigmatism) was -1.01 ± 0.95 DC (median -0.75, IQR: -1.33 to - 0.25). Out of 25 eyes, only six eyes had high post-operative cylindrical value of more than 3 DC. The spherical refractive equivalent was within 1D of the target refraction calculated preoperatively in nine eyes. In 11 eyes it was between 1-2 D and in five eyes more than 2 D.

Table 1: Demographic and Clinical Characteristics

Age	Mean 8.75 years (range 3 to 18 years)	
Gender	Male	9 patients
	Female	6 patients
Laterality	Unilateral	5 patients
	Bilateral	10 patients
Procedure	Primary	19 eyes
	Secondary	6 eyes
Grade of Subluxation	Grade 3	19 eyes
	Grade 4	6 eyes
Mean pre-operative axial length	24.59 mm [†] (range 20.35 – 27.54)	
Mean SFIOL* power calculated	19.65 D [‡] (range 12.5 – 29)	
Mean SFIOL power implanted	19.24 D (range 10.5 – 27.5)	

SFIOL*: Scleral fixated intraocular lens, mm[†]: millimeter, D[‡]: Diopter

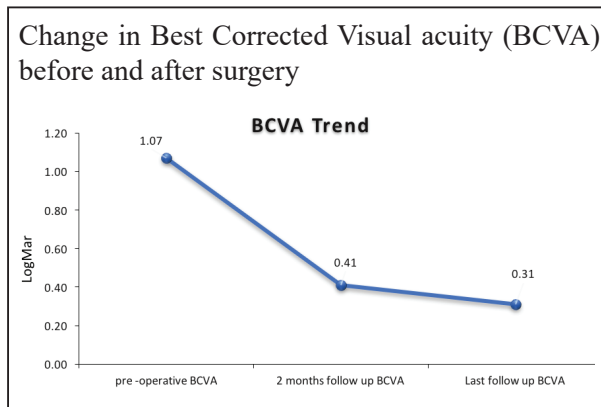


Figure 1: Line diagram showing trend of Best corrected visual acuity (BCVA) at pre-operative, second month and final post-operative follow up in children of ectopia lentis treated with implantation of SFIOL

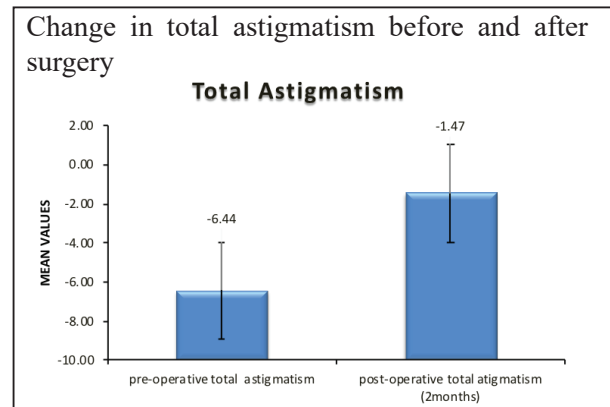


Figure 3: Bar graph showing difference between the mean values of total astigmatism at pre-operative and two months post-operative follow up

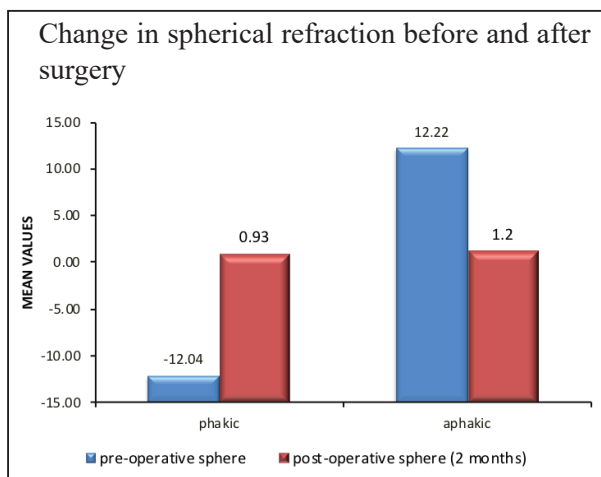


Figure 2: Bar graph showing difference between the mean values of spherical refraction at pre-operative and two months post-operative follow up

Discussion

The main aim of managing pediatric ectopia lentis is optimal visual restoration. Poor compliance with thick aphakic glasses and contact lenses precludes successful results. Prompt and appropriate surgical management is thus necessary in these children to prevent amblyopia and achieve better visual outcomes. (Dick HB and Augustin AJ. 2001). Multiple surgical options have been described including

implantation of anterior chamber intraocular lens (ACIOL), iris claw lens and SFIOL. Implantation of SFIOL is said to be well tolerated in pediatric eyes (Kumar et al, 1999; Mittelviehhaus et al, 2000; Bardorf et al, 2004; Asadi and Kheirkhah, 2008; Hyun et al, 2009; Hsu et al, 2012; Bhutto et al, 2013) though various complications have been reported such as intraocular hemorrhage, corectopia, retinal detachment, raised intraocular pressure, suture related complications, endophthalmitis and postoperative astigmatism (Bhutto et al, 2013).

In our study, we analyzed the refractive and visual outcome in 25 pediatric eyes with non-traumatic ectopia lentis who underwent lensectomy and SFIOL implantation either as a single or two staged procedure.

At two months post-operative follow up 18 eyes showed improvement by two or more lines and in seven eyes the pre-operative BCVA remained unchanged. Seven out of 18 eyes attained a postoperative BCVA of 0.2 logMAR units or more at two month post-operative follow up. However by final follow up, five eyes showed further improvement by two or more lines, three eyes remained stable and three eyes showed worsening of visual acuity. Timely follow up, regular use of glasses



and strict emphasis on amblyopia therapy has likely resulted in further improvement in visual acuity in these five eyes. The deterioration of the BCVA in three cases was due to late post-operative complications of retinal detachment, IOL dislocation and IOL decentration. These cases underwent vitreoretinal surgery for retinal reattachment and IOL re-fixation respectively. Among eyes which had no change in BCVA following SFIOL implantation, six eyes with grade 4 subluxation maintained the BCVA of 0.2 logMAR, though there was significant reduction of the hyperopic refraction. One 16 year old child with unilateral subluxation of lens, high myopic refraction and a poor visual acuity of 1.0 logMAR did not show any improvement postoperatively secondary to dense amblyopia.

On review of literature, in a study by Hsu et al, (2012) 77% showed post-operative BCVA greater than 0.3 logMAR in 13 eyes of ectopia lentis. Zetterstrom et al (1999) and Epley et al (2000) reported similar results in 32% and 39% of the eyes respectively. In studies by Buckley, Kumar, Asadi and Bhutto et al postoperative BCVA of 0.3 logMAR or more ranged between 55 %- 79%. (Buckley 2008; Kumar et al, 1999; Asadi and Kheirkhah, 2008; Bhutto et al, 2013) However, in these studies SFIOL implantation has been performed in eyes with traumatic cataract, surgical aphakia and ectopia lentis. In our series, 64% eyes showed BCVA of 0.3 logMAR or more following SFIOL implantation in eyes with non-traumatic ectopia lentis at two months follow-up.

Intraocular lens implantation causes elimination of optical aberrations and thereby a better subjective acceptance leading to improved quality of vision. This resulted in significant change in visual acuity following SFIOL implantation in our series. Moreover the improvement in media clarity and enhanced optical clarity with glasses due to decrease in refractive error following SFIOL implantation

led to improvement in compliance with these glasses.

Astigmatism following SFIOL implantation has been reported to range from -1.5DC to -4.5 DC in different studies. (Buckley, 2008; Bhutto et al, 2013; Dick and Augustin, 2001). The postoperative astigmatism reported by Bardoff et al was less or equal to 1.5 DC in all patients (2004). Bhutto et al (2013) reported a mean astigmatism of -2.42 DC after SFIOL implantation and attributed large corneal incision, tight sutures or IOL decentration as causes of postoperative astigmatism. (Bhutto et al, 2013) In our series the mean post-operative astigmatism was -1.47 ± 0.98 DC which was comparable with the study by Bhutto et al (2013). We found no statistically significant difference between pre and post-operative corneal astigmatism (p value 0.56). The mean difference between total and corneal astigmatism postoperatively (IOL induced astigmatism) was -1.01 ± 0.95 DC, which is comparable to -0.59 DC reported by Kjekja et al (2008). There was minimal IOL induced astigmatism and this could be secondary to the surgical procedure used by us where the torque of the IOL was reduced by passing the sutures in opposite directions through the eyelets of the IOL resulting in mild IOL tilt or decentration. Keratometry was performed to determine astigmatism during the study period. Newer technologies such as the anterior segment optical coherence tomography (AS-OCT) are now available and can aid in studying the cornea.

Six eyes had post-operative astigmatism of more than 3 DC which could be corrected with spectacles. The BCVA was better than 0.3 logMAR in five eyes at two months follow up. One eye had a BCVA of 1.17 logMAR which further improved to 0.3 logMAR on final follow up after strict amblyopia therapy.

In another study by Kohli et al only 12.5% eyes had astigmatism > 1.5 DC following sutureless,

glueless intrascleral fixated posterior chamber intraocular lenses in children with ectopia lentis which was higher than the astigmatism noted in the present study.

In the current series, spherical refractive equivalent was within 2D of the target refraction calculated preoperatively in 20 eyes (80%) which was comparable to that reported by Mimura et al (2004).

In conclusion, SFIOL implantation is a safe procedure for visual rehabilitation in children with non-traumatic ectopia lentis leading to significant reduction in refractive error. However, a regular postoperative follow up and strict compliance with amblyopia therapy is mandatory for a good visual outcome. Our study is limited by its retrospective nature. A longer follow up is required to assess the change of refraction and the stability of SFIOL. We recommend an observational prospective study in a larger cohort with longer follow up to confirm these results.

References

Asadi R, Kheirkhah A (2008). Long-term results of scleral fixation of posterior chamber intraocular lenses in children. *Ophthalmology*;115:67-72.

Bardorf CM, Epley KD, Lueder GT, Tychsen L (2004). Pediatric transscleral sutured intraocular lenses: efficacy and safety in 43 eyes followed an average of 3 years. *JAAPOS*;8:318-24.

Bhutto IA, Kazi GQ, Mahar PS, Qidwai UA (2013). Visual outcome and complications in Ab-externo scleral fixation IOL in aphakia in pediatric age group. *Pakistan journal of medical sciences*;29(4):947-50.

Buckley EG (2008). Safety of transscleral- sutured intraocular lenses in children. *JAAPOS*; 12 (5):431-9.

Dick HB, Augustin AJ (2001). Lens implant selection with absence of

capsular support. *Current Opinion in Ophthalmology*;12(1):47-55.

Enyedi LB, Peterseim MW, Freedman SF, et al (1998). Refractive changes after pediatric intraocular lens implantation. *American Journal of Ophthalmology*; 126(6):772-81.

Epley KD, Shainberg MJ, Lueder GT, Tychsen L (2001). Pediatric secondary lens implantation in the absence of capsular support. *JAAPOS*; 5(5):301-6.

Hsu HY, Edelstein SL, Lind JT (2012). Surgical management of non-traumatic pediatric ectopia lentis: A case series and review of the literature. *Saudi Journal of Ophthalmology*; 26(3):315-21.

Hyun DW, Lee TG, Cho SW (2009). Unilateral Scleral Fixation of Posterior Chamber Intraocular Lenses in Pediatric Complicated Traumatic Cataracts. *Korean Journal of Ophthalmology*; 23(3):148-52.

Jarrett WH II (1967). Dislocation of the lens. A study of 166 hospitalized cases. *Arch Ophthalmol*;78(3):289-96.

Kjeka O, Bohnstedt J, Kyrre Meberg et al (2008). Implantation of scleral-fixated posterior chamber intraocular lenses in adults. *Acta Ophthalmologica*;86(5):537-42.

Kumar M, Arora R, Sanga L, Sota LD (1999). Scleral-fixated intraocular lens implantation in unilateral aphakic children. *Ophthalmology*;106(11):106:2184-9.

Mimura T, Amano S, Sugiura T et al (2004). Refractive change after transscleral fixation of posterior chamber intraocular lenses in the absence of capsular support. *Acta Ophthalmologica Scandinavica*;82(5):544-6.

Mittelviefhaus H, Mittelviefhaus K, Gerling J (2000). Transscleral suture fixation of posterior chamber intraocular lenses in children under 3 years. *Graefes Arch Clin Exp Ophthalmol*;238(2):143-8.



Nb K, Kohli P, Pangtey BPS, Ramasamy K (2018). Evaluation of Sutureless, Glueless, Flapless, Intrasceral Fixated Posterior Chamber Intraocular Lens in Children with Ectopia Lentis. *J Ophthalmol*;2018:3212740.

Streeten BW.(2000). Pathology of the lens. In: Albert DM, Jakobiec FA,eds. Principles and practice of ophthalmology. Philadelphia (PA): Saunders:2225–39.

Waiswol M, Kasahara N (2009). Lens subluxation grading system. *Einstein*; 7:81-7.

Zetterström C, Lundvall A, Weeber Jr H, Jeeves M (1999). Sulcus fixation without capsular support in children. *J Cataract Refract Surg*;25:776-81.