

## Endoscopic Endonasal Dacryocystorhinostomy under Local Anesthesia or Assisted Local Anesthesia

Diwa Hamal<sup>1</sup> , Prerna Arjyal Kafle<sup>1</sup>, Binaya Lamichhane<sup>1</sup>, Afaque Anwar<sup>1</sup>, Sanjaya Kumar Singh<sup>1</sup>

<sup>1</sup>Biratnagar Eye Hospital, Biratnagar, Nepal

### ABSTRACT

**Introduction:** Endoscopic Endonasal Dacryocystorhinostomy (EENDCR) is effective, safe and less time consuming procedure and scar free to manage patients with epiphora. Traditionally, EENDCR is performed under general anesthesia. Limited general anesthesia facility in our country has made EENDCR surgery limited to the hospitals with GA facilities. EENDCR surgery under local or assisted local anesthesia could be an alternative solution. The aim of the study was to study the pain tolerability of the patient undergoing EENDCR under local anesthesia (LA) or assisted local anesthesia (ALA). To the best of our knowledge, there is a lack of similar studies in Nepal.

**Materials and methods:** This was a prospective, nonrandomized, interventional study done at a tertiary eye care center. After sample collection the study was aimed to evaluate the pain tolerability of patients undergoing EENDCR under LA or ALA. The case collection and the surgery were done by a single surgeon from 2018 Jan- 2019 April and followed for 6 to 24 months. All consecutive cases were enrolled in the study. Informed consent was obtained from all the patients. Inclusion criteria included chronic dacryocystitis with NLDO (Nasolacrimal duct obstruction), lacrimal sac mucocele and lacrimal sac pyocele. Previously failed DCR surgery was not included in the study. Total of 100 patients of EENDCR with a tube who completed a minimum 6 months follow up postoperatively were included in the study. Verbal rating scale (VRS) was used to report response to pain during different steps of surgery.

**Results:** There were 100 patients within the age range of 13-41 years of age. One hundred and six EENDCR were performed on 100 patients. Eighty-seven patients were adult (19-41) years and 13 patients were of pediatrics age group (13-18) years. There were 74 female and 26 male patients. Thirty-seven were RE (right eye), 57 were LE (Left eye) and 6 were BL (bilateral). Duration of illness was less than 6 months in 9 patients and more than 6 months in 91 patients. Ninety-two eyes were operated under LA and fourteen eyes of 11 patients asked for sedation in addition to local anesthesia (ALA). Patients reported pain during the creation of the bony ostium with Keryson's rongeur (24 eyes, VRS 3-4) and while using the drill (19 eyes, VRS 5-6). On pain scoring, there was no pain (0-2) in patients who underwent EENDCR under ALA. Pain scoring in patients who underwent EENDCR under LA showed no pain (0-2) in 53.26%, mild pain (3-4) in 26.09%, and moderate pain (5-6) in 20.65%. Duration of surgery ranged from 15 to 45 minutes. Duration of follow up was 6- 24 months. There was a 96.2% success rate in this study.

**Conclusion:** EENDCR can be done under LA or ALA depending on the indication and demand of the patient.

**Key words:** DCR, Endoscopic endonasal DCR, Local anesthesia, Nasolacrimal duct obstruction.

**Financial Interest** : Nil

Received : 05.07.2020

**Conflict of Interest** : Nil

Accepted : 01. 05.2021

#### Corresponding Author

Dr. Diwa Hamal  
Department of Orbit, plastic and lacrimal,  
Biratnagar Eye Hospital,  
Biratnagar, Nepal.  
E-mail: diwa222@hotmail.com



**Access this article online**

**Website:** [www.nepjol.info/index.php/NEPJO](http://www.nepjol.info/index.php/NEPJO)

**DOI:** <https://doi.org/10.3126/nepjoph.v14i1.21971>

**Copyright** © 2022 Nepal Ophthalmic Society

**ISSN:** 2072-6805, **E-ISSN:** 2091-0320



This work is licensed under a Creative Commons Attribution-NonCommercial-NoDerivatives 4.0 International License (CC BY-NC-ND).

## INTRODUCTION

EENDCR (Endoscopic Endonasal Dacryocystorhinostomy) is a simple, safe, skillful, less time consuming, scar free and highly satisfying surgery. Traditionally, EENDCR is performed under general anesthesia but local anesthesia with or without sedation for endoscopic DCR (Dacryocystorhinostomy) also appears to be safe and well tolerated. (Howden J et al, 2007; Durvasula VS et al, 2004; Meyer DR et al, 2000; Moore WM et al, 2002; Smith MG et al, 2001; Ragab SM et al, 2011.)

Local anesthesia can be effectively given for EENDCR by anesthetizing the anteromedial orbital structures including the lacrimal fossa plus the nasal mucosa and periosteum anterior to the uncinate process, in which the lacrimal window is created (Yung M.W et al, 1999).

The ophthalmic and maxillary divisions of the trigeminal nerve serve the areas involved in the surgery (Dutton J J et al, 1994; Netter F H, 1989). The ophthalmic division supplies two branches to this area: the infratrochlear nerve (medial upper eyelid, medial canthus & lacrimal sac) and the anterior ethmoidal nerve (lateral nasal wall, septum, anterior ethmoidal air cells and dorsum of the nose). Sensory branches of the pterygopalatine ganglion also supply the inside of the nose (Netter F H, 1989; Ciftci et al, 2005). Maxillary division innervates by way of the infra-orbital nerve (medial canthus and medial lower eyelid, lacrimal sac partly and upper nasolacrimal duct). The inferior portion of the

nasolacrimal canal and duct is innervated by the anterior superior dental nerve, which branches from the infraorbital nerve before it emerges from the infraorbital foramen (Lee, 2003). It is necessary to adequately anesthetize all of these nerves to ensure a painless procedure.

We will evaluate the pain tolerance of patients undergoing EENDCR under LA (local anesthesia) or ALA (assisted local anesthesia) in this study. General anesthesia is limited to a few eye hospitals in urban settings in Nepal. In addition EEDCR under local anesthesia could be a great approach to reduce longer waiting lists due to constraints of limited available resources even in hospitals equipped with general anesthesia facilities.

## MATERIALS AND METHODS

This was a prospective, nonrandomized, interventional study done at tertiary eye care center. Consecutive sampling was done after sample information. The study was aimed to evaluate the pain tolerability of patients undergoing EENDCR under LA (local anesthesia) or ALA (assisted local anesthesia). This study was done with approval from the hospital review board of Biratnagar Eye Hospital, Nepal. The case collection and surgery was done from 2018 Jan- 2019 April and followed for 6 to 24 months. Informed consent was taken from all the patients undergoing the study under LA or ALA. Inclusion criteria included chronic dacryocystitis with NLDO (nasolacrimal duct obstruction), lacrimal sac

mucocele, and pyocele. Patients who gave consent for study were only included in the study. Previously failed DCR surgery, patients with systemic illness, patients with nasal pathology as malignancy, nasal polyp, and those patients who did not follow up for at least 6 months postoperatively were excluded from the study. Nasal examination was done to rule out any condition that would contraindicate the EENDCR surgery. Total of 100 patients of EENDCR with tube satisfying the inclusion criteria were included in the study. All one hundred patients were operated under local or assisted local anesthesia. The collected data were recorded in Microsoft Excel 16.13.1 and statistical analysis was done using Statistical Package for Social Sciences version 25.

### **Anesthetic Technique**

Nasal packing was done with 4% Xylocaine with adrenaline 1:10000 IU for 30 minutes before surgery. The infra orbital, infra trochlear and dorsal nasal nerve were blocked transcutaneously by using local anesthesia 0.5% Bupivacaine, 2% Xylocaine with adrenaline 80,000 IU and Hyaluronidase. The nasal mucosa around the anterior root of the middle turbinate, above the inferior turbinate and over the nasal septum were then anesthetized. Sedation was done with Pethidine 1mg/kg and midazolam 0.02mg/kg & added with Ondansetron 0.15 mg/kg for patients who decided to do surgery under ALA before surgery. Vitals (BP, pulse, respiratory rate) were continuously monitored.

### **Evaluation of Pain management**

To measure the intensity of pain the verbal rating scale (VRS) was used. Replies to the Verbal Rating Scale were recorded intraoperatively, the patients were asked to verbally rate the level of perceived pain on a numerical scale from 0 to 10, with zero representing one extreme (no pain) and 10 representing the other extreme (worst pain). Patient's response to pain at different steps of surgery was classified based on the verbal response.

### **Surgical Technique**

Lacrimal irrigation was done to confirm the site of obstruction on the table before giving the block. EENDCR surgery was done by standard procedure. Carlstorz endoscope with telescope 4mm diameter was used. Procedure included anesthesia, nasal mucosal flap preparation, osteotomy, opening the lacrimal sac and intubation with Crawford bicanalicular stent. A nasal mucosal flap was made anterior to the middle turbinate with a number 15 surgical blade and elevated with a freer periosteal elevator. The nasal mucosal flap was excised and the underlying bone exposed. The osteotomy was performed with a Kerrison Rongeur and powered diamond burr as per hardness of frontal process of maxilla. The irrigation rate for the burr (marathon drill) was reduced to minimize the risk of aspiration. The lacrimal bone, frontal process of the maxilla, and root of the middle turbinate were removed to size of approximately 15 x 15 mm. The lacrimal sac was opened like a

book. Canaliculus was probed and used to tent the medial wall of the lacrimal sac, which was incised with a keratome and completed with a sickle knife. The lacrimal sac was opened to create anterior flap, posterior flap, and the anterior flap was excised. Time duration of the surgery as well as the approximate drill time were recorded.

### Post-operative

The patients were monitored for nausea, epistaxis and vomiting post-operatively. Systemic antibiotic, topical antibiotic with steroid, analgesics, nasal decongestant drops were advised for one week and to follow up after 2 weeks, 1 month, 3 months then every 6 months. Crawford's bicanalicular stent was removed in 3 months.

The functional success was defined as subjective improvement of epiphora as reported by the patient at 6 months' follow-up. The patients were also asked if they felt the surgery was successful.

Anatomical success was defined as evidence of FDDT (Fluorescein dye disappearance test) and patent syringing at 6 months follow-up.

### RESULTS

There were 100 patients (106 eyes) within the age range of 13-41 years of age. Eighty-seven patients (90 eyes) were adult (19-41) years and 13 patients (16 eyes) were of pediatrics age group (13-18) years. There were 74, 74% female patients (77, 72.64% eyes) and 26, 26% male patients (29, 27.35% eyes). There were 37 RE, 57 LE and 6 BL included in the study. Duration of illness was less than 6 months in 9 patients and more than 6 months in 91 patients.

Ninety-two eyes of 89 patients were operated under local anesthesia and fourteen eyes of 11 patients asked for sedation in addition to local anesthesia. The distribution of pain score was done as per mentioned in the methodology. VRS used to see the patient's response to pain after anesthesia has been classified in table 1.

**Table 1: Verbal rating scale (VRS) used to see the patient's response to pain after anesthesia during surgery.**

VRS (Verbal rating Scale)	ALA	LA
	14	92
No pain (0-2)	14	49(53.26%)
Mild pain (3-4)	0	24 (26.09%)
Moderate pain (5-6)	0	19 (20.65%)
Sever pain (7-8)	0	0
Worst pain (9-10)	0	0

**Table 2: Patient’s response to pain at different steps of surgery.**

<b>SURGICAL STEPS UNDER LA</b>	<b>VERBAL RATING SCALE FOR LA</b>	<b>NO OF EYES</b>
Skin incision	0-2	92(100%)
Bony ostium with Rongeur	3-4	24(26.09%)
Lacrimal sac flap	0-2	92(100%)
Nasal mucosal flap	0-2	92(100%)
Wound closure	0-2	92(100%)
Bony ostium with Drill	5-6	19(20.65%)

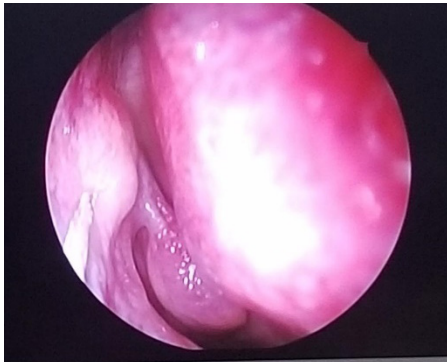
Patient’s response to pain at different steps of surgery done under LA, detail has been classified in Table 2.

Drill was used in 47 eyes as per needed for removing the hard frontal process of maxilla and to smoothen the cut margin of the bony ostium. The average drill time was 3min. Drill was not used in 59 eyes, as it was not necessary due to soft easy removal of the frontal process of maxilla with Kerrison Rongeur. Nineteen patients out of 47 operated under LA on whom drill was used had pain and discomfort during the surgery. The pain was due to superficial burn over the nasal ostium by the vibrating drill in 8 cases. The unpleasant sound and vibration caused discomfort. Eyes operated under ALA did not complain of pain in any of the steps of the surgery. Under LA 24 eyes had pain (VRS 3-4) during creation of the bony ostium with Kerrison Rongeur and using drill (19 eyes, VRS 5-6). On pain scoring, there was no pain in the ALA group. In the LA group there was no pain (0-2) in 51.08%, mild pain (3-4) in 26.08%, and moderate pain (5-6) in 20.65%.

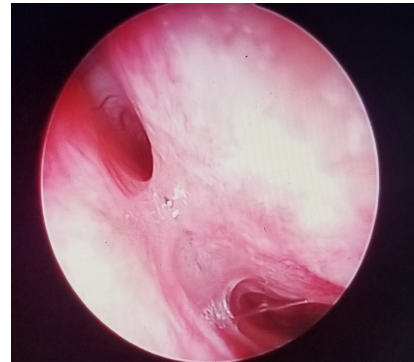
Two eyes operated under LA had minor

intraoperative complications that were difficult in bone punch. Seven eyes operated under LA had post-operative complications. Two eyes had immediate postoperative hemorrhage that was controlled with nasal repacking and oral Tranexamic acid. Upper punctal granulomas noted in 1 eye were excised with Crawford’s bicanalicular stent in situ on 3<sup>rd</sup> month postoperatively. There was persistent watering from 4 eyes (3.7%) at 3<sup>rd</sup> postoperative month follow-up. On FDDT and lacrimal irrigation they were diagnosed as failed DCR. Failed cases were diagnosed and managed endoscopically on the third and fourth month post operatively. The cause of failure was nasal mucosal fibrosis in 2 cases. Granulation tissue was formed over the internal ostium in one case. There was adhesion between the nasal mucosa and the nasal septum in another case. On asking the patients if they feel the primary surgery as successful, 96 patients were satisfied and comfortable until the last follow up. Overall success rate of EENDCR in this study was 96.2%.

Duration of surgery ranged from 15 to 45 minutes. Duration of follow up was 6 to 24 months (mean was 6.84 months, SD was 1.70).



**Figure 1: Showing the nasal mucosa around the anterior root of the middle turbinate, above the inferior turbinate were being anesthetized.**



**Figure 2: Showing adhesion between nasal mucosa and nasal septum post EENDCR surgery.**

## DISCUSSION

EENDCR is highly rewarding surgery for management of dacryocystitis when epiphora does not respond to medications or repeated syringing of nasolacrimal duct (Bharangar S et al, 2012).

Our study demonstrates that EENDCR under LA with and without sedation is well tolerated by patients. Fifty-one percent of the patients had no pain, 26.08% had mild pain and 20.65% had moderate pain when operated under LA. The pain was perceived during making the bony ostium by the ronger or drill. All the patients who were operated under ALA had no pain during the surgery.

Due to a long list for surgery under GA patient parties were given a choice of LA or ALA and operated accordingly. Only 11 paediatric patients (14 eyes) underwent surgery under ALA.

Various local anesthetic techniques with or without sedation have been described in the

literature. In our method of LA infraorbital, infra trochlear and dorsal nasal nerves were blocked by transcutaneous and intranasal injection by using local anesthesia 0.5% Bupivacaine, 2% Xylocaine with adrenaline 80000 IU and Hyaluronidase that worked well in our patients. Sedation was done with addition of pethidine 1mg/kg and midazolam .02mg/kg & added with Ondansetron 0.15 mg/kg for ALA for patient who decided before surgery.

In our study 11 out of 13 (84.6%) pediatric patients underwent surgery under ALA and 3 of them underwent surgery in other eyes too with no complication and complain of pain and discomfort.

Smith GM et al (2001) in his studies described EENDCR under LA done by ENT surgeon by the use of intranasal anesthesia by instilling 10% cocaine paste 1hour preoperatively. 1 mL of 2% lignocaine with 1:80 000 adrenaline was injected into the lateral nasal wall anterior to the uncinat process. Lacrimal fossa block was



performed with 2-3 mL of LA. Patients were asked to mark their level of perceived pain intensity using a visual analogue scale. Overall acceptability was comfortable in 30 eyes, mildly unpleasant in 28 eyes, moderately unpleasant in 7 eyes and very unpleasant in 1 eye. Eighty-eight per cent recorded perioperative pain scores  $\leq 5$  on a VAS (Smith GM et al, 2001).

Watkins et al. in their review of EENDCR used infraorbital, anterior ethmoidal and subcutaneous LA blocks as providing effective anesthesia (Watkins LM et al, 2003).

Assessment of pain can be done by various methods (visual analogue scale) VAS and (Verbal Rating Scale) VRS are among the commonest ones. We did the assessment of pain by using the VRS method, as it is easy, even for the illiterate patients as most of our patients are from low socioeconomic status with poor literacy rate. Cork et al (2004) in his comparative study demonstrated that VRS is easily assessed, takes less time than the VAS, and can be performed without the need of paper and pen. In our study on doing EENDCR under LA, 24 eyes had mild pain (VRS 3-4) during creation of the bony ostium with Kerrison Rongeur and moderate pain on using drill (19 eyes, VRS 5-6) that was tolerable. On pain scoring, there was no pain in the ALA group. In the LA group there was no pain (0-2) in 51.08%, mild pain (3-4) in 26.08%, and moderate pain (5-6) in 20.65%.

We can also explain that additional sedation can be provided if necessary. In our study none of

the patients undergoing surgery under ALA had pain.

Chan OW et al in his study explained that pain was acceptable with alone intra-nasal anesthesia even in patients that underwent additional procedures such as limited septoplasty, turbinectomy and lacrimal intubation. 56% of the patients were completely pain free intra-operatively and no patients had pain score (VAS) of  $>30/100$ . 97.7% (43/44) of patients were happy to have EENDCR with drill again under ALA. (Chan OW et al, 2014). Durvasula and Gatland studied 70 patients undergoing EENDCR, 60 of whom had the procedure under LA and midazolam. They used local infiltration of the medial canthal area and nasal mucosa with 2% lignocaine with 1:80 000 adrenaline and topical intranasal 10% cocaine solution. 88% were satisfied with the tolerability of the procedure under assisted LA (Durvasula et al, 2004).

The acceptability of EENDCR under LA or ALA appears comparable to other forms of DCR performed under LA with or without sedation. The reported range of acceptability for EENDCR is 62.9% to 98.7% (Howden J et al, 2007; Smith MG et al, 2001; Ragab SM et al, 2011; Tripathi A et al, 2002).

The strengths of this study includes a prospective design, standard surgical procedure, assessment of pain done on the first postoperative day by VAS by a single surgeon, and includes a good number of patients. The weakness of this study

is patients were not randomized; patients may have different levels of pain perception that was not addressed. The recruitment of patients for EENDCR inherently introduces some bias or sampling error into the study following discussion of the options of LA or assisted LA. Only the pediatric group of patients preferred ALA in our study rest all of them preferred LA alone.

Our study establishes LA or ALA as a possible alternative to general anesthesia for EENDCR. Various benefits of DCR under LA or ALA includes avoidance of general anesthesia in high risk patients, reduced operating room time, less intraoperative bleeding, shorter recovery period, less postoperative nausea and vomiting, decreases analgesic requirements (Howden J et al, 2007; Ciftci F et al, 2005). Surgeries performed under LA/ ALA are usually done on

an outpatient basis and reduce health care cost (Fanning G L et al, 2000; Howden J et al, 2007).

LA alone is acceptable for EENDCR but the option of ALA can be provided if needed. Patients should be educated before surgery that they may find the sound of the drill unpleasant and there can be tolerable levels of pain during osteotomy by drill and ronger if necessary that can be taken care of by additional sedation (ALA).

## CONCLUSION

EENDCR can be done under LA or ALA depending on the indication and demand of the patient.



## REFERENCES

- 
- Bharangar S, Singh N, and Lal V (2012). Endoscopic Endonasal Dacryocystorhinostomy: Best Surgical management for DCR. *Indian J Otolaryngol Head Neck Surg*; 64(4): 366-369. doi: 10.1007/s12070-011-0345-0
- Chan WO, Fahlbusch D, Dhillon P, and Selva D (2014). Assisted Local Anesthesia for Powered Endoscopic Dacryocystorhinostomy, *Orbit*; 33 (6): 416-420. doi: [10.3109/01676830.2014.949790](https://doi.org/10.3109/01676830.2014.949790)
- Ciftci F, Pocan S, Karadayi K, Gulecek O (2005). Local versus general anesthesia for external dacryocystorhinostomy in young patients. *OphthalPlastReconstr Surg*; 21 (3): 201-206. doi: [10.1097/01.IOP.0000163317.73873.C9](https://doi.org/10.1097/01.IOP.0000163317.73873.C9)
- Cork RC, Isaac I, Elsharydah A, Saleemi S, Zavisca F, Alexander L (2004). A comparison of the verbal rating scale and the visual analog scale for pain assessment. *Int J Anesthesiol*; 8:1. doi: [10.5580/1a73](https://doi.org/10.5580/1a73)
- Durvasula VSP, Gatland DJ (2004). Endoscopic dacryocystorhinostomy: long-term results and evolution of surgical technique. *J LaryngolOtol*; 118(8): 628-632. doi: [10.1258/0022215041917835](https://doi.org/10.1258/0022215041917835)
- Dutton J J (1994). *Atlas of Clinical and Surgical Orbital Anatomy*. Philadelphia: WB Saunders Company.
- Fanning GL (2000). Local anesthesia for dacryocystorhinostomy. *CurrAnaesth Crit Care*; 11: 306-309. doi: [10.1054/cacc.2000.0285](https://doi.org/10.1054/cacc.2000.0285)
-





- 
- Howden J, McCluskey P, O'Sullivan G, Ghabrial R (2007). Assisted local anaesthesia for endoscopic dacryocystorhinostomy. *Clin Experiment Ophthalmol*; 35 (3): 256-261. doi: [10.1111/j.1442-9071.2006.01412.x](https://doi.org/10.1111/j.1442-9071.2006.01412.x)
- Lee KJ (2003). Essential Otolaryngology. Head & Neck Surgery. In: Lee KJ (ed). *Anesthesia for Head & Neck Surgery*. McGraw Hill; 916-920.
- Meyer DR (2000). Comparison of oxymetazoline and lidocaine versus cocaine for outpatient dacryocystorhinostomy. *OphthalPlastReconstr Surg*; 16 (3):201-205. doi: [10.1097/00002341-200005000-00006](https://doi.org/10.1097/00002341-200005000-00006)
- Moore WM, Bentley CR, Olver JM (2002). Functional and anatomic results after two types of endoscopic endonasal dacryocystorhinostomy: surgical and holmium laser. *Ophthalmology*; 109 (8): 1575-1582. doi: [10.1016/S0161-6420\(02\)01114-4](https://doi.org/10.1016/S0161-6420(02)01114-4)
- Netter F H (1989). *Atlas of Human Anatomy*. Ciba-Geigy Corporation, Summit, NJ.
- Ragab SM, El-Koddousy MS, Badr M (2011). Endocanalicular, high-pressure balloon catheter, endoscopic dacryocystorhinostomy: a randomized controlled trial. *Otolaryngol Head Neck Surg*; 145 (4): 683-688. doi: [10.1177/0194599811410534](https://doi.org/10.1177/0194599811410534)
- Smith MG, Kong AS, Yung MW, Hardman Lea S, Leary G (2001). Lacrimal fossa block: an audit of a minimally invasive regional anaesthetic technique for endoscopic dacryocystorhinostomy (DCR). *Clin Otolaryngol Allied Sci*; 26(5): 407-410. doi: [10.1046/j.1365-2273.2001.00493.x](https://doi.org/10.1046/j.1365-2273.2001.00493.x)
- Tripathi A, Lesser TH, O'Donnell NP, et al. Local anaesthetic endonasal endoscopic laser dacryocystorhinostomy: analysis of patients' acceptability and various factors affecting the success of this procedure. *Eye (Lond)* 2002; 16(2): 146-149.
- Watkins LM, Janfaza P, Rubin PA (2003). The evolution of endonasal dacryocystorhinostomy. *SurvOphthalmol*; 48: 73-84. doi: [10.1016/S0039-6257\(02\)00397-1](https://doi.org/10.1016/S0039-6257(02)00397-1)
- Yung M.W, Logan B.M (1999). The anatomy of the lacrimal bone at the lateral wall of the nose: its significance to the lacrimal surgeon. *Clin. Otolaryngol Allied Sci*; 24(4): 262-265. doi: [10.1046/j.1365-2273.1999.00235.x](https://doi.org/10.1046/j.1365-2273.1999.00235.x)
-