

## Case Report

### Retinal Vasculitis in a Patient with Ankylosing Spondylitis: A rare Association

Anindya Kishore Majumder<sup>1</sup>, Rupak Roy<sup>1</sup>, Ranju Kharel (Sitaula)<sup>2</sup>, Kowsigan Magesan<sup>3</sup> and Parthopratim Dutta Majumder<sup>3</sup>

<sup>1</sup>Aditya Birla Sankara Nethralaya, Mukundapur, Kolkata, West Bengal, India

<sup>2</sup>B. P. Koirala Lions Centre for Ophthalmic Studies, Tribhuvan University, Institute of Medicine, Kathmandu, Nepal

<sup>3</sup>Sankara Nethralaya, 18- College Road, Chennai, India- 600006

#### Abstract

**Purpose:** To report a case of retinal vasculitis in a patient with ankylosing spondylitis.

**Background:** Posterior segment involvement in HLA B-27-associated uveitis is uncommon but we report a case wherein retinal vasculitis was associated with HLA-B 27 uveitis. **Case:** A 36-year-old male, a diagnosed case of ankylosing spondylitis, presented to us with severe anterior segment inflammation associated vitritis in both the eyes. He received topical, oral steroid and immunosuppressive and 3<sup>1</sup>/<sub>2</sub>-month after the control of his uveitis, he underwent cataract surgery in his left eye. Fundus evaluation following cataract surgery revealed sclerosed retinal vessels and wide-field fundus fluorescein angiography confirmed retinal vascular involvement in both the eyes.

**Conclusion:** Retinal vasculitis, though rare can occur in patients with ankylosing spondylitis especially in conditions which present with panuveitis-like picture.

**Key words:** Ankylosing spondylitis, retinal vasculitis, HLA B-27, Panuveitis

#### Introduction

Posterior segment involvement in HLA B-27-associated uveitis though rare has been reported to involve 15-20% of the patients with HLA B-27-associated uveitis. (Pathanapitton et al., 2016) Among all other posterior segment involvements reported in association with HLA B-27-associated uveitis, retinal vasculitis in HLA B-27-associated uveitis is relatively uncommon.

Retinal vasculitis as a part of case series on posterior segment involvement in HLA B-27-associated uveitis have been described by various authors (Rodriguez et al., 1994) and recently Rothova and Braakenburg (Braakenburg and Rothova, 2014) have described a case-series of nine patients with retinal vasculitis in HLA-B-27 –associated concurrent anterior uveitis and panuveitis patients. To the best of our knowledge, there has been no such report described from India. HLA-B27-associated uveitis, which is primarily considered as anterior segment inflammation and since majority of the time a posterior segment involvement is overlooked; we believe our case report will help to create awareness among the young ophthalmologists about this uncommon involvement in HLA B-27-associated uveitis.

**Financial interest:** Nil

**Conflict of interest:** Nil

Received: 01.12.2017

Accepted: 28.21.2017

#### Corresponding author

Dr. Parthopratim Dutta Majumder MS, FMRF

Senior Consultant, Department of uvea & intraocular inflammation,

Sankara Nethralaya, 18 College Road, Chennai, India- 600006.

Phone: 044-28271616, Fax: 044-28254180

E-mail: drparthopratim@gmail.com

## Case Report

A 36-year-old male presented to us with gradual progressive diminution of vision which was associated with recurrent attacks of redness, ocular pain alternating between the two eyes for the last two years. He was diagnosed as ankylosing spondylitis one year back but at the time of presentation, he was not on any systemic medications investigation. He received intermittent treatment with topical steroid, cycloplegic and oral steroid for his ocular condition prescribed by the ophthalmologists elsewhere. On examination, his best corrected visual acuity (BCVA) by Snellen's visual acuity chart was 2/60 in the right eye and counting finger close to face at the one-meter distance in the left. Slit-lamp examination revealed cells 3+, flare 3+ with seclusio pupillae and complicated dense posterior subcapsular cataract in both the eyes. Intraocular pressure in both eyes was in early teens and fundus examination under mydriasis revealed a limited view of the fundus because of seclusio pupillae and 3+ media haze due to vitritis. Ultrasonography B-scan of both eyes showed hyperechoic shadows in mid and posterior vitreous with attached retina. He was extensively investigated to identify any infective or immunological causes of uveitis. His Mantoux was 10mm, ESR 15mm, ANA and RA factors were negative but HLA-B27 allele was detected by the molecular method using the polymerase chain reaction (PCR). In addition, an opinion from rheumatologist was sought, who confirmed the presence of ankylosing spondylitis too.

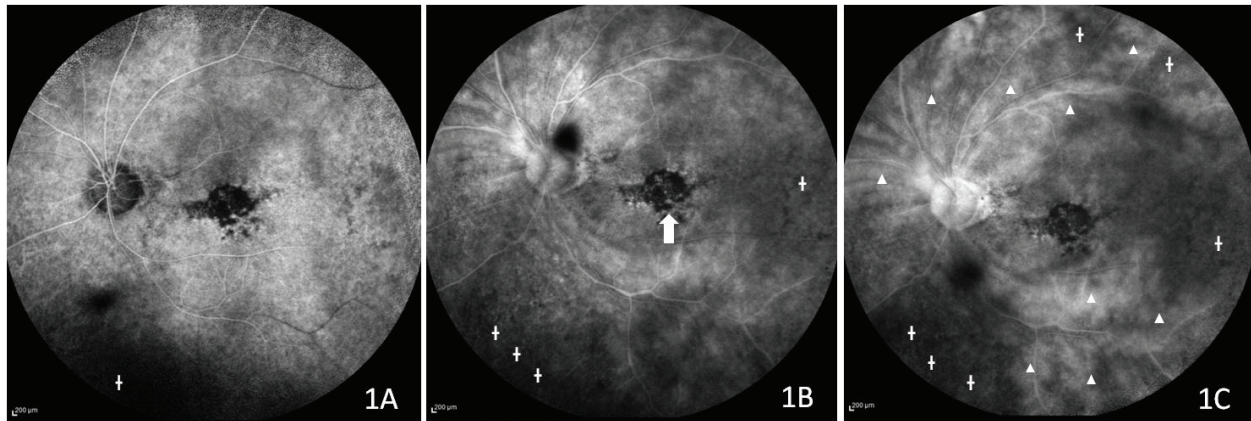
He was subsequently started on intense topical therapy with the topical corticosteroid and cycloplegic and oral corticosteroid (1mg/kg/day) along with subcutaneous methotrexate (20 mg/week) and sulphasalazine as advocated by the rheumatologist. He was monitored periodically while tapering oral and topical

medications by us and the rheumatologist. He underwent an uneventful phacoemulsification with implantation of posterior chamber intraocular lens in his left eye three and half months after initial presentation.

On post-operative evaluation, fundus examination of the left eye revealed sclerosed retinal vessels in the periphery and epiretinal membrane over macula. There was presence of old pigmented vitreous cells. Fundus examination of the left eye was difficult due to dense media haze and seclusio pupillae. A wide-field fundus fluorescein angiography (FFA) revealed staining of the retinal vessels in both of the eyes, though FFA images of the right eye were hazy for obvious reason. In addition, left eye showed gross capillary non-perfusion areas in the retinal periphery as well as a hypoperfused macula. (Figure 1) A sequel of occlusive retinal vasculitis was considered and the patient underwent a battery of laboratory investigations to rule out any evidence of systemic rheumatic disease especially systemic vasculitis. He was also evaluated thoroughly by the treating rheumatologist. However, no evidence of any systemic vasculitis was found.

## Discussion

Over the last few years, there has been an increase in the number of literature describing posterior segment manifestations of HLA B-27-associated uveitis.(Pathanapitoon et al., 2016)(Rodriguez et al., 1994)(Braakenburg and Rothova, 2014) HLA B-27-associated uveitis, the most common cause of acute anterior uveitis, is now believed to have a spectrum of presentation and this includes optic disc edema (Pathanapitoon et al., 2016), macular involvement (Wexler et al., 2012), epiretinal membrane formation, and intermediate uveitis (Dodds et al., 1999). Condition like panuveitis mimicking endophthalmitis, though rare, has been reported in the literature (Sanghvi et al, 2010).



**Figure 1A, 1B, 1C:** Serial (early, mid and late phase) fundus fluorescein angiography images showing staining of the blood vessels and leak of the dye at the capillary level (marked with white solid fill arrowhead), distorted foveal avascular zone (marked with white solid fill arrow) suggestive of ischaemic macula and peripheral retinal capillary non-perfusion areas (marked with white plus sign)

Our patient presented with an aggressive form of intraocular inflammation and subsequently found to have evidence of retinal vascular involvement. Extraocular vascular involvement in a patient with ankylosing spondylitis have been widely reported in the literature (Gan et al., 2014) (Palazzi et al., 2011). However, the literature on retinal vasculitis in patients of ankylosing spondylitis is limited. Reasons for such observation remain largely unknown. Retinal vasculitis patients are routinely not investigated for HLA B-27 and a FFA is not always performed in an aggressive form of HLA B-27 associated uveitis (Braakenburg and Rothova, 2014). These may be the contributing factors for which retinal vasculitis in HLA B-27 associated uveitis patients remain relatively uncommon.

Simultaneous bilateral involvement in HLA B-27-associated uveitis is usually rare but has been reported in the literature (Pathanapitoon et al., 2016). The absence of long-term systemic medications, delay in presentation can be attributed to the cause of such aggressive bilateral involvement of intraocular inflammation in our patient. Though our

patient was extensively investigated and evaluated by a rheumatologist, we could not find any evidence of any other systemic disease including infective aetiology pertaining to the cause of retinal vasculitis. Therefore we believe HLA B-27-associated uveitis could be a possible explanation to the etiopathogenesis of such involvement. Similar observations were reported by Rothova and Braakenburg (Braakenburg and Rothova, 2014). In a retrospective case-series of nine patients with HLA B-27-associated uveitis, retinal vasculitis was found to occur in association with concurrent anterior or panuveitis and in 89% cases, retinal vasculitis was bilateral. Similar to our patient, all of the patients in their series had panuveitis and four of them had presented with acute anterior uveitis. Our study also highlighted the importance of wide-field FFA in cases with peripheral retinal vasculitis. In a recently published study, the peripheral active vasculitis that was not evident clinically in conventional FFA was detected by ultra-wide FFA in 58.8% of eyes with retinal vasculitis. (Aggarwal et al., 2016) Conventional FFA may allow capturing more than 75° by asking

the patient to look in various directions. But the technique requires the expertise of the photographer, well dilatation of the pupil and patient cooperation and sometimes peripheral retinal vasculitis may be missed.

In conclusion, our report highlighted the relatively uncommon association of retinal vasculitis in patients with HLA B-27-associated uveitis. Clinicians must be aware of the posterior segment involvement in HLA B-27-associated uveitis and thoroughly investigate cases with such presentation including a wide-field FFA to look for peripheral retinal vascular involvement.

## References

Aggarwal, K., Muljutkar, S., Mahajan, S., Singh, R., Sharma, A., Bansal, R., Gupta, V., Gupta, A., (2016). Role of Ultra-Wide Field Imaging in the Management of Tubercular Posterior Uveitis. *Ocul. Immunol. Inflamm*; 24: 631–636. <https://doi.org/10.3109/09273948.2015.1099681>

Braakenburg, A.M., Rothova, A ( 2014). The clinical characteristics of retinal vasculitis in HLA-B27-positive patients. *Ocul. Immunol. Inflamm*; 22: 197–202. <https://doi.org/10.3109/09273948.2013.835429>

Dodds, E.M., Lowder, C.Y., Meisler, D.M (1999). Posterior segment inflammation in HLA-B27+ acute anterior uveitis: clinical characteristics. *Ocul. Immunol. Inflamm*; 7: 85–92.

Gan, F., Fei, Y., Li, M., Wang, Q., Xu, D., Hou, Y., Zeng, X., Zhang, F (2014.) The characteristics of patients having ankylosing spondylitis associated with Takayasu's arteritis. *Clin. Rheumatol*; 33: 355–358. <https://doi.org/10.1007/s10067-013-2444-7>

Palazzi, C., Salvarani, C., D'Angelo, S., Olivieri, I ( 2011). Aortitis and periaortitis in ankylosing spondylitis. *Jt. Bone Spine Rev. Rhum*; 78: 451–455. <https://doi.org/10.1016/j.jbspin.2010.11.003>

Pathanapitoon, K., Dodds, E.M., Cunningham, E.T., Rothova, A (2016). Clinical Spectrum of HLA-B27-associated Ocular Inflammation. *Ocul. Immunol. Inflamm*; 1–8. <https://doi.org/10.1080/09273948.2016.1185527>

Rodriguez, A., Akova, Y.A., Pedroza-Seres, M., Foster, C.S (1994). Posterior segment ocular manifestations in patients with HLA-B27-associated uveitis. *Ophthalmology*; 101: 1267–1274.

Sanghvi, C., Mercieca, K., Jones, N.P (2010). Very severe HLA B27-associated panuveitis mimicking endophthalmitis: a case series. *Ocul. Immunol. Inflamm*; 18: 139–141. <https://doi.org/10.3109/09273940903560236>

Wexler, A., Sand, T., Elsås, T.B (2012). Bilateral macular thickening in mild unilateral anterior uveitis: is HLA-B27 involved? *BMC Ophthalmol*; 12: 30. <https://doi.org/10.1186/1471-2415-12-30>