

## Case report

### A rare presentation of exudative macroaneurysms in unilateral Eales' disease

Nada M, Qanoongo S, Singh S.V., Khurana AK  
Regional Institute of Ophthalmology,  
PGIMS, University of health sciences, Rohtak, Haryana

#### Abstract

**Background:** A case of exudative macroaneurysms in unilateral Eales' disease is reported. 'Eales disease' is an idiopathic bilateral occlusive periphlebitis with neovascularisation and mostly presents with vitreous hemorrhage. **Case:** A 30 year old male presented with diminution of vision in left eye (6/36) for 1 month. Slit Lamp examination of both eyes revealed normal anterior segment. Fundus examination of left eye with + 90 D lens revealed reddish lesions at the macula with surrounding circinate exudation. On peripheral examination hemorrhages were seen along with vasculitis in the superotemporal quadrant. The right eye fundus was normal. All laboratory investigations were found within normal limits. **Conclusion:** Eales' disease is mostly a bilateral condition but this case is rare as there is unioocular involvement with exudative macroaneurysms. Laser therapy was instituted which was effective in management of this condition with restoration of normal visual acuity. There was no relapse on follow up for 2 years.

**Keywords:** Eales' disease, macroaneurysms, vasculitis, vitreous hemorrhage, laser photocoagulation

#### Introduction

In 1880, Henry Eales first described this disease in healthy young men with abnormal retinal veins, peripheral neovascularization, and recurrent vitreous hemorrhages. It is an idiopathic obliterative vasculopathy that usually involves the peripheral retina of young adults. It is an important cause of visual morbidity in young Asian males and rare in Caucasians. It is strongly associated with tuberculo-protein hypersensitivity. Presentation is usually in the 3rd–5th decades with vitreous haemorrhage.

The anterior chamber may exhibit cell and flare with keratic precipitates. Vitreous debris and cells often are seen, even in the absence of vitreous hemorrhage. Peripheral nonperfusion is a typical feature of Eales' disease. The surrounding vasculature is tortuous with microvascular abnormalities, which include the following: macroaneurysms, arteriovenous shunts, venous beading, hard exudates, and cotton-wool spots. Macroaneurysms are of three types: hemorrhagic, exudative and quiescent. Hemorrhagic macroaneurysms are associated with dot and blot hemorrhages, exudative macroaneurysms are associated with lipid exudation whereas quiescent macroaneurysms are inactive. We report a case of exudative macroaneurysms in unilateral Eales' disease.

Received on: 17/07/16

Accepted on: 01/12/16

#### Address for correspondence

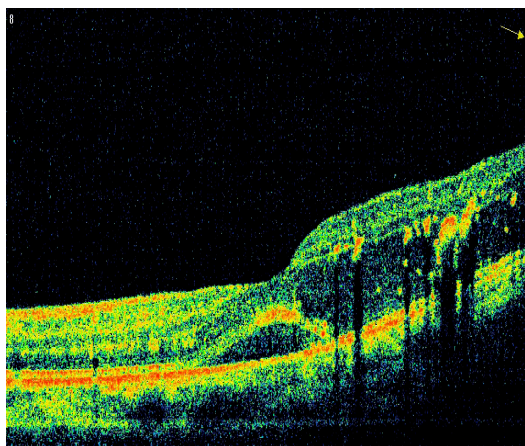
Dr. Manisha Nada, Professor  
Regional Institute of Ophthalmology, PGIMS, University of  
health sciences, 22/9 J Medical enclave, Rohtak-124001,  
(Haryana)  
Tel: 09896007158  
E-Mail : manisha\_nada@rediffmail.com

### Case report

A 30 years old male presented with decreased vision in left eye. On ocular examination the visual acuity (VA) in his right eye was 6/6, while in left eye was 6/36. Patient complained of blurring of vision in his left eye for one week. On slit lamp biomicroscopy examination the anterior segment of both eyes were normal. Intraocular pressure (IOP) was 16 mmHg in right eye and was 18 mmHg in left. Dilated fundus examination with +90 D lens of the left eye revealed reddish lesions at the macula with surrounding circinate exudation. Superotemporally hemorrhages were seen along with vasculitis. The right eye fundus was normal.

Laboratory investigations including blood glucose, complete blood count, angiotensin converting enzyme and lysozyme, antinuclear antibody, rheumatoid factor and ESR were found to be within normal limits. Tuberculin test and chest X-ray were also normal.

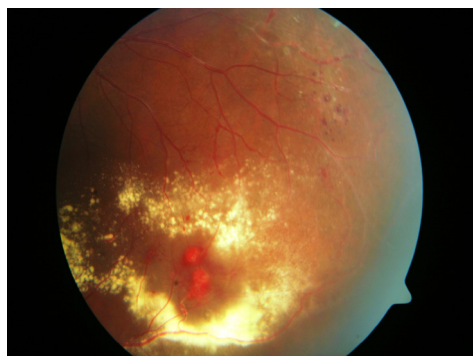
Imaging like optical coherence tomography (OCT) was done which showed perifoveal hard exudates and neurosensory detachment at macula (Figure 1).



**Figure 1:** Left eye OCT showing perifoveal hard exudates and neurosensory detachment at macula

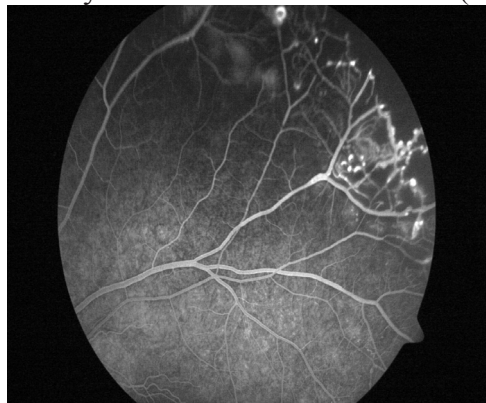
Fundus examination of left eye revealed hemorrhages, hard exudates and macroaneurysms. On fluorescein angiography

of the left eye, areas of vascular sheathing demonstrated dye leakage on FFA (Figure 2).

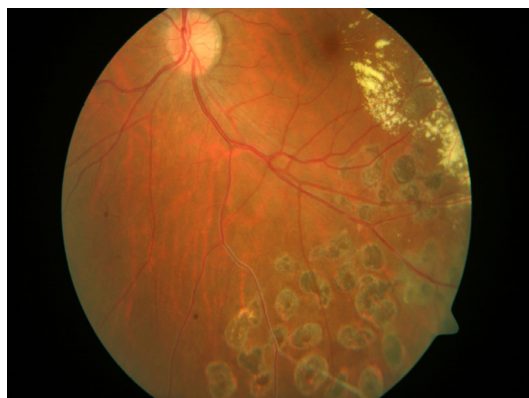

**Figure 2:** Fundus photograph of left eye revealed hemorrhages, hard exudates and macroaneurysms

During the venous phase delayed filling of the retinal macroaneurysm with fluorescein dye was seen. The aneurysm was obscured partially by the presence of hemorrhage, but filling by the dye enhanced visualization (Figure 3).



**Figure 3:** Left eye FA showing macroaneurysms and vascular leakage during late phase



**Figure 4:** Fundus picture of left eye showing laser spots after modified grid laser photocoagulation

During late phase complete filling of macroaneurysms with late leakage was seen.

FFA of right eye was normal.

### Treatment

Modified grid laser photocoagulation was done as oedema and exudates involved the macula and there was documented visual deterioration (Fig 4.).

Grid laser stimulates the RPE pump mechanism leading to enhanced removal of fluid from subretinal space and resolution of macular edema. Nepafenac eye drops were instilled twice daily for 3 months in the affected eye. The exudates and hemorrhages resolved and visual acuity of the patient improved to 6/6 after 6 months. The patient has been maintaining stable visual acuity since then without any relapse.

### Discussion

Laser treatment is safe and effective in the management of macular edema occurring as a result of exudation from macroaneurysms. Indications for laser treatment include vision loss due to chronic macular exudates or edema. (Rabb et al, 1988) Laser photocoagulation directly to the macroaneurysm using xenon arc, argon, or dye yellow has been documented in the literature to improve vision in some patients. (Rabb et al, 1988; Abdel-Khalek and Richardson, 1986; Hudomel and Imre, 1973) However, some studies note that direct photocoagulation to the macroaneurysm does not improve visual outcomes and may lead to branch retinal artery occlusion. (Brown et al, 1994) Indirect laser treatment to the area surrounding the macroaneurysm may also improve visual outcomes in some patients with macular edema. (Robertson, 1973; Palestine et al, 1982; Francois, 1979) Laser hyaloidotomy using a neodymium-doped yttrium aluminium garnet (Nd:YAG) laser for subhyaloid hemorrhage has been reported but is controversial due to the risk of vitreous

hemorrhage or damage to the macula. (Tassignon et al, 1989) As macular edema resolved after laser photocoagulation visual acuity of the patient improved and finally patient had 6/6 vision in the affected eye. There was no adverse effect of laser photocoagulation in the affected eye of the patient. There was no relapse and the patient has been maintaining stable vision of 6/6 since then.

Eales' disease is mostly a bilateral condition and is associated with vascular anomalies like macroaneurysms, arteriovenous shunts, venous beading, vitreous hemorrhage etc. These microvascular anomalies occur due to inflammatory weakening of vessel wall because of recurrent vessel wall inflammation. This case is rare as there is only unocular involvement with fundus picture suggestive of Eales' disease with associated exudative macroaneurysms.

Laser therapy is effective technique in the management of exudative macroaneurysms and helps in restoration of normal visual acuity as seen in this case. The visual acuity remained stable and there was no relapse.

On thorough search of literature, it has been found that unilateral Eales' disease with exudative macroaneurysms has not been reported till date.

### References

- Abdel-Khalek MN, Richardson J (1986). Retinal macroaneurysm: Natural history and guidelines for treatment. *Br J Ophthalmol*;70:2-11.
- Brown DM, Sobol WM, Folk JC, Weingeist TA (1994). Retinal arteriolar macroaneurysms: long-term visual outcome. *Br J Ophthalmol*; 78(7):534-538.
- Francois J (1979). Acquired macroaneurysms of the retinal arteries. *Int Ophthalmol*; 1:153-161.



Hudomel J, Imre G (1973). Photocoagulation treatment of solitary aneurysm near the macula lutea: Report of a case. *Acta Ophthalmol*; 51:633-638.

Palestine AG, Robertson DM, Goldstein BG (1982). Macroaneurysms of the retinal arteries. *Am J Ophthalmol*; 93:164-171.

Rabb M, Gagliano DA, Teske, MP (1988). Retinal Arteriolar Macroaneurysms: *Surv Ophthalmol*; 33:73-96.

Robertson D (1973). Macroaneurysms of the retinal arteries. *Trans Am Acad Ophthalmol Otolaryngol*; 77:55-67.

Saxena S, Pant AB, Khanna VK (2010). Tumor necrosis factor- $\alpha$ -mediated severity of idiopathic retinal periphlebitis in young adults (Eales' disease): implication for anti-TNF- $\alpha$  therapy. *J Ocul Biol Dis Infor*; 3:35-38.

Saxena S, Pant AB, Khanna VK (2009). Interleukin-1 and tumor necrosis factor- $\alpha$ :

novel targets for immunotherapy in Eales disease. *Ocul Immunol Inflamm*; 17:201-206.

Sen A, Paine SK, Chowdhury IH (2011). Association of interferon-gamma, interleukin-10, and tumor necrosis factor- $\alpha$  gene polymorphisms with occurrence and severity of Eales' disease. *Invest Ophthalmol Vis Sci*; 52:171-178.

Tassignon MJ, Stempels N, Van Mulders L (1989). Retrohyaloid premacular hemorrhage treated by Q-switched Nd-YAG laser. A case report. *Graefes Arch Clin Exp Ophthalmol*; 27(5):440-442.

Therese KL, Deepa P, Therese J, Bagyalakshmi R, Biswas J, Madhavan HN (2007). Association of mycobacteria with Eales' disease. *Indian J Med Res*; 126:56-62.

**Source of support: nil. Conflict of interest: none**