

Original article

Ocular manifestations of childhood acute leukemia in a tertiary-level eye centre of Kathmandu, Nepal

Deepak Khadka,¹Ananda K Sharma,²Jeevan K Shrestha,²Gauri S Shrestha²

Pun N Shrestha,³Suresh R Pant,¹Bidya P Pant¹

¹Geta Eye Hospital, Dhangadhi, Kailali,

²Institute of Medicine, Department of Ophthalmology

B.P. Koirala Lion's Centre for Ophthalmic Studies,

³Kanti Children Hospital, Maharajgunj, Kathmandu, Nepal

Abstract

Introduction: In some instances, the understanding of the ocular manifestations in childhood leukemia is not only important to establish the diagnosis but also reflects the disease state and prognosis. **Objective:** To study the ocular manifestations of childhood acute leukemia among the children attending a tertiary-level hospital in Nepal. **Materials and methods:** A cross-sectional, descriptive study was undertaken at the B.P. Koirala Lions Centre for Ophthalmic Studies (BPKLCOS) and Kanti Children Hospital (KCH), Kathmandu, over a period of one-and-a-half years. Children diagnosed with acute childhood leukemia referred to the BPKLCOS from the Oncology Unit of the KCH and the Emergency Department of the Tribhuvan University Teaching Hospital (TUTH) were included in the study, using a non-probability sampling method. **Results:** Of the 71 cases with childhood acute leukemia, 55 (77.5%; 95% CI = 66% - 85%) had acute lymphoblastic leukemia(ALL)whereas the other 16 (23%) had acute myeloblastic leukemia (AML). Ocular involvement were seen in 33 cases (46%) and were more frequent in cases of AML as compared to those with ALL (p=0.001, OR 5.0, 95% CI= 1.4 – 17.5). Direct ocular involvement and secondary ocular involvement were observed in 12 (16.9%) and 29 (40.8%) subjects, respectively. Ocular symptoms were present in only 11 cases (15.49%). Cerebro-spinal fluid (CSF) and bone marrow examination in cases with direct ocular involvement showed 10 cases (83.3%) positive for blast cells in the CSF and 6 cases (50%) positive for blast cells in bone marrow. The most common secondary manifestation was retinal haemorrhage, seen in 23 cases (32.4%). **Conclusion:** In view of the high asymptomatic ocular involvement and the significant visual morbidity, a routine ophthalmic examination is recommended as an integral part of the medical examination in all cases of childhood acute leukemia.

Keywords: Ocular manifestations, childhood acute leukemia, lymphoblastic leukemia, myeloblastic leukemia

Received on: 05.01.2013

Accepted on: 12.03.2014

Address for correspondence

Dr Ananda Kumar Sharma, MD

Associate Professor and Head Department of Ophthalmology
Institute Of Medicine, B.P. Koirala Lion's Centre
for Ophthalmic Studies, Maharajgunj, Kathmandu, Nepal

Tel: +977-9851078622

E-mail: dr.anandasharma@gmail.com

Introduction

Leukemias are a group of heterogeneous neoplastic disorders of white blood cells which are the most frequent childhood cancers affecting children aged 2 to 10 years. They are one of the

leading causes of childhood cancer-related deaths. Ophthalmic involvement can be classified into two major categories (Sharma et al, 2004): primary or direct leukemic infiltration, and secondary or indirect involvement. The direct leukemic infiltration can be observed in three various patterns: (a) uveal infiltration, orbital infiltration, and neuro-ophthalmic signs of optic nerve infiltration (Chaudhuri et al, 2013; Lin H-F et al, 2005), (b) cranial nerve palsies, and (c) papilledema (Nguyen et al, 2013). The secondary changes are manifested as retinal or vitreous haemorrhage, infections, and vascular occlusions due to hematologic abnormalities of leukemia such as anaemia, thrombocytopenia, hyperviscosity, and immune suppression.

Estimates of the occurrence of ophthalmic manifestations of leukemia vary from 9 to 90% (Kinacid et al, 1983; Reddy & Menon, 1998). Various ocular manifestations (Reddy et al, 2003; Alemayehu, 1996) have been reported, such as bilateral serous detachment of the retina, leopard-spots pattern of the fundus (Hine & Kingham, 1979), sub-conjunctival haemorrhage (Murthy et al, 2009), acute iridocyclitis with hypopion or hyphema (Zakka KA et al., 1980), leukemic infiltration of the optic nerve (Brown GC et al, 1981), vitreous infiltrates (Zhioua, 2001), retinal haemorrhage, leukemic retinopathy (Holt & Gordon-Smith, 1969) and proptosis (Murthy et al 2009). Diffuse iris infiltration results in heterochromia iridis and in nodular involvement that usually extends to the pupillary margin (Jonston & Ware, 1973).

Knowledge regarding the ocular manifestations of leukemia is important for the diagnosis and timely management of the disease, more so as they also often reflect the disease state of the body (Kinacid & Green, 1983; Curto et al., 1989; Ohkoshi & Tsiaras, 1992; Reddy & Menon, 1998). This study, in Nepal, will provide some baseline information about the ocular involvement in childhood leukemia.

Subjects and methods

A hospital-based, cross-sectional, descriptive study was undertaken among 71 children with acute leukemia referred to the BPKLCOS during the period of January 2006 to July 2007 from the Oncology Unit of Kanti Children Hospital (KCH) and the Emergency Department of Tribhuvan University Teaching Hospital. Informed consent was received from all parents and caregivers. All children were examined by a team of ophthalmologists and ophthalmic residents irrespective of the presence or lack of eye symptoms. A detailed ocular evaluation was carried out in the eye centre and data were recorded on a specifically designed proforma.

Visual acuity was assessed by using the standard Snellen's Chart and other age appropriate tests for children, e.g., Catford drum, HOTV Chart, Lea-Symbols, were done. After performing the external eye examination with a torch light, the anterior segment examination of the eyes was performed with a slit-lamp bio-microscope. The fundus evaluation was carried out with a direct ophthalmoscope (Heine Beta-200) as well as with a binocular indirect ophthalmoscope with +20D lens after pupillary dilation with 0.5% tropicamide and 2.5% phenylephrine. Intraocular pressure was measured either with an air puff tonometer or a hand-held Perkins tonometer. Orthoptics evaluation, Hess Screen charting, diplopia charting, computerized tomography (CT) scan, magnetic resonance imaging (MRI) and ocular tissue biopsy were carried out whenever necessary. Anterior and posterior segment photography were also done whenever needed. The ocular findings in the leukemic children were divided into two categories: I. Direct ocular involvement, and, II. Secondary ocular involvement. Direct ocular involvement included (a) orbital, adnexal and anterior segment invasion, (b) retinal infiltrates and vitreous seedlings, (c) neuro-ophthalmic signs of central nervous system (CNS) leukemia, optic nerve invasion, cranial nerve palsies and

papilledema. The secondary ocular involvement findings include were lid ecchymosis, subconjunctival haemorrhage, vitreous haemorrhage, retinal haemorrhage, subretinal hemorrhage, cotton wool spots, vascular sheathings, Roth's Spots, retinal vessel tortuosity, disc edema and others. Cerebrospinal fluid (CSF) analysis and bone marrow (BM) biopsy of patients with direct ocular involvement were performed. The data were processed and analyzed with SPSS 14.0 version.

Results

Of the 71 children with acute leukemia, 52 (73.2%) were males and 19 (26.8%) females. Fifty five (77.5%; 95%CI = 66% - 85%) children suffered from acute lymphoid leukemia (ALL) and sixteen (22.5%) had acute myeloid leukemia (AML). The mean age of the cases was 7.8±4 years for ALL and 10.7± 3.3 years for AML. Only eleven children (15.4%) with leukemia had

ocular complaints. All of them complained of diminution of vision with other associated ocular complaints such as ocular pain (2.8%), redness of eyes (2.8%) and other complaints such as eyelid swelling, deviation of eye, headache and drooping of upper eyelid in 5.6% of the cases. Ocular manifestations were seen in 33(46.0%). Among the 16 cases of AML, 12 cases (75.0%) had ocular involvement where as only 21cases (38.2%) had ocular involvement among the 55 cases of ALL examined.

In the leukemic subjects, the patterns of ocular involvements were also analyzed. Among them, 5.6% of the subjects had direct ocular involvement, 29.6% had secondary ocular involvement and 11.2% had both direct and indirect involvement.

Table 1: Description of leukemia according to age, sex, symptoms, and ocular manifestations

		Total No (%)	Acute Lymphoid Leukemia No (%)	Acute Myeloid Leukemia No (%)	P value	ODD (95% CI)
Gender	Males	52 (73.2)	38 (69.1)	14 (87.5)	0.14*	0.3 (0.1-1.6)
	Females	19 (26.8)	17 (30.9)	2 (12.5)		
Mean age (SD) years		8.5±4.0	7.8±4.0	10.7±3.3	0.05**	
Symptoms		11 (15.4)	6 (10.9)	5 (31.2)	0.04*	3.8 (1.0-4.7)
Ocular involvement		33 (46.5)	21 (38.2)	12 (75.0)	0.00*	5.0 (1.4-17.5)
Ocular findings	Direct	4 (5.6)	3 (5.5)	1 (6.3)	0.89*	1.2 (0.1-12.2)
	Secondary	21 (29.6)	13 (23.6)	8 (50.0)	0.037*	3.3 (1.0-10.5)
	Both	8 (11.3)	5 (9.1)	3 (18.8)	0.27*	2.3 (0.5-11.1)

*= Chi-square test; **= Unpaired t-test

Table 2: Ocular manifestations in childhood acute leukemia

Condition	Total		Acute Lymphoid Leukemia (ALL)		Acute Myeloid Leukemia (AML)	
	Cases (n=71)	Direct involvement (n=12)	Cases (n=55)	Direct involvement (n=12)	Cases (n=16)	Direct involvement (n=12)
	No (%)	No (%)	No (%)	No (%)	No (%)	No (%)
Orbit, adnexae, and anterior segment manifestations						
Chloroma (Figure A)	1 (1.4)	1 (8.3)	-	-	1 (6.3)	1 (8.3)
Iris nodule	1 (1.4)	1 (8.3)	1 (1.8)	1 (8.3)	-	-
Glaucoma	1 (1.4)	1 (8.3)	1 (1.8)	1 (8.3)	-	-
Proptosis	2 (2.8)	2 (16.6)	1 (1.8)	1 (8.3)	1 (6.3)	1 (8.3)

Posterior segment involvement						
Retinal infiltrate	2 (2.8)	2 (16.6)	2 (3.6)	2 (16.6)	-	-
Vitreous seedlings	2 (2.8)	2 (16.6)	2 (3.6)	2 (16.6)	-	-
Neuro-ophthalmology manifestations						
Optic nerve infiltrate	5 (7.0)	5 (41.6)	4 (7.3)	4 (33.3)	1 (6.3)	1 (8.3)
3 rd , 6 th , 7 th nerve palsy	4 (5.6)	4 (33.3)	3 (5.5)	3 (25.0)	1 (6.3)	1 (8.3)
papilledema	7 (9.9)	7 (56.3)	5 (9.1)	5 (41.6)	2 (12.5)	2 (16.6)

Table 2 represents ocular manifestations in childhood acute leukemia. A total of 7% had direct orbital and anterior segment involvement including three cases (5.4%) of ALL and two cases (12.6%) of AML and total direct involvement in 41.7%. Total retina and vitreous involvement was seen in 5.6% of cases and total direct involvement was reported in 33.3% (Figure 1B). Four cases of ALL with retinal and vitreous involvement developed whitish pupillary reflex due to massive leukemic infiltrates in the retina and vitreous and developed retinal detachment in a few days (Figure 1C). Neuro-ophthalmic signs of CNS

leukemia were seen in all cases with direct ocular involvement. Optic nerve infiltration (Figure 1D) was seen in 7%, cranial nerve palsies in 5.6% (Figure 1E) and Papilledema in 9.9% (Figure 1F). Some cases had more than one direct ocular involvement.

When the patterns of secondary ocular involvements were analyzed (Table 3), 32.2% had retinal, pre-retinal or sub-retinal hemorrhage whereas retinal vascular tortuosity (19.7%) and white-centered hemorrhage (12.7%) were also commonly noted. Lid ecchymosis, abscess, vascular sheathing and cotton-wool spots were the rare presentations.

Table 3: Secondary ocular manifestations in childhood acute leukemia

Table 4 represents the presenting visual acuity in the 71 cases (142 eyes) with childhood acute leukemia. Visual acuity was recorded as less than or equal to 3/60 in 13 eyes (9.1%), and they were blind due to the ophthalmic manifestations of childhood acute leukemia.

Table 4: Presenting visual acuity inpatients with childhood acute leukemia

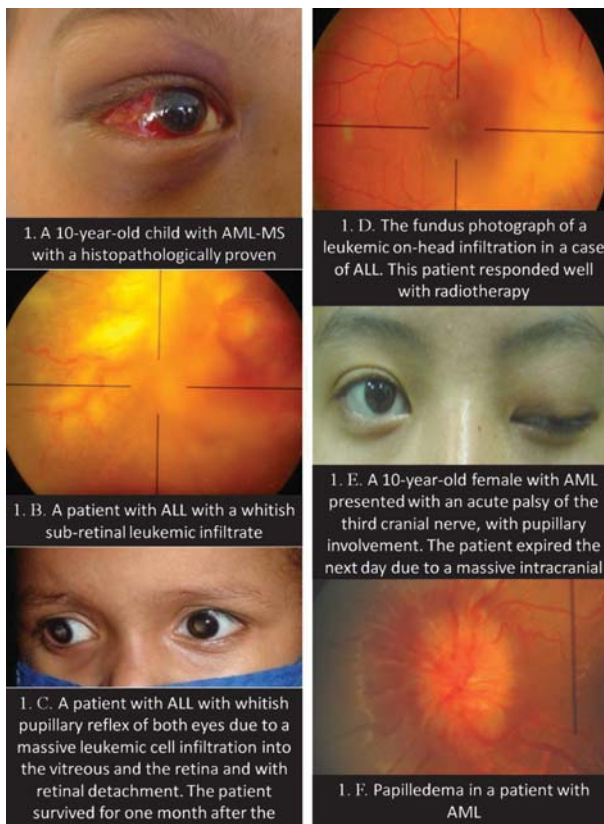
When the CSF analysis and BM examination records were analyzed, 83.3% of patients with direct ocular involvement had CSF positive for blast

cells whereas only 50% had BM positive for blast cells (Table 5).

Table 5. CSF and BM findings in leukemias with direct ocular involvement

	Total (n=12)	Acute Lymphoid Leukemia (n= 8)	Acute Myeloid Leukemia (n=4)	P* Value	OR (95% CI)
CSF for blast cells	10 (83.33)	7 (75)	3 (83.3)	0.58	0.4 (0.01-9.3)
BM for blast cells	6 (50)	4 (50)	2 (50)	1.0	1.0 (0.1-11.0)

CSF =cerebro-spinal fluid, BM =bone marrow



Discussion

Leukemias are the most frequent childhood neoplasm and one of the leading causes of childhood cancer-related deaths (Kumar et al, 2006). In most of the studies of childhood acute leukemias, ALL were more common than AML. In this study of 71 cases with childhood acute leukemias, 77 % (n=55) were ALL and 23% (n=16) AML. This finding is similar to that of the study conducted by Ridgeway et al (1976), in which 78% of the cases were of ALL, 21% of AML and 1% of non-lymphocytic

leukemia. Chronic lymphoblastic leukemia (Omoti et al, 2010) has been reported to be more common (40.4%) in adult leukemic patients, followed by chronic myeloid leukemia (29.8%), AML (19.1%) and ALL (10.6%). Similarly, Russo et al (2008) have also reported ocular manifestation in 66% of patients with AML and in 11.5% of ALL patients. Orbital or ocular lesions were noted more commonly in patients with AML (66.6%) as compared to patients with ALL (15.1%).

In our study, the age of the patients ranged from 8 months to 15 years with the mean age (SD) of 8.5±4.0 years, and the male-female ratio was 2.3:1. A study by Reddy & Menon (1998) on both childhood and adult leukemia as has reported a male-female ratio of 1.3:1.

In this study, 15% of patients (n=11) with childhood acute leukemias presented with ocular symptoms. The most common presentation was diminution of vision, in 19.7% (n=14). One case presented with a sudden onset of ptosis and had a complete 3rd nerve palsy with pupillary involvement. Massive intra-cranial bleed caused death in one of the children. One leukaemic patient with severe left lower lid abscess was found to have acute lymphoblastic leukemia (ALL). Similarly, those who had headache were diagnosed to have papilledema. Schachat et al, (1989) and Reddy & Menon (1998) reported ocular symptoms in 3% and 3.6% patients with acute childhood leukemia, respectively. We included all the sub types of childhood acute leukemia, irrespective of the duration and

treatment. All the cases were constantly instigated for any ocular complaints as well. Therefore, a high rate of symptoms is present in our study. In a study of a pathological series of leukemia, ocular involvement was reported in 80% (Kinacid et al, 1983), whereas it was reported in the range of 7-90% in various clinical series (Ridgeway et al, 1976; Reddy & Menon, 1998; Schachat et al, 1989). In our clinical study, ocular involvement was noted only in 46% of patients (n=33). In our study, ocular involvement was more common in AML (81.2%) than in ALL (38%). Similarly, Reddy & Menon (1998) have reported a more common ocular involvement in AML (41%) than in ALL (29.2%). Direct ocular manifestations were seen in 16.9% (n=12) of our patients, which is much higher (3.0%) than in the Schachat et al (1989) study. The higher prevalence in our study could be due to the enrollment of only newly-diagnosed cases. The chloroma or granulocytic sarcoma - a rare ocular manifestation commonly seen in the M4 type of AML (Champlin & Gale, 1989) was also reported in our study. In our study, optic nerve involvement was seen in 41.66% of cases (n=5) with neurological manifestations of leukemia. The optic nerve invasion of the neoplasm was observed in 15.15% of cases (n=5). Ridgeway et al (1976) reported that 31% of cases with acute childhood leukemia had optic nerve involvement. Chaudhuri et al (2013) have also reported ischaemic optic neuropathy causing blindness in a case of ALL. In our study, of 33 cases with ocular involvement, 12.12% (n=4) had cranial nerve palsies and 21.21% (n=7) had papilledema. Ridgeway et al (1976) reported papilledema in 25%. CSF and bone marrow evaluations were also performed in 12 subjects of leukemias in this study. The CSF for leukemic cells was found positive in 83.3% of cases (n=10) of direct ocular involvement and bone marrow involvement was noted in 50% (n=6) of these cases. In this study, no case of pseudohypopyon was noted, as has been reported by the Gomber et al (2008) study. In our study, secondary ocular manifestations were seen in

40.8% of cases (n=29), which is comparable with the Schachat et al (1989) report, where they were seen in 39% of cases. Among the secondary ocular manifestations, the most common manifestation was the retinal hemorrhage (32.4%), which was more common in AML (56.3%) than in ALL (25.5%). This finding is also comparable with the findings of the Schachat et al (1989) report of 24% and the Ridgeway et al (1976) report of 37%.

The visual acuity was assessed in all the cases with childhood acute leukemia. Among them, 120 eyes had a visual acuity (VA) of better than 6/18, 9 had less than 6/60 and 13 less than 3/60. Three patients had a VA of less than 3/60 in both eyes due to a dense subhyaloid premacular hemorrhage which was subjected to Nd-Yag laser hyaloidotomy resulting in an improved visual outcome (Khadka et al, 2012).

Conclusion

Though ocular symptoms were reported in a small proportion of our cases of childhood acute leukemia, a significantly high rate of ocular manifestation was found in the visually asymptomatic cases of childhood leukemia in this study. Ocular findings are more frequently observed in AML than in ALL. The posterior segment involvement causes visual impairment. Routine ophthalmic examination is recommended in all childhood leukemias.

Acknowledgement

We would like to thank Dr Kailash P Shah, Oncology Unit - Kanti Children Hospital, and Mr Suresh Sharma, Chief Ophthalmic Technologist for providing the illustrative clinical photographs and Mr Chudamani Basel, (M.Sc), for the relevant laboratory investigations.

References

Alemayehu W, Shamebo M, Bedri A, Mengistu Z (1996). Ocular manifestations of leukemia in Ethiopians. *Ethiop Med J*;34:217-224.

Allen RA, Straatsma BR (1983). Ocular involvement in leukemia and allied disorders. *Arch Ophthalmol*; 27: 211-232.

Brown GC, Shields JA, Augsburger JJ et al (1981). Leukaemic optic neuropathy. *Int Ophthalmol*; 3:111-6.

Champlin R, Gale RP (1989). Acute lymphocytic leukemia: Recent advances in biology and therapy. *Blood*; 73: 2051-2066.

Chaudhuri T, Roy S, Roy P (2013). Ischaemic optic neuropathy induced sudden blindness as an initial presentation of acute lymphoblastic leukemia. *Indian J Med PaediatrOncol*; 34(4): 335-336.

Curto Mio, Zingone A, Aquaviva A, Bagnulo S, Calculli L, Cristiani L et al (1989). Leukemic infiltration of the eye: results of therapy in a retrospective multicentric study. *Med Pediatr Oncol*; 17: 134-139.

Gomber S, Narang M, Dhaliwal U (2008). Uncommon Manifestations of Acute Lymphoblastic Leukemia (ALL). *Indian J Med Paediatr Oncol*; 29(4):34-36.

Hine JE, Kingham JD (1979). Myelogenous leukemia and bilateral exudative retinal detachment. *Ann Ophthalmol*; 11:1867-1872.

Holt JM, Gordon-Smith EC. (1969). Retinal abnormalities in diseases of blood. *Br J Ophthalmol*; 53: 145-160.

Jonston SS, Ware F. (1973). Iris involvement in leukemia. *Br J Ophthalmol*; 57:320-4.

Khadka D, Sharma AK, Shrestha JK, Pant B, Pant S, Shrestha A (2012). Nd: Yag laser treatment for sub-hyaloidhemorrhage in childhood acute leukemia. *Nepal J Ophthalmol*; 4 (7):102-107.

Kinacid MC, Green WR (1983). Ocular and orbital involvement in Leukemia. *Surv Ophthalmol* 1983; 27:211-233.

Kumar V, Abbas A, Fausto N (2006). Robbins and Cotran Pathologic basis of disease. In: anirban Maitra, Vinay Kumar eds. Diseases of childhood and infancy. 7th Edition, Elsevier Inc, 469-508.

Lin H-F, Dai M-S, Kao W-Y, Chao T-Y (2005). Unilateral Optic Nerve Leukaemic Infiltration with Sudden Vision Loss Heralding a Systemic Relapse of Acute Lymphoblastic Leukemia. *J Med Sci*;25(2):097-100.

Murthy R, Vemuganti GK, Honavar SG, Naik M, Reddy V (2009). Extramedullary leukemia in children presenting with proptosis. *J hematol Oncol*; 2:4.

Nguyen HS, Haider KM, Ackerman LL (2013). Unusual causes of papilledema: Two illustrative cases. *Surg Neurol Int*;4:60.

Ohkoshi K, Tsiaras WG (1992). Prognostic importance of ophthalmic manifestations in childhood leukemia. *Br J Ophthalmol*; 76: 651-655.

Omoti AE, Omoti CE, Momoh RO (2010). Ocular disorders in adult leukemia patients in Nigeria. *Middle East Afr J Ophthalmol*;17 (2):165-8.

Reddy SC, Menon BS. (1998). A prospective study of ocular manifestations in childhood acute leukemia. *Acta Ophthalmol Scand*; 76:700-703.

Reddy SC, Jackson N, Menon BS (2003). Ocular involvement in Leukemia: A study of 288 cases. *Ophthalmologica*; 217:441-446.

Ridgeway EW, Jaffe N, Walton DS, (1976). Leukaemicophthalmopathy in children. *Cancer*; 38: 1744-1749.

Russo V, Scott IU, Querques G, Stella A, Barone A, Delle NN (2008). Orbital and ocular manifestations of acute childhood leukemia: clinical and statistical analysis of 180 patients. *Eur J Ophthalmol*;18(4):619-23.

Schachat AP, Markowitz JA, Guyer DR, Burke PJ, Karp JE, Graham ML (1989).



Ophthalmic manifestations of leukemia. Arch Ophthalmol; 107:697-700.

Sharma T, Grewal J, Gupta S, Murray PI (2004). Ophthalmic manifestations of acute leukemias: The ophthalmologist's role. Eye; 18: 663-672.

Zakka KA, Yee RD, Shorr N, et al (1980). Leukaemic iris infiltration. Am J Ophthalmol 1980; 89:204-9.

Zhioua R, Boussen I, Malek I, Ouertani A. (2001). Acute lymphoblastic leukemia and vitreous infiltration: A case study. J Francais Ophthalmol; 24:180-182.

Source of support: nil. Conflict of interest: none