

Case Report

Acanthamoeba Keratitis – A Case Report

Leesha Shrestha Joshi¹, Reeta Gurung²

¹Consultant, Department of cornea, Kedia eye hospital, Birgunj

²Senior Consultant, Department of cornea, TIO, Gaushala, Kathmandu

Abstract

Introduction: Acanthamoeba keratitis is a serious infection of the cornea which causes severe inflammation of the eye and loss of vision.

Case description: A 45 years female came with a history of trauma of right eye with vegetative matter with severe pain and redness. Patient was treated with antibacterial, antifungal eye drops but the condition deteriorated. Diagnosis was based on presence of motile trophozoites and cyst in the culture of non nutrient agar with a lawn of E coli of the corneal ulcer scraping. Therapeutic penetrating keratoplasty was performed as the patient's condition deteriorated.

Conclusion: Acanthamoeba keratitis is a rare parasitic vision threatening infection with poor prognosis in comparison to other infectious keratitis. Therefore prevention is very important.

Key words: Acanthamoeba keratitis, Trophozoites, Cyst.

Introduction

Acanthamoeba keratitis is a serious infection of cornea which causes severe inflammation of the eye and loss of vision. In 1973 the first case of acanthamoeba keratitis was recognized. The disease was rare until 1980 and later it was increased in incidence due to uses of contact lenses. (Christopher D et al, 1998).

The clinical picture may be severe pain associated with superficial keratitis to stromal thinning typical ring infiltrate and perforation.

The choices of drugs used in the treatment of acanthamoeba keratitis are propamidine isethionate, clotrimazole, polyhexamethylene biguanide and chlorhexidine are suggested.

Therapeutic keratoplasty is performed in severe acanthamoeba keratitis but not as initial treatment (John K.G Dart, 2009).

Case report

A 45 years old female patient presented with complaints of pain, redness and watering in the right eye for ten days with a history of minor

Financial Interest: Nil

Conflict of Interest: Nil

Received: 07.07.2020 Accepted: 28.12.2020

Corresponding author

Dr. Leesha Shrestha Joshi
Kedia Eye Hospital, Birgunj, Nepal
E-mail: shreslisa@yahoo.com

Access this article online

Website: www.nepjol.info/index.php/NEPJOPH

DOI: <https://doi.org/10.3126/nepjoph.v13i1.29912>

Copyright © 2021 Nepal Ophthalmic Society

ISSN: 2072-6805, E-ISSN: 2091-0320



This work is licensed under a Creative Commons Attribution-NonCommercial-NoDerivatives 4.0 International License (CC BY-NC-ND).

trauma in the right eye with some vegetative matter. On examination vision in the right eye was finger count and in the left eye 6/9. The right eye showed epithelial defect in the paracentral cornea measuring 3.5mm vertically and 3mm horizontally. Few DM folds were present and corneal sensation was decreased moderately. A corneal scraping was performed but was negative for microorganisms. Patient was treated as a viral infection, the patient's condition deteriorated. Pain and the size of epithelial defect was increased invading deep stroma with ring infiltrate.

So rescraping was done suspecting *Acanthamoeba* in a non-nutrient agar with a lawn of *E. coli*. There was presence of motile trophozoites and cyst which was suggestive of *acanthamoeba*. As the anti amoebic drugs were not available in Nepal, patient was treated with antifungal and antibacterial drugs. But the condition of the patient deteriorated, so therapeutic penetrating keratoplasty performed with antifungal, antibacterial, steroid and antiglaucoma drugs. Patient was stable for a few months. No recurrence of infection. But after 1 year the patient developed failed graft, secondary glaucoma and cataract. So the patient was planned for regrant with lens extraction and intraocular lens.

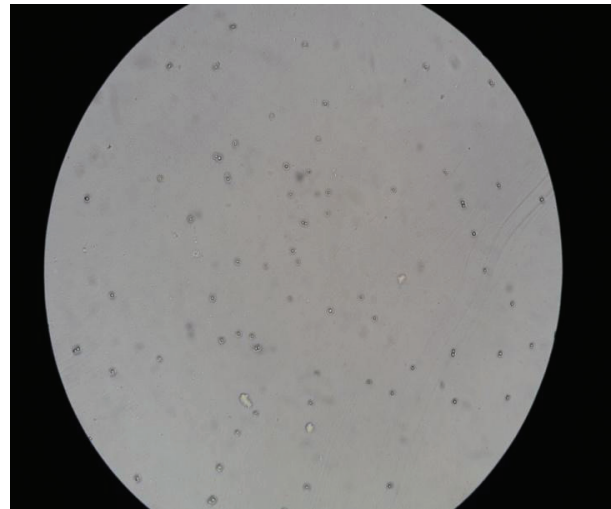


Figure 2: *Acanthamoeba* cyst

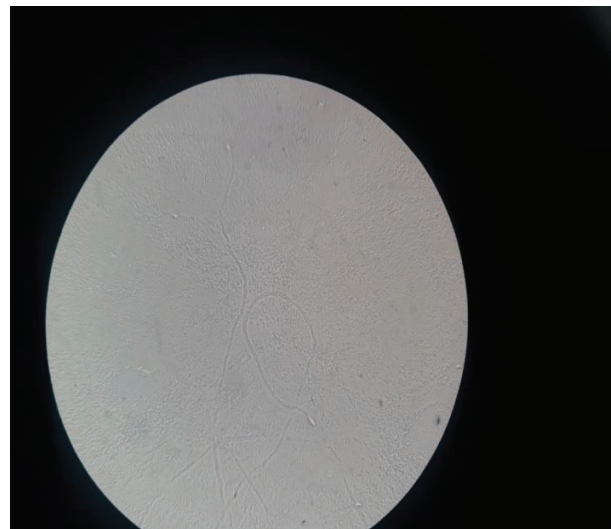

Figure 3: *Acanthamoeba* trophozoite

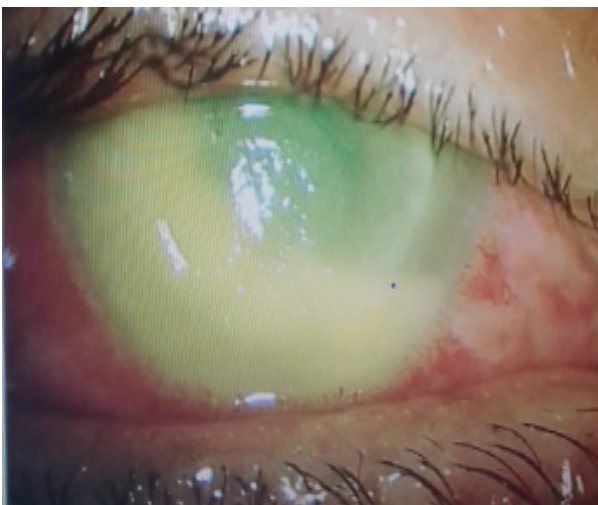


Figure 1: *Acanthamoeba* keratitis

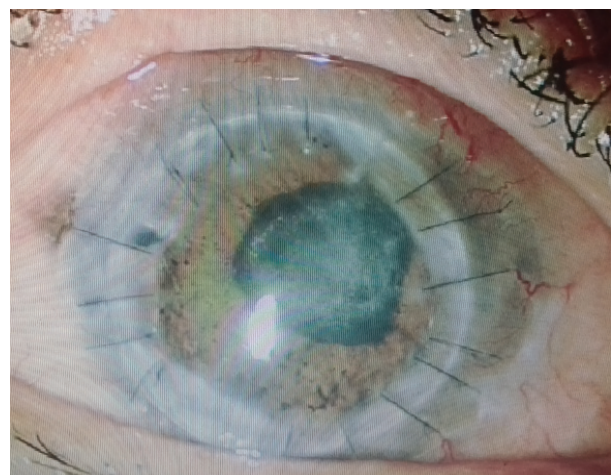

Figure 4: After therapeutic keratoplasty

Discussion

Acanthamoeba keratitis is a severe sight threatening infection of the cornea causing severe ocular inflammation and loss of vision. Acanthamoeba keratitis accounts for 2% in India of all cases of culture positive corneal ulcers (Garg P et al, 2017).

The main predisposing factors for acanthamoeba keratitis is trauma and exposure to contaminated water or soil which are not associated with contact lens (Mascarenhas J et al, 2014; Sharma S et al, 2000; Manikandan P et al 2004; Bashir G et al, 2005). In this study also trauma was the predisposing factor for developing acanthamoeba keratitis.

Mohammad Hossein Feiz reported that pain is one of the most important sign. Patient complains of severe pain which is more than imagination (Mohammad Hossein Feiz et al, 2019). In this case also patient complained of severe pain. In the early stages, most of the cases are misdiagnosed as viral keratitis and symptoms are difficult to associate. Patients may present with punctate epithelial erosions to deep stromal edema involving endothelium which was similar to this case.

The diagnosis of acanthamoeba keratitis can be made by clinical features, confocal microscopy, culture on non-nutrient agar supplemented with E coli, histopathological examination and PCR. In this study acanthamoeba keratitis was confirmed by observing trophozoites and cyst on culture on non nutrient agar with E coli (Mohammad Hossein Feiz et al, 2019).

The treatment of acanthamoeba keratitis is very difficult as the medicines which are available are effective only in trophozoites form. The common medicines used in keratitis are brolene drop 0.1%, propamidine isethionate, polyhexamethylene biguanide, chlorhexidine, neomycin, imidazoles (Bang S et al, 2010). As these medicines were not available in our country patient was prescribed antifungal and antibacterial medication. But the patient

was poorly responded to topical therapy and underwent therapeutic penetrating keratoplasty similar to study done by Jing Zhong et al (Jing Zhong et al, 2017)

Conclusion

It is a rare vision threatening parasite infection. The prognosis for acanthamoeba is worse in comparison to other infectious keratitis. Therefore prevention is very important as the treatment is lengthy and not necessarily effective.

Acknowledgement

We would like to thank the faculties, fellows of the cornea department and microbiologist of Tilganga institute of ophthalmology for their support.

References

- Bang S, Edell E, Eghrari AO, Gottsch JD (2010). Treatment with voriconazole in 3 eyes with resistant Acanthamoeba keratitis. *AmJ Ophthalmol*; 149(1):66-9. DOI: 10.1016/j.ajo.2009.08.004
- Bashir G, Rizwi A, Shah A, Shakeel S, Fazili T (2005). Acanthamoeba keratitis in Kashmir. *Indian J Pathol Microbiol*; 48 : 417.
- Christopher D, Stuart D (1998). Acanthamoeba keratitis. *Survey of ophthalmology*; 42(6) : 493–508. DOI: [https://doi.org/10.1016/S0039-6257\(98\)00004-6](https://doi.org/10.1016/S0039-6257(98)00004-6)
- Dart JK, Saw VP, Kilvington S (2009). Acanthamoeba keratitis: diagnosis and treatment update 2009. *American Journal of Ophthalmology*; 148(4) : 487–99.
- Garg P, Kalra P, Joseph J. Non-contact lens related Acanthamoeba keratitis. *Indian J Ophthalmol*. 2017 Nov; 65(11) : 1079–86. DOI: 10.4103/ijo.IJO_826_17
- Haddad MH, Shokri A, Habibpour H, Nejadi S M (2019). A review of Acanthamoeba keratitis in the middle East and Iran. *Journal of acute disease*; 8 (4) : 133- 41.



Manikandan P, Bhaskar M, Revathy R, John RK, Narendran V, Panneerselvam K, et al (2004). *Acanthamoeba keratitis – A six year epidemiological review from a tertiary care eye hospital in South India. Indian J Med Microbiol; 22 : 226–30.*

Mascarenhas J, Lalitha P, Prajna NV, Srinivasan M, Das M, D'Silva SS, et al (2014). *Acanthamoeba, fungal, and bacterial keratitis: A comparison of risk factors and clinical features. Am J Ophthalmol; 157 : 56–62.*

Sharma S, Garg P, Rao GN (2000). *Patient characteristics, diagnosis, and treatment of non-contact lens related Acanthamoeba keratitis. Br J Ophthalmol; 84 :1103–8.*

Zhong J, Li X, Deng Y, Chen L, Zhou S, Huang W, Lin S, Yuan J (2017). *Associated factors, diagnosis and management of Acanthamoeba keratitis in a referral Center in Southern China. Zhong et al. BMC Ophthalmology; 17 : 175. DOI 10.1186/s12886-017-0571-7*