

Original Article

Assessing Profile and Treatment Outcome in Patients of Ocular Surface Squamous Neoplasia (OSSN)

Eliya Shrestha¹; Laxman Banstola²; Indra Man Maharjan¹; Babita Gurung¹; Harimaya Gurung¹; Hari Bikram Adhikari¹; Isha Karmacharya¹

¹Himalaya Eye Hospital, Gharipatan, Pokhara-17, Nepal

²Western Regional Hospital, Ranipauwa, Pokhara-11, Nepal

Abstract

Purpose: This study has attempted to assess the profile and treatment outcome of patients with OSSN and report the recurrence rate following treatment of primary OSSN.

Materials and Methods: This was a retrospective, non-comparative hospital based observational study. The case files of OSSN patients from Jan 2010 to Dec 2017 were assessed. The study site was Himalaya Eye Hospital, Gharipatan, Pokhara. This hospital is the only eye hospital in province 4, Nepal. All the files of suspicious cases of conjunctival mass or OSSN were reviewed. Data regarding demographic characteristics, vision acuity, involved eye, clinical features, conjunctival lesion type, duration of symptoms, preoperative clinical diagnosis, history, other eye disease, associated systemic diseases, occupation as well as treatment modalities of the patients and its outcome were taken.

Results: Out of 40 cases, females were 21(52.5%) versus 19(47.5%) male. Among them, 19 patients had keratinized stratified squamous epithelium, 17 had conjunctival intraepithelial squamous neoplasia and 4 had invasive squamous cell carcinoma. Predominance age group was 15-59 age (25/40, 62.5%), among which 12 had keratinized stratified squamous epithelium, 11 conjunctival intraepithelial squamous neoplasia and 2 had invasive squamous cell carcinoma conjunctival lesion. The mean duration of symptoms was about nine months (S.D. = 5.972). The mean size of lesion mass was 3.28 mm (SD=1.569). More than half of the cases (55%, 22/40) had the mass located at nasal limbus. 95% (38/40) cases underwent lesion total excision and direct closure and 5% (2/40) underwent lesion excision followed by Amniotic Membrane grafting. Only 5% (2/40) cases, those who had undergone lesion excision, the lesion recurrence was observed during follow up period of 31 months.

Conclusion: The outcome of the OSSN following the treatment was found to be satisfactory. Further studies with prolonged follow-up are recommended to evaluate the risk of recurrence and other adverse effects.

Key words: Amniotic Membrane Graft, Ocular Surface Squamous Neoplasia, Treatment Outcome, Recurrence

Financial Interest: Nil
Conflict of Interest: Nil
Received: 04.12.2018

Accepted: 12.03.2019

Corresponding author
Dr. Eliya Shrestha
Deputy Medical Director, Himalaya Eye Hospital
Email: eliya.sth12@gmail.com,
Phone: +977-9846086534

Introduction

Corneo-conjunctival intraepithelial neoplasia (CIN) and carcinoma together called Ocular Surface Squamous Neoplasia (OSSN) (Waddell et al,2010) comprises of a range of simple dysplasia to carcinoma in situ to invasive squamous cell carcinoma, involving the conjunctiva as well as the cornea (Lee and Hirst,1992). Primary surgical excision remains the mainstay of treatment but the recurrence rate is high (Lee and Hirst,1995). The disadvantage of primary excision alone is the recurrence of OSSN which ranges from 15% to 52% (Kaines et al,2005;Honavar and Manjandavida,2015). Various adjunctive therapies have been described (Lee and Hirst,1995). Mitomycin-C (MMC) has been recommended for treatment of recurrent OSSN (Daniell et al,2002; Khokhar et al,2002). This study presents a series of eyes with localized primary OSSN treated with surgical excision or with topical MMC alone or with combined. In cases with very large lesion involving more than 4 clock hours leaving very less healthy conjunctiva, the area was covered by Amniotic Membrane Graft (AMG). The aim of this study was to assess the profile and treatment outcome of patients with OSSN and report the recurrence rate following treatment of primary OSSN.

Methods and Materials

This study was formally reviewed and approved by the Nepal Health Research Council and permitted by Himalaya Eye Hospital. This study adhered to the tenets of the Declaration of Helsinki.

This was a retrospective, non-comparative hospital based observational study. The OSSN case records between January 2010 and July 2017 were assessed. The study site was Himalaya Eye Hospital, Gharipatan, Pokhara. This hospital is the only eye hospital in Gandaki Zone, Nepal (Sharma) which was established on March 1993 at Pokhara (Barros et al,2014),

to serve the people of Gandaki, Dhaulagiri and Karnali zones in Western Nepal (three out of 14 zones of Nepal). All the files of cases suspected as conjunctival OSSN were reviewed. There were 67 cases with suspicious lesion of OSSN. All were treated with topical Mitomycin C before surgery at least for three weeks. Twenty cases had resolved the lesion treated with topical Mitomycin C alone and seven cases did not come for follow up. So these 27 cases were not included in our study. The cases diagnosed and treated in other hospital and came for follow up in HEH and those patients whose data were incomplete were excluded from study.

Data regarding demographic characteristics (age, gender, occupation), visual acuity, clinical features (involved eye, redness, irritation, mass growth, foreign body sensation, pain), duration of symptoms, history (other ocular disease, associated systemic diseases), preoperative clinical diagnosis, conjunctival lesion type, treatment modalities of the patients and its outcome (recurrence) were entered in MS EXCEL 2010. Regarding the conjunctival lesion type, Benign lesion included fibrovascular tissue lined by stratified squamous epithelium, pinguecula, squamous papilloma, benign cystic lesion, nevocellular nevus, granulation tissue, keratinized stratified squamous epithelium and chronic inflammatory lesion; Pre-cancerous lesion included CIN, conjunctival squamous intraepithelial neoplasia, squamous cell carcinoma in situ and moderate/severe dysplasia of squamous epithelium; and Malignancy included well-differentiated/invasive squamous cell carcinoma. The data were analyzed in SPSS version 22. Descriptive statistics were used for demographic characteristics and the data being presented as frequency, percentages, mean, and standard deviation.

Results

Demographic and Clinical Details

A total of 40 cases (40 eyes) were included in

the study. By gender, females were predominant (52.5% versus 47.5%) among which majority had benign conjunctival lesion. Predominance age group was 15-59 age 50%), among which high proportion had benign and pre-cancerous conjunctival lesion. (Table 1)

The visual acuity of 24 cases was found to be 6/6, followed by six cases with 6/9 vision, four with 6/36 vision, three cases with 6/18 vision, two cases with 6/12 vision and only one case with 6/60 vision. Of 40 patients, 12.5% (5/40) were smokers; none of them had any associated systemic diseases like diabetes, cancer, eczema, HIV infection, and so on. None of the patients had other ocular disease except pinguecula in 13 cases and pterygium in one case. None of the cases had history of using steroid and methotrexate or had the previous history of ocular trauma or surgery unrelated to OSSN.

Clinical Features and Preoperative Clinical Diagnosis

For 18 cases, the right eye was involved in the OSSN, and the left eye in 22 cases. Only unilateral involvement was found in all cases. The 72.5% (29/40) cases had redness, 15% (6/40) cases had reported eye irritation, 65% (26/40) cases had reported foreign body sensation, and none of the cases had reported pain in the eye. Mass growth in the eye was found in all the cases. The mean duration of symptoms was about nine months (S.D. = 5.972) ranging from one month to 36 months. Majority of the cases had the symptoms for 6-12 months, i.e. 57.5% (23/40) cases, followed by less than six months (16 cases) and more than a year (one case).

Of 40 cases, the mean size of lesion mass was 3.28 mm (SD=1.569). More than half of the cases (55%, 22/40) had the mass located at nasal limbus. (Table 2)

Treatment Details and Outcome

All 40 cases were treated with topical Mitomycin C before surgery at least for three weeks, followed by surgical excision with histopathological examination. Out of 40 cases, 95% (38/40) cases underwent lesion excision which included none touch technique plus de-epithelization with alcohol plus cryotherapy. 3-4mm apparently healthy conjunctiva was excised in all cases and sent for histopathological examination. The histopathological report of 19 patients had keratinized stratified squamous epithelium, 17 had conjunctival intraepithelial squamous neoplasia and 4 had invasive squamous cell carcinoma. The 5% (2/40) underwent lesion excision which included none touch technique plus de-epithelization with alcohol wash plus cryotherapy followed by Amniotic Membrane Grafting. This was because the lesion was very large leaving very less healthy conjunctiva so the area had to be covered by AMG. None of the cases had experienced complications during the surgery. 95%(38/40) cases were given postoperatively Mitomycin C. Those two patients who showed post-operative limbal stem cell deficiency leading to prolonged superficial punctate keratitis were not given Mitomycin C. The follow up duration ranged from one month to 61 months, with intervals of three visits. Only in the two cases, those who underwent lesion excision alone, the lesion recurrence was observed during follow up period of 31 months. (Table 3)

Table 1: Demographic Characteristics of Participants with Ocular Surface Squamous Neoplasia (OSSN) and Lesion type

Demographic Characteristics	Number	Percent	Conjunctival Lesion Type, No. (%)		
			Benign	Pre-cancerous	Malignancy
Age					
0 - 14	3	7.5	3 (100.0)		
15 - 59	25	62.5	12 (48.0)	11 (44.0)	2 (8.0)
60 and above	12	30.0	4 (33.3)	6 (50.0)	2 (16.7)
Mean = 46.08 21.006 years; Min ^m = 5; Max ^m = 88					
Sex					
Male	19	47.5	8 (42.1)	8 (42.1)	3 (15.8)
Female	21	52.5	11 (52.4)	9 (42.9)	1 (4.8)
Occupation					
Housewife	21	52.5	9 (42.9)	10 (47.6)	2 (9.5)
Student	5	12.5	5 (100)		
Farmer	12	30.0	3 (25.0)	7 (58.3)	2 (16.7)
Service	2	5.0	2 (100)		

Table 2: Size of Mass in the Eye, Cornea Involvement and Lesion Location

	Number	Percent
Size of Mass		
≤ 3	26	65.0
> 3	14	35.0
Mean = 3.28 ±1.569 mm; Min ^m = 1; Max ^m = 9		
Cornea Involvement		
Yes	30	75.0
No	10	25.0
Lesion location		
Nasal limbus	22	55.0
Temporal limbus	13	32.5
Superior limbus	4	10.0
Circumlimbal	1	2.5

Table 3. Treatment Details and Outcome

	Number	Percent
Primary Treatment		
Excision	38	95.0
Excision + AMG	2	5.0
Complication		
Yes	0	0.0
No	40	100.0
Recurrence		
Yes	2	5.0
No	38	95.0

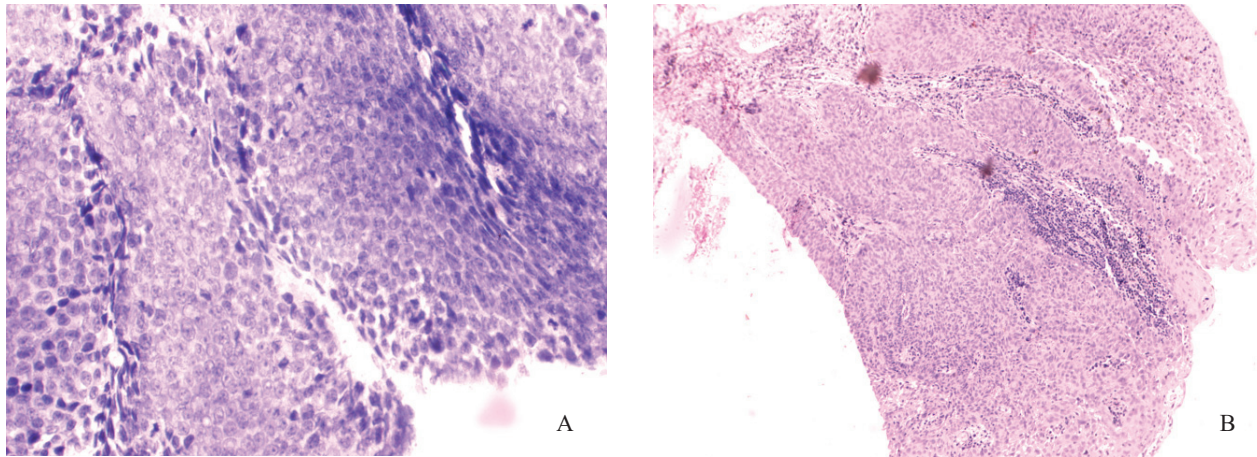


Figure 1 (A) Histologic sections showing soft tissue focally lined by squamous epithelium with changes of invasive squamous cell carcinoma (H&E stain), **(B)** Histologic sections showing soft tissue with atypical mitotic figure (H&E stain)

Discussion

This study has attempted to assess profile and treatment outcome in patients of ocular surface squamous neoplasia, which showed that benign conjunctival lesions were the most common type of lesions similar to study done in Iran (Aliakbar-Navahi et al,2015). More than 90% cases were above 15 years of age as shown in this study, however, several studies showed that there is chance of development of OSSN in early age if the patient is suffering from Xeroderma pigmentosum (Gupta et al, 2011;Kalamkar et al,2016). Beside Xeroderma pigmentosa there have been reports of OSSN found in patients suffering from various systemic diseases like Hepatitis C, HIV(Human Immunodeficiency Virus), HPV(Human Papilloma Virus) (Choi et al,2017). However, none of the patients under this study were suffering from Xeroderma pigmentosa, HIV or HPV. Mean age of the patients was 46.08 years which is close to 45.20 years in the study done by Dandala (2015a).

This study showed that OSSN was seen more prevalent in females than males, similar to the report from Zimbabwe, where females (70%) outnumbered males (Pola et al., 2003). Also, OSSN was seen more prevalent among

housewives, followed by farmers. In contrast to this finding, a study done in India depicts that increased incidence of OSSN was observed more in males and people with outdoor occupations (Dandala et al,2015b). It is evident that sun exposure is one of the important risk factors for the presence of OSSN (Dandala et al,2015a, Gichuhi et al,2016; Gichuhi et al,2013). Since, women are overburdened with agricultural works and household chores (Gurung et al,2005), both indoors and outdoors, this may explain the prevalence of OSSN more in females and housewives as depicted in this study, however, further studies are required to validate this finding.

None of our patients had bilateral involvement. Bilateral involvement of OSSN is very rare though very few reports have been found (Usui et al,2004; Grueb et al,2006; Gericke et al, 2008; Masanganise et al, 2010; Agarwal et al, 2017). The most common location of OSSN was nasal limbus similar to other studies (Gichuhi et al, 2015; Dandala et al, 2015a). Studies have revealed that the limbus receives direct sunlight temporally which is focused nasally, thus the nasal limbus receives the highest intensity of sunlight (Gichuhi et al, 2014; Wolffsohn et

al, 2014). Regarding the treatment outcomes of lesion excision alone or with AMG, the results are found to be satisfactory with no complications similar to other studies (Fasina, 2015; Sturges et al, 2008; Bahrami et al, 2014). However, there was recurrence in 2 out of 40 patients who underwent lesion excision alone in contrast to study done in Nigeria which showed no recurrence (Fasina,2015). Nevertheless, studies have reported that recurrence rate of OSSN can range from 15% to 52% (Honavar and Manjandavida,2015; Lee and Hirst,1995). However, the recurrence rate can be limited to <5% (Honavar and Manjandavida,2015) as found in this study may be due to adjuvant topical mitomycin C. Instead of mitomycin C use of adjuvant interferon-alpha-2b (IFN-alpha-2b) has been reported with good results (Blasi et al,2018). Topical chemotherapy alone with IFN-alpha-2b and 5 fluorouracil in combination or alone without surgical intervention has also been reported (Chaugule et al,2018). However in our situation because of less availability of these expensive medicine we are still using the surgery as primary mode of treatment of OSSN.

Conclusion

Altogether there were 40 OSSN patients among which more than half were females. OSSN was majorly found in working age group 15-59 years of age and mostly in housewives followed by farmers. Benign conjunctival lesions were the most common type of lesions. None of the patients had bilateral involvement. The most common location of OSSN was nasal limbus. The outcome of the OSSN following the treatment was found to be satisfactory with 5% recurrence. Further studies with prolonged follow-up are recommended to evaluate the risk of recurrence and other adverse effects. Also, further studies are required to find the risk factors associated with OSSN via mediation model.

References

- Agarwal R, Chawla B, Asif M I, Pujari A (2017). Bilateral ocular surface squamous neoplasia with bilateral periocular basal cell carcinoma in a case of xeroderma pigmentosum. *BMJ Case Rep*;2017.
- Aliakbar-Navahi R, Ashraf M J, Seirfar N, Koohestani S, Abedi E (2015). Conjunctival Lesions: a histopathologic review in fars province, Iran. *Journal of Ophthalmic & Vision Research*;10: 98-101.
- Bahrami B, Greenwell T; Muecke J S (2014). Long-term outcomes after adjunctive topical 5-fluorouracil or mitomycin C for the treatment of surgically excised, localized ocular surface squamous neoplasia. *Clin Exp Ophthalmol*;42:317-22.
- Barros J D, Lowen M S, Moraes-Filho M N, Martins M C (2014). Use of impression cytology for the detection of unsuspected ocular surface squamous neoplasia cells in pterygia. *Arq Bras Oftalmol*;77:305-309.
- Blasi M A, Maceroni M, Sammarco M G, Pagliara M M (2018). Mitomycin C or interferon as adjuvant therapy to surgery for ocular surface squamous neoplasia: comparative study. *Eur J Ophthalmol*;28:204-209.
- Chaugule S S, Park J, Finger P T (2018). Topical chemotherapy for giant ocular surface squamous neoplasia of the conjunctiva and cornea: Is surgery necessary? *Indian J Ophthalmol*;66:55-60.
- Choi C J, Jakobiec F A, Zakka F R, Sanchez A V, Lee N G (2017). Ocular Surface Squamous Neoplasia in a Patient With Hepatitis C. *JAMA Ophthalmol*;135:1121-1123.
- Dandala P P, Malladi P, Kavitha (2015a). Ocular Surface Squamous Neoplasia (OSSN): A Retrospective Study. *J Clin Diagn Res*; 9: NC10-3.

Dandala P P, Malladi P, Kavitha (2015b). Ocular Surface Squamous Neoplasia (OSSN): A Retrospective Study. *Journal of Clinical and Diagnostic Research : J Clin Diagn Res*; 9:NC10-NC13.

Daniell M, Maini R, Tole D (2002). Use of mitomycin C in the treatment of corneal conjunctival intraepithelial neoplasia. *Clin Exp Ophthalmol*;30: 94-8.

Fasina O (2015). Ocular surface squamous neoplasia in Ibadan, Nigeria. *Asian Journal of Oncology*; 1: 101-105.

Gericke A, Pitz S, Stempel I, Sekundo W (2008). Bilateral ocular surface squamous neoplasia and neurodermatitis. Two cases with different courses. *Ophthalmologie*;105:1142-5.

Gichuhi S, Macharia E, Kabiru J, Zindamoyen A M, Rono H, Ollando E, Wachira J, Munene R, Onyuma T, Jaoko W G, Sagoo M S, Weiss H A, Burton M J (2016). Risk factors for ocular surface squamous neoplasia in Kenya: a case-control study. *Trop Med Int Health*;21:1522-1530.

Gichuhi S, Macharia E, Kabiru J, Zindamoyen A M, Rono H, Ollando E, Wanyonyi L, Wachira J, Munene R, Onyuma T, Jaoko W G, Sagoo M S, Weiss H A, Burton M J (2015). Clinical Presentation of Ocular Surface Squamous Neoplasia in Kenya. *JAMA Ophthalmol*, 133, 1305-13.

Gichuhi S, Ohnuma S, Sagoo M S, Burton M J. (2014). Pathophysiology of ocular surface squamous neoplasia. *Exp Eye Res*;129:172-82.

Gichuhi S, Sagoo M S, Weiss H A, Burton M J (2013). Epidemiology of ocular surface squamous neoplasia in Africa. *Trop Med Int Health*;18:1424-43.

Grueb M, Rohrbach J M, Kroeber S M (2006). Bilateral ocular surface squamous neoplasia after wood dust exposure. *Acta Oncol*;45:218-9.

Gupta N, Sachdev R, Tandon R (2011). Ocular surface squamous neoplasia in xeroderma pigmentosum: clinical spectrum and outcome. *Graefes Arch Clin Exp Ophthalmol*;249:1217-21.

Gurung K, Tulachan P M, Gauchan D (2005). Gender and Social Dynamics in Livestock Management: A Case Study from Three Ecological Zones in Nepal Center for Mountain Research Development (CEMORD)

Honavar S, Manjandavida, F (2015). Tumors of the ocular surface: A review. *Indian Journal of Ophthalmology*;63:187-203.

Kaines A, Davis G, Selva D, Leibovitch I, Dodd T, Malhotra R (2005). Conjunctival squamous cell carcinoma with perineural invasion resulting in death. *Ophthalmic Surg Lasers Imaging*;36: 249-51.

Kalamkar C, Radke N, Mukherjee A, Radke S (2016). Xeroderma pigmentosum with bilateral ocular surface squamous neoplasia and review of the literature. *BMJ Case Rep*;2016.

Khokhar, S., Soni, A., Singhsethi, H., Sudan, R., Sony, P. & Pangtey, M. S. (2002). Combined surgery, cryotherapy, and mitomycin-C for recurrent ocular surface squamous neoplasia. *Cornea*, 21, 189-91.

Lee G A, Hirst L W (1992). Incidence of ocular surface epithelial dysplasia in metropolitan Brisbane. A 10-year survey. *Arch Ophthalmol*;110:525-7.

Lee G A, Hirst L W (1995). Ocular surface squamous neoplasia. *Surv Ophthalmol*;39:429-50.

Masanganise R, Mukome A, Dari J, Makunike-Mutasa R (2010). Bilateral HIV related ocular surface squamous neoplasia: a paradigm shift. *Cent Afr J Med*; 56: 23-6.

Pola E C, Masanganise R, Rusakaniko S (2003). The trend of ocular surface squamous neoplasia among ocular surface tumour



biopsies submitted for histology from Sekuru Kaguvi Eye Unit, Harare between 1996 and 2000. *Cent Afr J Med*; 49:1-4.

Sharma, M. K. *Over Arching Issues in Eye Care: Challenges and Need for Advocacy.* Lumbini Eye Institute.

Sturges A, Butt A L, Lai J E, Chodosh J (2008). Topical interferon or surgical excision for the management of primary ocular surface squamous neoplasia. *Ophthalmology*; 115:1297-302 (1302 e1).

Usui Y, Waring G O, See R F, Rao N A, Marrone A C (2004). Bilateral ocular surface squamous neoplasia: a clinicopathological case report. *Br J Ophthalmol*; 88:595-6.

Waddell K, Kwehangana J, Johnston W T, Lucas S, Newton R (2010). A case-control study of ocular surface squamous neoplasia (OSSN) in Uganda. *Int J Cancer*; 127:427-32.

Wolffsohn J S, Drew T, Sulley A (2014). Conjunctival UV autofluorescence--prevalence and risk factors. *Contact Lens and Anterior Eye*; 37: 427-430.