

Case Report

An Unusual case of neurocysticercosis leading to blindness in a young Indian male

Meenakshi Wadhvani¹, Ananya Panda², Rajpal Vohra³, Achal Kumar Srivastava⁴

¹Department of Ophthalmology, Chacha Nehru Bal Chikitsalya, New Delhi

²Department of Radiology, AIIMS, New Delhi India

³DR Rajendra Prasad Centre for Ophthalmic Sciences, AIIMS, New Delhi, India

⁴Department of Neurology, AIIMS, New Delhi, India

Abstract

Neurocysticercosis is an endemic disease in India. It is caused by infection from the larval form of *Taenia solium* and humans serve as the intermediate host. Its diverse manifestations include seizures, headaches, focal neurological signs. Obstructive hydrocephalus, with its potential for death is the most disastrous complication. We hereby report a case of 24 year old boy presenting with blindness without hydrocephalus.

Key words: Neurocysticercosis, taenia solium, blindness

Introduction

Neurocysticercosis was first described by Rumler in 1558 and is a very common helminthic reaction of the central nervous system. It is an important biological marker of social and economic development of the country (Carpio et al, 1998). Neuro ophthalmic signs usually are characterized by papilledema with or without third ventricular dilatation (Keane et al, 1982, Del Brutto et al, 1996).

Case presentation

A 24 year old boy presented to Eye clinic with complaints of sudden painless loss of vision in both eyes over a period of one week. There was no history of trauma, drug intake, headache and vomiting. There were no systemic complaints.

On Ocular examination his visual acuity in both eyes was inability to perceive light in both eyes. Direct and indirect pupillary reaction were absent. His intraocular pressures were 12 and 14 mm Hg in right and left eye respectively. The ocular movement was normal in all gazes. Rest of the anterior and posterior segment examination was normal. General physical examination and systemic (including neurological) examination was within normal limits. Haematological and biochemical tests were within normal limits. HIV test was negative.

Contrast enhanced CT scan of head and orbit revealed brain parenchyma was studded with multiple cysts of varying ages, including calcified lesions suggestive of miliary form of neurocysticercosis. Bilateral optic nerve sheath complex were thickened with two discrete cysticerci lesions in right lateral rectus muscle. (Figure 1, 2) A provisional diagnosis of miliary neurocysticercosis with orbital involvement was made. Rest of the walls of the orbit and the brain parenchyma was normal. There was

Financial Interest: Nil

Conflict of Interest: Nil

Received: 12.06.2018

Accepted: 20.11.2018

Corresponding author

Meenakshi Wadhvani

Assistant Professor, Department of ophthalmology,

Chacha Nehru Bal Chikitsalya, New Delhi

E-mail: mkgang08@gmail.com

no hydrocephalus. A provisional diagnosis of neurocysticercosis with ocular involvement was done. The patient was referred to neurology department where he was treated with oral steroids (Intravenous pulse steroids for three days and oral methyl prednisolone 1mg/dl for fifteen days). On subsequent followup his visual status and pupillary reactions did not improve.

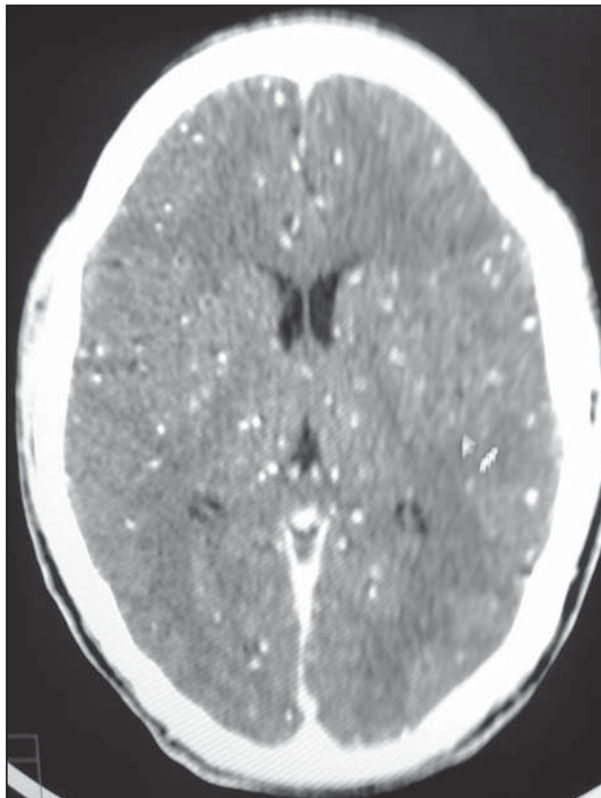


Figure 1: Contrast enhanced CT scan of brain at the level of lateral ventricles shows multiple neurocysticerci in varying stages, studding the entire brain parenchyma. There is no hydrocephalus

Discussion

Cysticercosis can involve various sites like brain, heart, eyes, subcutaneous tissue and peritoneum. It occurs as an important health problem in developing countries like India. It is a chronic, self limited disease that affects young

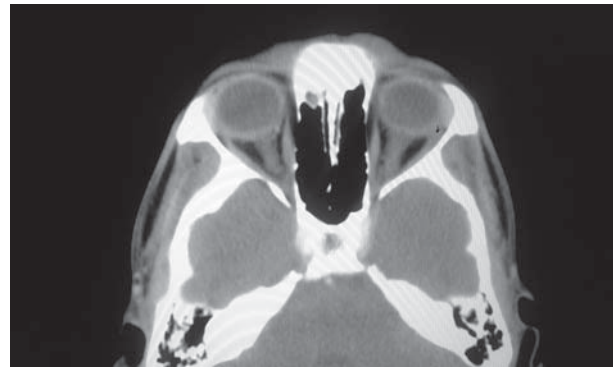


Figure 2: Contrast enhanced CT scan of orbit shows a rim enhancing cystic lesion with central scolex involving the right lateral rectus muscle (arrow).

adults. Intraocular involvement by cysticercosis occurs in about 3% of the cases (Prasad et al, 2008). The chief aetiology is uncooked food and improperly washed vegetables, although it is also commonly found in pork consumers (Anand et al, 2014, Keane et al, 1984)

The diagnosis of cysticercosis is based on clinical, serological and imaging findings. Clinical and serological examination is often nondiagnostic to rule out cysticercosis. Both CT scan and MRI are helpful in establishing the diagnosis of cysticercosis. There are four stages of evolution of cysticercosis namely, vesicular, colloidal vesicular, granular nodular and nodular calcified. It is important to monitor visual loss as it can be affected due to invasion along the course of visual pathways (Chang et al 2001). The most common fundus presentation is papilledema due to inflammation of optic nerve; profound visual loss up to extent of PL negative is very rare. The main reason for vision loss was due to chiasmal lesion leading to optic nerve compression therefore optic disc edema and secondary optic atrophy due to prolonged disc edema. It is important to monitor visual loss as it can be affected due to invasion along the course of visual pathways (Prasad et al, 2008). The most common fundus presentation is papilledema due to

inflammation of optic nerve; profound visual loss up to extent of PL negative is very rare. In Index case although treatment was started immediately but patient had already lost vision at the time of presentation. Chang et al, 2001 in his case series of 23 cases of visual loss in cysticercosis reported 2 cases of patients with no perception of light in both eyes but both these cases presented with hydrocephalus, The unique presentation of blindness but without hydrocephalus in neurocysticercosis is not reported to the best of our knowledge.

Medical management is the main stay of treatment in the form of systemic methyl prednisolone and albendazole, although Albendazole is always given along with high dose of corticosteroids and antiseizure medication to prevent side effects due to larval migration. Surgical therapy for neurocysticercosis is indicated for emergency treatment of hydrocephalus, in the form of ventriculoperitoneal shunt or optic nerve fenestration to salvage vision (Keane et al, 1984). Surgery was not done due to lack of signs of hydrocephalus. The patient belonged to lower socioeconomic strata and was lost to followup after one month of treatment, the last evaluation of posterior segment revealed secondary optic atrophy.

To conclude, cysticercosis is an underestimated hazard due to lack of epidemiological data. Awareness regarding clean hygienic and

cooking practices can lead to prevention and eradication of this entity, also prompt treatment with the aid of imaging can prevent further visual loss in case of this entity.

References

- Anand S, Arun M.S, Javid ASM, Manam A, Radhakrishnan A and Padma V (2014). Unusual Presentations of Neurocysticercosis: *World Journal of Medical Sciences*; 10 (4): 436-442.
- Carpio A, Escobar A and Hauser WA (1998). Cysticercosis and epilepsy: a critical review. *Epilepsia*; 39: 1025-1040.
- Chang GY, Keane JR (2001). Visual loss in cysticercosis analysis of 23 patients. *Neurology*; 57:545-547.
- Del Brutto OH, Wadia NH, Dumas MCruz M, Tsang VC, Schantz PM (1996). Proposal of diagnostic criteria for human cysticercosis and neurocysticercosis. *J Neurol Sci*; 142:1-6.
- Keane JR (1982). Neuro-ophthalmologic signs and symptoms of cysticercosis. *Arch Ophthalmol*; 100:1445-1448.
- Keane JR (1984). Death from cysticercosis: seven patients with unrecognized obstructive hydrocephalus. *Wes J Med*; 140: 787-789.
- Prasad K, Prasad A, Verma A and Singh AK (2008). Human cysticercosis and Indian scenario: A review. *J Biosci*; 33(4): 571-582.