

Case Report

Orbital Myocysticercosis different Presentation and Management in Eastern Nepal

Diwa Hamal¹, Santosh Kafle¹, Purna Arjyal Kafle¹, Prija Poudyal¹,
Binaya Lamichhane¹, Ben Limbu²

¹Biratnagar Eye Hospital, Biratnagar, Nepal

²Tilganga Eye Hospital, Kathmandu, Nepal

Abstract

Introduction: Ocular cysticercosis is a preventable cause of blindness. It is caused by parasitic infestation caused by the larval form of *Taenia solium*. Poor sanitation and improper management of food and meat products are the major causes for cysticercosis infestation.

Case: Two cases of myocysticercosis presented to our hospital differently. A 12 years boy, first case presented with drooping of right eye (RE) upper lid with recurrent swelling, pain, redness with mild headache and intermittent vomiting for 1 and half months. On examination swelling of RE upper lid, mild ptosis, abaxial proptosis with restricted motility in upgaze was noted. Orbital CT (computer tomography) scan and ocular ultrasound reports showed findings suggestive of myocysticercosis of superior rectus muscle of RE. Routine microscopic examination (RME) of stool demonstrated eggs of *Taenia*. Complete blood count (CBC) showed eosinophilia. As a suspected case of myocysticercosis and since the patient resided at an endemic zone, empirical therapy with albendazole and steroid was started to continue for 4 weeks. After one week the patient presented with features suggestive of RE orbital cellulitis. With proper counseling about medical therapy and cyst excision, the patient recovered well with only mild RE upper lid ptosis of 2mm. The histopathological examination (HPE) of the excised cyst was suggestive of inflammatory cystic lesion. A 55 years male presented as a second case to us with gradually increasing mass in the RE lower lid with a history of pain, difficulty in opening RE and intermittent swelling of RE 2 months back. On examination RE lower lid mass with exotropia of 15 degree, mild hypertropia was noted. CT scan showed presence of cystic mass 3.5x2x1.5cm in the right orbit involving the right inferior rectus muscle, abutting and displacing the globe superolaterally. CBC showed eosinophilia. Post cyst excision patient recovered well with remaining mild restriction in infraduction most probably due to fibrosis. HPE was conclusive of cysticercus cellulosae. Both the patients improved well with no recurrence until last visit 17 months in 12 years boy and 6 months in 55 years male after which he lost to follow.

Financial Interest: Nil

Conflict of Interest: Nil

Received: 09.07.2019

Accepted: 12.11.2019

Corresponding author

Dr. Diwa Hamal

Oculoplasty surgeon

Biratnagar eye hospital, Rani- 13, Biratnagar.

Contact: 9851012243

E-mail: diwa222@hotmail.com

Conclusion: Myocysticercosis can occur at any age. There is equal importance of clinical, radiological, microbiological and histopathological support for proper diagnosis and management of cysticercosis. Medical therapy along with surgical excision of the cyst with its content may be needed in the management of myocysticercosis.

Key words: Ocular cysticercosis, Myocysticercosis, *Taenia solium*.

Introduction

Ocular Cysticercosis is a preventable cause of blindness. It is caused by a parasitic

infestation by the larval form of *Taenia solium*. Among all ophthalmic cases 5 to 8.4% of orbit and adnexa is infected (Witting, 2001; Atul K et al, 1995). The extraocular muscle is commonly involved in orbital and adnexal cysticercosis (Sekhar GC et al, 1997), leading to restricted eye movements and inflammatory signs (Pushker N et al, 2001). In 1829, Soemmering reported the first case of a live anterior chamber cysticercosis. There is no sex predilection with more inclination towards children and young adults (Lombardo J, 2001; Pushker N, 2002).

Case 1

A 12 years old boy presented with drooping of right eye (RE) upper lid with recurrent swelling, pain, redness since one and half months. That was also associated with mild headache and intermittent vomiting. He had no history of systemic disease. There was no abnormality in his general physical examination. He has no history of trauma.

His best-corrected visual acuity (BCVA) was 6/9 in his RE and 6/6 in his left eye (LE) on presentation. Examination of RE showed fullness in upper lid, mild ptosis, proptosis with restricted ocular motility in upgaze. His forced duction test of RE was positive for superior rectus (SR). Restriction was noted since the eye could not be placed in supraduction. Ptosis evaluation showed RE {IPF (Inter palpebral fissure height)- 6mm, MRD₁ (marginal reflex distance)- 0mm, LPS (Levator palpebrae superioris muscle) function- 7mm, Bell's phenomenon- good, MGJW

(Marcus Gunn jaw winking) phenomenon- absent, corneal sensation- Normal), LE (IPF- 9mm, MRD₁- +3mm, LPS function- 12mm, Bell's phenomenon- good, MGJW- absent, corneal sensation- Normal). The icepack test and fatigability tests were negative. His conjunctiva, cornea, anterior chamber, pupil, lens and the posterior segment all were normal in BE. Exophthalmometry showed inferonasal proptosis of 5mm in RE more than LE. Intra ocular pressure (IOP) was 20 mm of mercury in RE and 18 mm of mercury in LE. CT brain and orbit revealed 1.5cm hypodense cystic lesion in right superior rectus muscle causing inferior displacement of right globe suggestive of myocysticercosis.

USG orbit showed a cyst in the right superior rectus muscle with the features suggestive of myocysticercosis. RME (Routine microscopic examination) of stool showed presence of eggs of *Taenia*, and we found eosinophilia in blood examination. Based on the evidence of history, examination, stool examination, imaging findings, patient residing at endemic zone of cysticercosis the diagnosis of myocysticercosis of the right superior rectus was made empirically.

Patient was then started medical therapy with oral steroid (prednisolone acetate) 1mg/kg body weight daily followed by albendazole 15 mg/kg daily 2 days later. After one week the patient returned with massive chemosis, ptosis, proptosis, sluggish pupillary reaction, decreased vision to HM (hand movement) with

severe restriction in ocular movement showing features of orbital cellulitis.

Due to worsening symptom of patient and profound reduction of his vision he was admitted at hospital and advised for iv dexamethasone 5mg intravenous four times daily along with oral albendazole 15 mg per kg daily, iv antibiotics, oral seratopeptidase, topical ofloxacin eye drops for 1 week. His BCVA in RE gradually improved to 6/60 then to 6/36 and chemosis, proptosis improved. Because he improved with medical treatment from hospital he was discharged after 1week treatment in hospital but he again returned with decreased vision, lid edema, diffuse chemosis and restricted ocular motility within another week. Due to recurrent inflammatory presentation we suspect the compliance of patient to medical therapy, therefore we decide to perform anterior orbitotomy which was performed through upper forniceal approach at week 4 of patient presentation.

The cyst ruptured on the table with copious purulent material spilled out. The cyst wall with the content was sent for HPE (histopathological examination). Oral antibiotics, topical antibiotics, oral seratopeptidase was advised for 1 week and oral steroid was advised for 1 week and tapered in every 3 days then after. On discharge his vision was 6/12 RE, mild chemosis and extraocular movement (EOM) was slightly restricted to upgaze. Six months postoperative follow up his BCVA was 6/6 BE, mild ptosis RE, EOM was normal in BE, anterior and posterior segment was normal. Ptosis evaluation showed RE (IPF- 7mm, MRD₁- +2mm, LPS function-10mm), LE (IPF- 9mm, MRD₁- +3mm, LPS function-12mm). He had mild ptosis of 2mm with no recurrence until his last visit at seventeen months postoperatively and is under regular follow up.

Histopathological examination showed mass with fibrocollagenous tissue lined by chronic inflammatory cells infiltrate predominantly

comprising of mature lymphocytes, histiocytes some with foamy cytoplasm and plasma cells. The cells at places were seen embedded within the interstitium of edematous and hemorrhagic fibrocollagenous as well as adipose tissue stromal background. The cysticercus cellulosae, scolex was not seen.

Case 2

A 55 years male presented with one month history of gradually increasing mass in the right lower lid. He had a history of pain, difficulty in opening RE and intermittent swelling of RE 2 months back. He has no documentation of past treatment history. He has no history of systemic illness in the past. There was no abnormality in his general physical examination. He has no history of head, ocular trauma or surgery.

Examination revealed BCVA to be 6/9 in BE. EOM was restricted in infraduction and adduction in RE. There was no diplopia. He had 15 degree exotropia and mild hypertropia of RE. His forced duction test of RE was positive for inferior rectus and middle rectus. Restriction was noted since the eye could not be placed in infraduction and adduction. There was approximately 10x10mm size mobile, non tender mass in his right lower eyelid. RE upper lid was normal. The anterior and posterior segments of BE showed no significant findings. IOP in RE was 30 and LE was 10 mm of mercury.

CT orbit was done that showed 3.5x2x1.5cm cystic mass in the right orbit involving the right inferior rectus muscle, abutting and displacing the globe superolaterally with normal brain scan. Stool examination was normal but CBC showed eosinophilia. Inferior orbitotomy by right lower fornix approach with excision of the cyst was planned. The cyst burst and copious purulent discharge came out during surgery then that was sent for HPE.

On the first post operative day his BCVA was 6/9 BE, IOP, pupillary reaction was normal,

EOM showed slight limitation of movement to infraduction. He was discharged with one week of oral, topical antibiotics, oral seratopeptidase and analgesics. Oral steroid was advised to taper in 3 weeks.

Three weeks postoperatively swelling subsided BCVA was 6/6 BE and his EOM was still restricted in infraduction most probably due to fibrosis.

With HPE report of the patient we diagnosed it as a case of mycysticercosis as mentioned in figure 10. There was no recurrence until 6 months postoperative period then after he lost to follow.

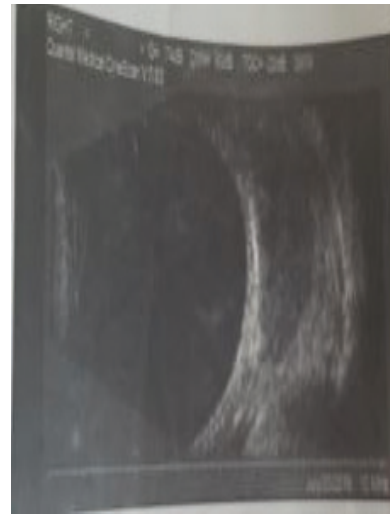

Figure 3: Ultrasonography (USG) B scan image showing fluid filled cystic lesion in superior rectus right eye.

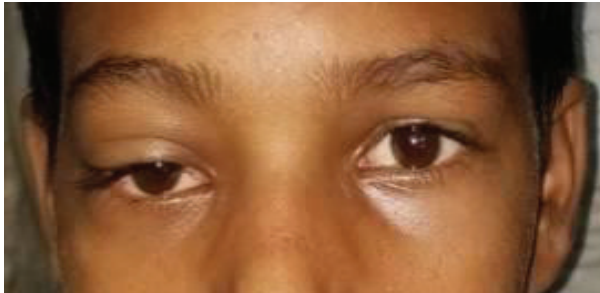

Figure 1: Clinical picture of patient with right upper lid mild ptosis, proptosis, fullness of right upper eyelid.

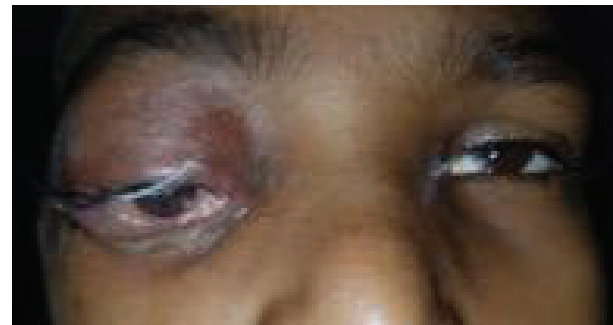


Figure 4: Clinical picture of patient showing massive chemosis, ptosis, proptosis of right eye.

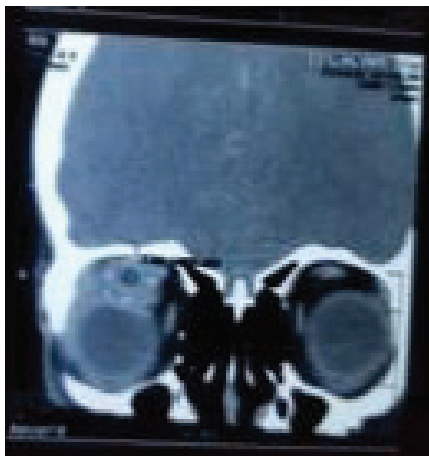

Figure 2: Showed CT brain and orbit revealed 1.5cm hypodense cystic lesion in right superior rectus muscle showing faint enhancement of the margin, causing inferior displacement of right globe suggestive of mycysticercosis.

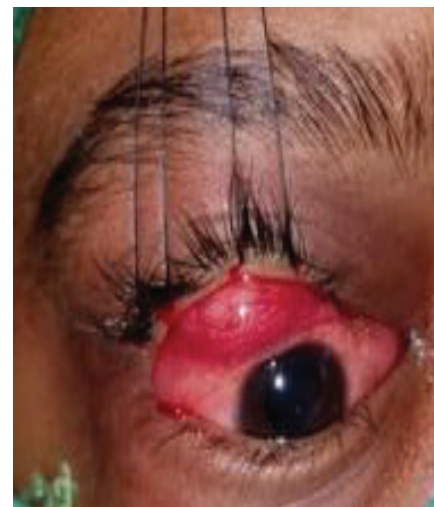

Figure 5: Upper fornix cystic swelling with congested conjunctiva in the operation table.

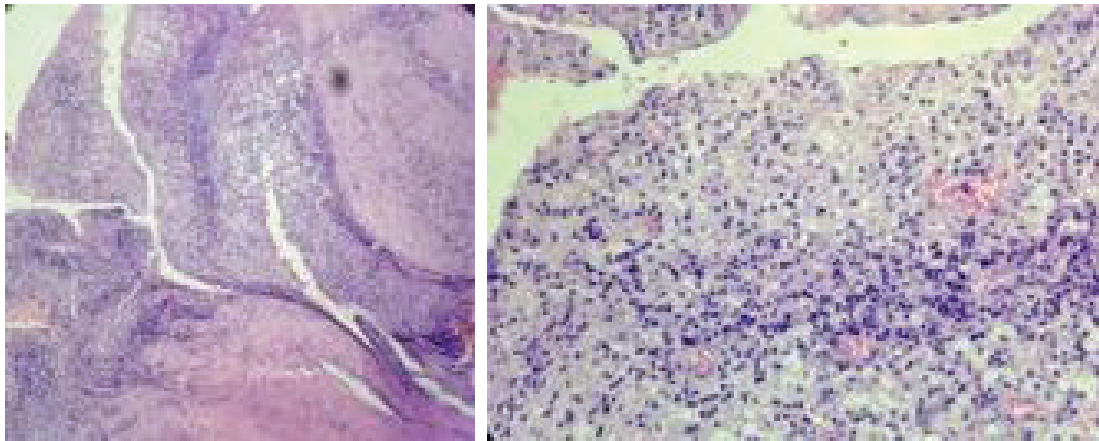


Figure 6: Cystic structure lined by mixed inflammatory cells infiltrate, Figure a: H&E stain X 10, Figure b: H&E stain X 40, Chronic inflammatory cells comprising predominantly of mature lymphocytes and histiocytes with foamy cytoplasm.

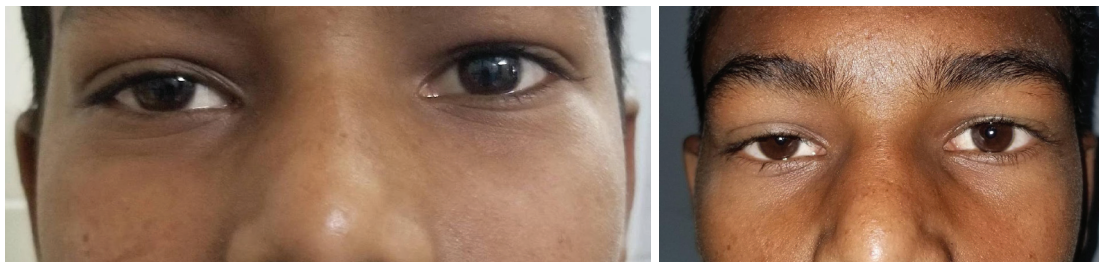


Figure 7(a): Six months post operative picture of the patient showing mild ptosis, puffiness of RE upper lid with no proptosis.

Figure 7(b): Seventeen months post operative picture of the patient with mild ptosis of RE.

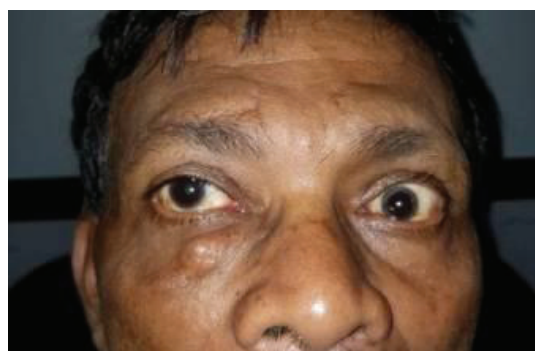


Figure 8: Clinical picture of patient with right eye lower lid mass extending from inferonasal orbit approximately 10x10mm size deviating the globe superolaterally.

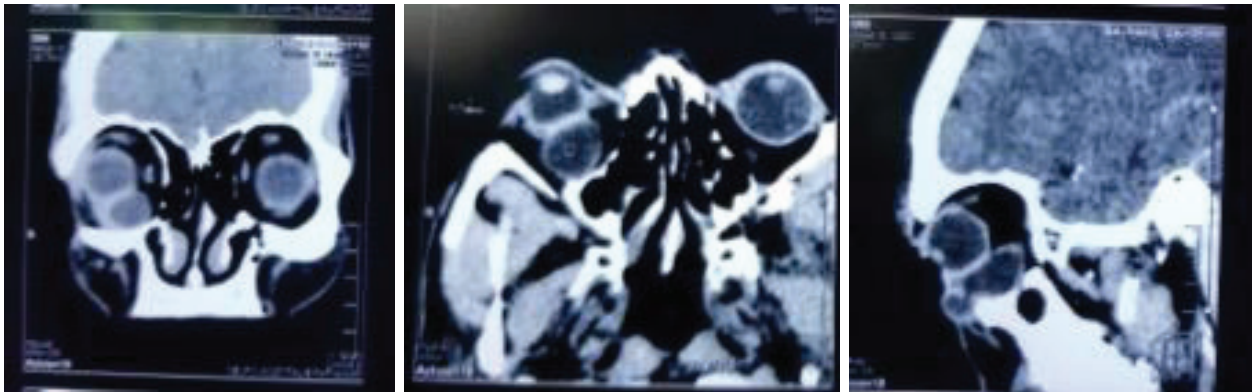

Figure 9: CT head and orbit showing 3.5x2x1.5cm hypodense cystic mass with thin enhancing wall in right orbit involving the right inferior rectus muscle, abutting and displacing the globe superolaterally, extending beyond the orbital margin into the adjacent soft tissue.

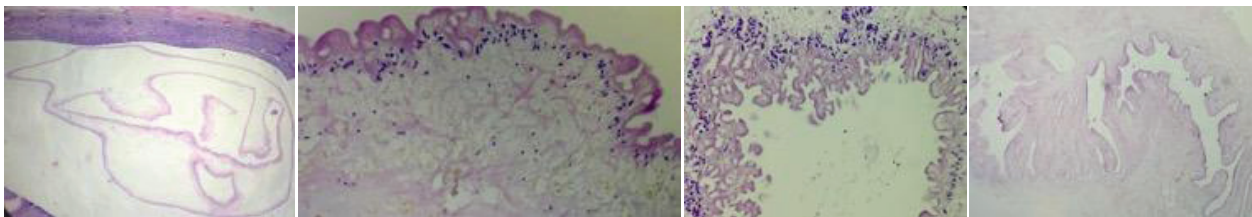


Figure 10a: The HPE showing cystic space containing the cysticercus cellulosae (H&E stain X10)

10b & 10c: Showing cycticercus cellulosae lined by three layers: inner cuticular, middle granular and outer loose parenchymatous lining layers (H&E stain X60)

10d: Showing the scolex with duct-like invagination-lined by eosinophilic membrane (H&E stain X60).

Discussion

Orbital and adnexal cysticercosis can present with various clinical presentation. There are reports of lateral rectus muscles and superior rectus muscle involvement (Sundaram PM, 2004). Lacrimal sac, Subconjunctival space, eyelid, optic nerve and retro-orbital space are the common locations of cysticercosis (Raoot A, 2014). In our first case superior rectus was affected with fibrosis leading to hypotropia, limitation of supraduction with massive orbital cellulitis like feature. In second case the inferior rectus was affected leading to mild hypertropia, exotropia and limitation of infraduction.

Patients can present with periorcular swelling, diplopia, proptosis, ptosis, pain restriction

of ocular motility, strabismus, lid edema, decreased vision and also features of orbital cellulitis. There is subconjunctival presentation if the cyst extrudes from the primary extra ocular muscle site (Sundaram PM et al, 2014). There is a rare case report of multiple brain neurocysticercosis associated with ocular cysticercosis involving superior rectus (SR) muscle and levator palpebrae superioris (LPS) (Verma Ret al, 2013). There are rare case report of involvement of LPS and SR muscle with ocular cysticercosis (Sekhar GC et al, 1997; Agrawal S et al, 2017).

Orbital cysticercosis has various differential diagnosis that includes myositis, benign or malignant tumours, metastasis, hydatid cyst,

muscle abscess or haematoma. The diagnosis of orbital and adnexal cysticercosis is done based on the clinical, serological, radiological and histopathological reports. The clinical findings can sometimes be non-specific and serology may show false positive reports so, imaging studies and histopathology can be most helpful in establishing the final diagnosis. In the suspected cases of cysticercosis microbiological examination of the stool for the adult worm is performed.

A well-defined cyst with a hyperechoic scolex is seen on ocular USG (ultrasonography) B-scan (Honavar SG et al, 1998). The scolex shows a high amplitude spike in A- scan due to presence of calcareous corpuscles (Rahalkar MD et al, 2000). A hypodense mass with a central hyperdensity suggestive of scolex is seen in CT scan of the orbit. If the cyst is dead or ruptured and has surrounding inflammation the scolex may not be visible as in our first case. Concurrent neurocysticercosis should always be excluded (Pushker N et al, 2002). A hypointense cystic lesion and hyperintense scolex within the extraocular muscle is seen in MRI. A complete blood count may report eosinophilia (Murthy GR et al, 1980).

Excision biopsy is done to confirm the diagnosis in cases of subconjunctival cyst. In all cases of ocular cysticercosis CT scan imaging is always done to rule out neurocysticercosis. CT imaging helps to rule out any cystic intramuscular lesion with scolex in cases with proptosis, ptosis, restricted motility or inflammation. If cyst with scolex is seen or ELISA is positive, oral albendazole (15 mg/kg) and oral steroid (prednisolone 1 mg/kg) are given (Sihota R et al, 1994). In cystic lesion without scolex or ELISA is negative, oral steroids must be prescribed if the patient is from cysticercosis endemic zone empirical therapy with albendazole with steroid is to be given for 4 to 6 weeks. For the extraocular muscle form and retro-orbital cysticercosis medical therapy is recommended

(Mohan K et al, 2005). For subconjunctival and eyelid cysticercosis surgical removal is recommended.

Cysticercosis occurs due to improper hygiene and sanitary conditions. Health education of the population regarding proper hygiene is important for disease control. Consumption of fully cooked pork, washing of raw vegetables and fruits before eating, proper hands hygiene after using toilets, before food handling are very important preventive actions.

Early treatment with oral albendazole, corticosteroids and cyst removal helps to restore normal function early (Pushker N et al, 2001; Mohan K et al, 2005). Motility restriction can persist if the diagnosis is delayed.

Conclusion

Our case emphasize that myocysticercosis can occur at any age with varied presentation as ptosis, proptosis, squint or orbital cellulitis. Inferior rectus muscle and superior rectus muscles are equally important location of Cysticercosis. There is equal role of clinical, radiological, microbiological and histopathological support for proper diagnosis and management of cysticercosis. Education about the importance of drug intake both the steroid and albendazole should be well explained to the patient to avoid delay in recovery. Only medical therapy may not treat cases with extraocular muscle form as surgical excision of the cyst with its content may be needed as in our cases. Poor drug compliance can lead to lengthening of the treatment duration leading to complications.

References

- Agrawal S, Ranjan S, Mishra A (2013). Ocular myocysticercosis: an unusual case of ptosis. *Nepal J Ophthalmol*; 5 (2): 279–81.
- Atul K, Kumar TH, Mallika G, Sandip M (1995). Socio-demographic trends in ocular cysticercosis. *Acta Ophthalmol Scand*; 73 (5): 438-41.

- Honavar SG, Sekhar CG (1998). Ultrasonological characteristics of extraocular cysticercosis. *Orbit*; 17 (4): 271–84.
- Lombardo J (2001). Subretinal cysticercosis. *Optom Vis Sci.*; 78 (4):188–94.
- Murthy GR, Rao AV (1980). Subconjunctival cysticercosis. *Indian J Ophthalmol*; 28(2): 77–8.
- Mohan K, Saroha V, Sharma A, Pandav S, Singh U (2005). Extraocular muscle cysticercosis: clinical presentations and outcome of treatment. *J Pediatr Ophthalmol Strabismus*; 42(1): 28–33.
- Pushker N, Bajaj MS (2002). Betharia SM. Orbital and adnexal cysticercosis. *Clin Exp Ophthalmol*; 30(5): 322–33.
- Pushker N, Pushker N, Bajaj MS, Chandra M, Neena (2001). Ocular and orbital cysticercosis. *Acta Ophthalmol Scand*; 79(4): 408-13.
- Rahalkar MD, Shetty DD, Kelkar AB, Kelkar AA, Kinare AS, Ambardekar ST (2000). The many faces of cysticercosis. *Clin Radiol*; 55(9): 668–74.
- Raoot A (2014). Lacrimal sac cysticercosis: a rare site for manifestation. *Case Rep Ophthalmol Med*; 961815.
- Sekhar GC, Lemke BN (1997). Orbital cysticercosis. *Ophthalmology*; 104 (10): 1599-604.
- Sihota R, Honavar SG (1994). Oral albendazole in the management of extraocular cysticercosis. *Br J Ophthalmol*; 78(8):621–23.
- Sommering ST (1830). *Über einen Cysticercus cellulosaе im Menschlichen Auge.* *Oken's Iseis.* ;8: 717–8.
- Sundaram PM, Jayakumar N, Noronha V (2004). Extraocular muscle cysticercosis-a clinical challenge to the ophthalmologists. *Orbit*; 23(4): 255–62.
- Verma R, Jaiswal A (2013). Multiple brain parenchymal neurocysticercosis with extraocular muscle cysticercosis affecting levator palpebral superioris and superior rectus complex: an unusual association. *BMJ Case Rep.* 2013. pii: bcr 2012007421.
- Wittig EO (2001). Ocular cysticercosis: an epidemiological study. *Arq Neuropsiquiatr*; 59 (3-B): 696-701.