

## Original Article

# Profile of Corneal Ulcer in a Month of harvesting Season in a Tertiary Level Eye Hospital of Eastern Nepal

Vijay Gautam, Abinash Chaudhary, Sanjay Kumar Singh, Pooja Gautam Rai  
Sagarmatha Choudhary Eye Hospital, Lahan, Siraha, Nepal

## Abstract

**Introduction:** Agricultural workers are prone to corneal injuries due to vegetative trauma especially during the harvesting season. This study reports the number of new cases of corneal injuries and corneal ulcer presenting in a month of harvesting season.

**Methods:** This is a cross-sectional, hospital based study of all new cases of corneal injury and corneal ulcer presenting to the cornea department from 1<sup>st</sup> November, 2016 to 30<sup>th</sup> November, 2016. Typical or suspected cases of corneal ulcer of viral, immunologic or metabolic causes were excluded. Detailed history and clinical examination was carried out. Corneal scrapes in cases with corneal ulcer were taken and subjected to direct microscopy. Details of the findings were recorded in a proforma designed for the study. Statistical analysis was done by SPSS 18. **Results:** 259 cases presented during that period. Females were more affected (54%). Fifty-one percent of the cases presented from Nepal. Forty-eight percent gave history of ocular trauma by vegetative material. 40% presented within a week of development of symptoms, and about 40% after 2 weeks. Fifty percent of the cases had not presented to an eye care professional. 9% were using topical steroids. Progressive status of the disease was noted in 80%. Sixty-five percent presented with corneal ulcer of less than 2 mm size. Direct smear examination was carried out in 105 cases and 73% of them showed fungal elements. **Conclusion:** Awareness of agriculture related corneal injuries due to trauma by vegetative materials and methods to prevent such injuries is very important.

**Key words:** Corneal Injury, Corneal ulcer, Vegetative material, harvesting season

## Introduction

Corneal ulceration is the second most common cause of unilateral blindness after cataract in developing countries (Upadhyay MP et al, 1991; Whitcher JP et al 2001). According to Upadhyay et al, incidence of corneal ulceration

in Nepal was 799/100000 population per year (Upadhyay MP et al, 1991). Seasonal variation in the incidence is well noticed with high incidence of corneal ulceration during the harvesting season (Basak SK et al, 2005; Dhakhwa K et al, 2012; Sitoula RP et al, 2015; Bandyopadhyay S et al, 2012). Agricultural workers seem to be at greatest risk of developing fungal keratitis and the inciting agent is usually a minor trauma with a vegetative foreign body (Goel R et al, 2013). Most of the patients that presented to the cornea department of our hospital had agricultural background.

**Financial interest:** Nil

**Conflict of interest:** Nil

Received: 21.04.2017

Accepted: 20.11.2017

**Corresponding author**

Dr. Vijay Gautam, MD

Sagarmatha Choudhary Eye Hospital, Lahan, Siraha, Nepal

Phone: 00977-9849445566

Fax: 00977-33-560492

E-mail: vjay.gautam@gmail.com

Lack of awareness regarding corneal ulceration among the patients is one of the main causes for delayed presentation in developing countries like Nepal (Sitoula RP et al, 2015). Both bacterial and fungal keratitis in developing countries can be prevented with the grass roots public health structure that is currently in place even in the poorest countries (Upadhyay MP et al, 2007).

We carried out this study in cornea department of our hospital to report the high number of cases with corneal injury and corneal ulcer in a month of a harvesting season, so as to emphasize on the need of public awareness on corneal injuries and methods to prevent them in the local districts.

### Methods

Corneal ulceration is defined as a loss of corneal epithelium with underlying stromal infiltration and suppuration associated with signs of inflammation with or without hypopyon (Srinivasan M et al, 1997). Every consecutive case of corneal injury and corneal ulcer presenting for the first time at cornea department of Sagarmatha Choudhary Eye Hospital, Lahan, Nepal from November 1, 2016 to November 30, 2016 was included in the study. Typical or suspected viral ulcer, interstitial keratitis, neurotrophic ulcer, mooren's ulcer and any ulcer associated with systemic or metabolic disease were excluded from the study.

History was taken in detail from the patient about the cause (any inciting agent with its type), duration and medicines used. Clinical examination was done thereafter to record the size of the lesion and stage of the disease. Direct smear examination of corneal scraping was done in cases with corneal ulceration with patients' consent. Detail findings of every case were recorded in the proforma designed for the study.

Informed consent was taken from the patient or guardian. Study was approved by the hospital.

### Clinical examination

The size of the epithelial defect after staining with 2% fluorescein was measured with variable slit on the slit-lamp bio-microscope and recorded in millimetres. The longest dimension of the ulcer was recorded as the size of the ulcer. The stage of the disease was noted as progressive or healing, depending on the infiltrations, margins and edges, surface, depth and vascularisation of the ulcer. Ultrasound A and B scan were done in cases where the posterior segment could not be viewed to rule out the presence of vitritis or endophthalmitis with Quantel medical B-scan echograph class I type B.

### Laboratory procedure

Corneal scraping was performed with a number 15 Bard Parker blade after the affected eye was anesthetized with a topical 0.5% proparacaine hydrochloride. Firstly the necrotic material over the surface of the ulcer was removed and then in a series of short, moderately firm strokes the leading edges and the base of each infiltrated area was scraped in one direction from the peripheral margins towards the centre of the suppurative area. The material obtained was transferred on the blade and smeared on to the sterile glass slide over an area of approximately 1 cm in diameter. The glass slide was marked with a permanent marker on the opposite surface to obviate the need to search for area smeared under the microscope. Two slides were prepared, one for Gram staining and the second for 10% KOH wet mount. The specimen was then viewed with 10x objective and 100x oil-immersion objective of a microscope (Olympus CX22LED).

### Treatment

Therapy was decided on the basis of history and smear report. However, if direct smear

examination was negative or yielded no result, then therapy was initiated on the basis of history and clinical examination. Treatment in the form of antibacterial or antifungal was started along with other adjuvant therapies.

### Data Processing and Analysis

Detail findings were recorded in the Proforma developed for this study. SPSS software version 18 for Windows was used for statistical analysis.

### Results

A total of 259 cases of agriculture related corneal injuries were noted in the month of November. Percentage of cases between 40 to 60 years of age was 39.4%.

Number of females (n=141) was higher than that of males (n=118).

One hundred thirty-three cases were from Nepal, while 126 cases were from India. Among 133 cases from Nepal, 90 cases were from two Terai districts of Sagarmatha zone.

One hundred twenty-five cases (48.3%) gave history of trauma to the eye with vegetative

material. Thirty-seven cases (14.3%) gave history of trauma to the eye with other (non-vegetative) objects.

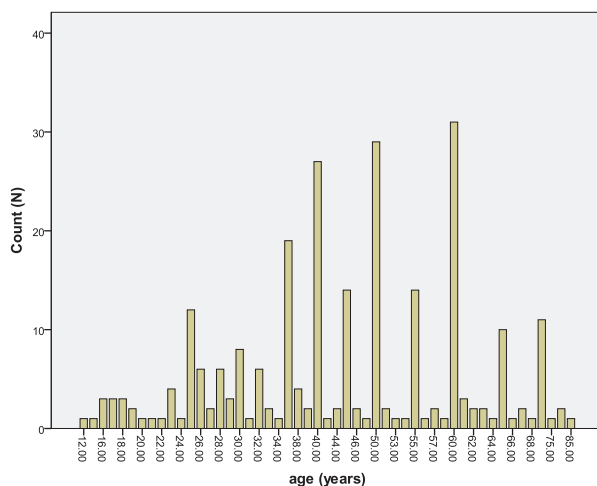
Only 4.2% of the cases presented within the first 2 days of the development of symptoms while 39.4% of the cases presented within the first week, and 37.5% after 2 weeks.

Forty-nine percent of the cases fell in a group that was either not using medicine or using undocumented medicine or self medication. It was highly unlikely that this group sought any form of established medical opinion. Topical steroids were used by 8.9% of the cases.

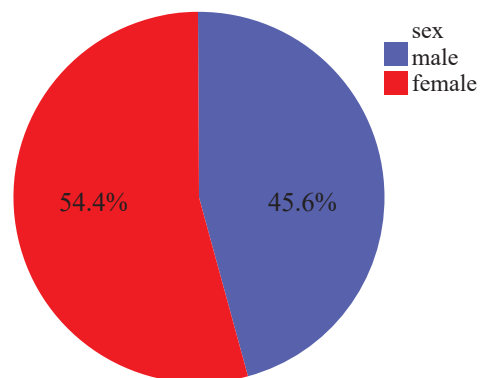
Nine cases presented with perforated cornea due to corneal ulcer and 78.8% of the cases showed signs of progression of the disease.

Less than 2 mm size of the lesion was noted in 64.9% of the cases.

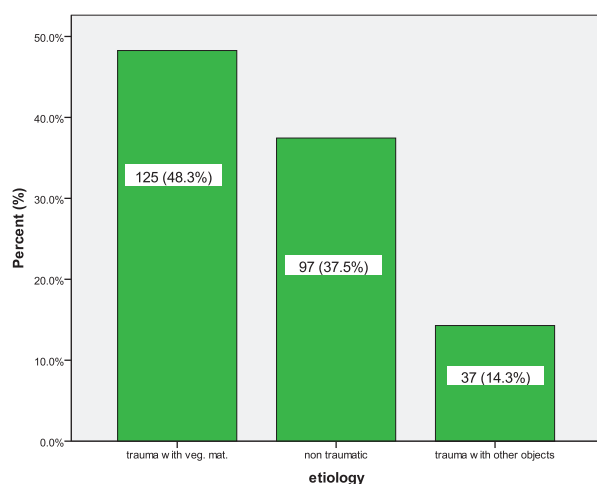
Direct smear examination of the corneal scrapes was positive in 82 out of 105 cases in which corneal scraping was done. Seventy-seven of them showed fungal elements. Bacteria was seen in 4 cases.



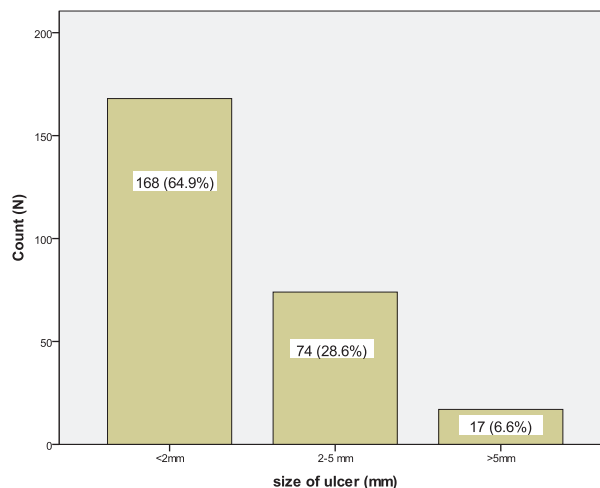
**Figure 1:** Age distribution of the cases.



**Figure 2:** Gender distribution of the cases.



**Figure 3:** Distribution based on etiology



**Figure 4:** Size of corneal lesion at the time of presentation

**Table 1: Regional distribution of the cases**

Country	Number	Percent
Nepal	133	51.35
India	126	48.65

**Table 2: Duration of presentation after developing of symptoms**

Duration	Number (N)	Percentage (%)
Within first week	102	39.4
In second week	60	23.2
After 2 weeks	97	37.5

**Table 3: Drugs used at the time of presentation**

Drugs used	Number	Percentage
Steroids	23	8.9
Antibacterials	30	11.6
Antifungals	7	2.7
Antivirals	1	0.4
Antibacterial+antifungal	71	27.4
Others	127	49

**Table 4: Stage of the disease at the time of presentation.**

Stage	Number(N)	Percentage(%)
Regressive	42	16.2
Progressive	204	83.8
	4	
	9	

**Table 5: Direct smear examination of the corneal scrapes.**

Direct smear	Number (N)	Percentage(%)
Fungus elements	77	29.7
Bacteria	4	1.5
Mixed (fungus + bacteria)	1	0.4
No result	23	8.9
Not done	154	59.5

**Table 6: Details of the cases from Nepal**

Details		Siraha (n=53)	Saptari (n=37)	Other Nepal districts (n=43)
Sex	Male	20	10	24
	Female	33	27	19
Trauma with vegetative material		21 (39.6%)	24 (64.8%)	23 (53.4%)
Duration of presentation after development of symptoms	Within first week	37	20	12
	In second week	9	8	10
	After 2 weeks	7	9	21
Drugs used at the time of presentation	Steroids	3	1	1
	Antimicrobials	16	14	30
	No or self medication or no details	34	22	12
Stage of the disease at the time of presentation	Regressive	6	5	13
	Progressive	47	32	30
Size of corneal lesion at the time of presentation	Less than 2 mm	42	32	30
	2-5 mm	10	5	9
	More than 5 mm	1	0	4
Direct smear examination	10% KOH	13	8	15
	Grams stain	1	1	0
	No result	2	1	5
	Not done	37	27	23

## Discussion

In this study of 259 patients, the mean age was 44.87 years (standard deviation-15.37 years) ranging from 12 to 85 years. Our findings agree with the findings of different studies (Sitoula RP et al, 2015; Bajracharya L et al, 2013; Feilmeier MR et al, 2010; Thapa M et al, 2012). Similarly, several studies from India and Nepal have also observed that age group of 20-50 years present more with this disease (Goel R et al, 2013; Bandyopadhyay S et al, 2012; Dhakhwa K et al, 2012; Upadhyay MP et al, 2001).

It was observed that number of female (n=141, 54%) cases was higher than the male (n=118, 46%) cases. Different studies on corneal ulcer from Nepal and India have observed more males (around 60%) affected than females (Upadhyay MP et al, 2001; Goel R et al, 2013; Bajracharya L et al, 2013; Ganguly S et al, 2011; Bandyopadhyay S et al, 2012; Dhakhwa K et al, 2012; Feilmeier MR et al, 2010; Thapa M et al, 2012). Our finding is slightly different than the findings of these studies. The difference may be due to more exposure of

females in agricultural and household activities in this part of the country.

More than 51% of the cases in our study were from Nepal. Sixty-seven percent of which were from Siraha and Saptari districts. Rest of the Nepalese patients were from the adjoining districts, mainly Dhanusha, Sunsari and Udayapur. Similarly, Indian patients were mostly from the near-by districts of Madhubani, Saharsa and Darbhanga. Our study observed higher percentage of Nepali population than the study conducted at western Nepal (25.1%) (Dhakhwa K et al, 2012).

About 49% of the cases in our study presented with a history of trauma to the eye with vegetative material. In studies from eastern and western Nepal, ocular trauma with vegetative material accounted for 38% and 33.3% respectively (Sitoula RP et al, 2015; Dhakhwa K et al, 2012). Reports from India show corneal trauma as a predisposing factor for corneal ulcer in around 65% of cases (Srinivasan M et al, 1997; Bandyopadhyay S et al, 2012).

We observed that almost 40% of the included cases presented to us within first week of development of symptoms, 23% in the second week and nearly 40% after 2 weeks. Studies from Nepal have observed in their cases 16% to almost 65% presentation in the first week, 17% to 28% presentation in the second week and 20% to 56% presentations after 2 weeks of development of symptoms (Sitoula RP et al, 2015; Dhakhwa K et al, 2012; Adhikari RK, 2006). Our study has higher percentage of presentation in the first week which may be because many of our cases were from near-by areas.

We found that almost 50% of the cases were either not using any medicine or using herbal medicine or using 'some' medicine whose documentation could not be done. Almost 9% of these patients were using steroid eye

drops before presentation. Our observation on percentage use of steroid is higher than findings reported by Sitoula RP et al (2%) and Dhakhwa K et al (4%) but lesser than that observed by Thapa M et al (17%) and Bandyopadhyay S et al (16%) (Sitoula RP et al, 2015; Dhakhwa K et al, 2012; Thapa M et al, 2012; Bandyopadhyay S et al, 2012).

Almost 80% of the cases showed signs of progression of the disease. Five percent of the cases presented with impending perforation and perforation. Progression of the ulcer was significantly associated with the duration of the disease ( $p=0.005$ ).

We observed that about 65% of the cases presented to us with ulcer size of less than 2 mm. Similarly, about 7% presented with ulcer size of more than 5 mm. Size of the ulcer was significantly associated with the duration of the disease ( $p=0.02$ ).

Direct smear examination was done in 40.5% of the cases. Positive result was seen in 78% and fungal elements were seen in 74% of them. Similar result was seen in the study done by Sitoula RP et al (Sitoula RP et al, 2015). Association between positive smear examination and size of the ulcer was not observed in our study ( $p=0.66$ ).

### Limitations

Many patients in our study had agricultural background but we do not have the documentation regarding their occupation.

History regarding the details of medicine used by the patients before presentation could not be taken from many patients either because they could not remember the name or they did not bring the medicine or prescription along with them.

Corneal scraping was done in 40.5% cases only. This study lacks culture tests of the corneal scrape sample.



## Conclusion

Agriculture related corneal injuries are common during the harvesting season. Delayed presentation and use of improper medicines decrease the visual outcome of corneal ulcer treatment. Early intervention with proper drugs is very important to halt the progression of the disease.

Many corneal ulcer patients from Nepal and India presented with trauma with vegetative material as a predisposing factor. Awareness on precaution from such trauma on eye especially during the harvesting season is very important. Programs directed to increase awareness in the agricultural community should be carried out regularly.

## References

Adhikari RK (2006). Analysis of corneal injuries in King Mahendra Memorial Eye Hospital Bharatpur, Chitwan. Kathmandu University Medical Journal; 4(1)13, 34-39.

Bajracharya L, Gurung R, DeMarchis EH, Oliva M, Ruit S, Tabin G (2013). Indications for keratoplasty in Nepal: 2005-2010. Nepal J Ophthalmol; 5(10):207-214.

Bandyopadhyay S, Das D, Mondal KK, Ghanta AK, Purkait SK, Bhaskar R (2012). Epidemiology and laboratory diagnosis of fungal corneal ulcer in the Sundarban Region of West Bengal, eastern India. Nepal J Ophthalmol; 4(7):29-36.

Basak SK, Basak S, Mohanta A, Bhowmick A (2005). Epidemiological and microbiological diagnosis of suppurative keratitis in Gangetic West Bengal, eastern India. Indian J Ophthalmol; 53(1):17-22.

Dhakhwa K, Sharma MK, Bajimaya S, Dwivedi AK, Rai (KC) Salma (2012). Causative organisms in microbial keratitis, their sensitivity pattern and treatment outcome in western Nepal. Nepal J Ophthalmol; 4(7):119-127.

Feilmeier MR, Sivaraman KR, Oliva M, Tabin GC, Gurung R (2010). Etiologic

Diagnosis of Corneal Ulceration at a Tertiary Eye Center in Kathmandu, Nepal. . Cornea; 29(12):1380-1385.

Ganguly S, Salma KC, Kansakar I, Sharma M, Bastola P, Pradhan R (2011). Pattern of fungal isolates in cases of corneal ulcer in the western periphery of Nepal. Nepal J Ophthalmol; 3(6):118-122.

Goel R, Malik KPS, Goel A, Sharma N, Aggarwal A (2013). Agriculture related corneal injuries. Nepal J Ophthalmol; 5(9): 45-49.

Sitoula RP, Singh SK, Maheseth V, Sharma A, Labh RK (2015). Epidemiology and etiological diagnosis of infective keratitis in eastern region of Nepal. Nepal J Ophthalmol; 7(13):10-15.

Srinivasan M, Gonzales CA, George C, et al (1997). Epidemiology and aetiological diagnosis of corneal ulceration in Madurai, South India. Br J Ophthalmol; 81:965-971.

Thapa M, Sharma AK, Shah DN, KC S, Shrestha S (2012). Organism Isolation in Corneal Ulcer: Utility of Different Techniques. JNMA; 52(1) 185: 14-19.

Upadhyay MP, Srinivasan M, Whitcher JP (2007). Microbial Keratitis in the Developing World: Does Prevention Work? Int Ophthalmol Clin Summer; 47(3):17-25.

Upadhyay MP, Karmacharya PC, Koirala S, et al (2001). The Bhaktapur eye study: ocular trauma and antibiotic prophylaxis for the prevention of corneal ulceration in Nepal. Br J Ophthalmol. 85:388-392.

Upadhyay MP, Karmacharya PC, Koirala S, Tuladhar NR, Bryan LE, Smolin G et al (1991). Epidemiologic characteristics, predisposing factors, and aetiologic diagnosis of corneal ulceration in Nepal. Am J Ophthalmol; 111:92-99.

Whitcher JP, Srinivasan M, Upadhyay MP (2001). Corneal blindness: a global perspective. Bull World Health Organ; 79:214-21.