

Original Article

New Clinical and Laboratory Findings of SHAPU

Anu Manandhar A¹, Todd P Margolis², Bhaiya Khanal³

¹Tilganga institute of Ophthalmology, Bagmati Bridge, Kathmandu, Nepal

²Washington University School of Medicine in St Louis, Washington DC, USA

³Natural History Museum, Department of Entomology, Tribhuvan University, Kathmandu Nepal

Abstract

Introduction: The cause of Seasonal hyperacute panuveitis (SHAPU) also known as seasonal endophthalmitis is not yet confirmed. So far, bacteria have been isolated from the vitreous of three cases, VZV from the aqueous of one case and anellovirus from the vitreous of 30 cases of SHAPU. Its connection with moth is still assumed but not proven yet. **Objective:** To study the clinical and microbiological features of SHAPU. To find out indirect evidence of its connection with moths. **Method:** Prospective longitudinal study of all the cases of SHAPU observed at Tilganga Institute of Ophthalmology in 2009 and 2010. A detailed ocular examination was performed on each case and vitreous fluid was removed from almost all cases for microbiological study. **Result:** 66 cases of SHAPU were identified. Most were children. Twenty-three percent reported a recent history of white moth contact. Fine brown hairs, were present in 5 eyes. Bacteria were isolated from the vitreous of 9 eyes, PCR testing of the vitreous of all 48 cases showed no evidence of HSV, VZV or CMV DNA. Twenty of 34 cases (58.8%) who presented within 7 days of onset of symptoms had a final visual acuity \geq 6/60 whereas 4/25 cases (16.0%) who presented after 7 days had final visual acuity \geq 6/60 ($p=0.001$). **Conclusion:** Herpes group of virus is the less likely cause of SHAPU. Bacteria are found in more cases. Early presentation is associated with a better visual outcome. Role of moth in its pathogenesis is still suspected.

Key words: Seasonal hyperacute panuveitis (SHAPU), seasonal endophthalmitis, Nepal, moth, ophthalmia nodosa

Introduction

Seasonal hyperacute panuveitis (SHAPU), also called seasonal endophthalmitis, is a disease only reported from Nepal. SHAPU has caused unilateral blindness and phthisis bulbi in hundreds of children since 1975.

This is a gross calculation based upon the records of SHAPU outbreaks in Tilganga Institute of Ophthalmology (TIO) and other eye hospitals/institutes of Nepal. Occurring seasonally as unilateral hyperacute panuveitis in children with no gender predilection, presenting with features like sudden onset of redness, leukocoria, profound vision loss and minimal pain has been observed by Malla (1978) and Upadhyay et al (1984). Upadhyay (1984) described fibrinoid reaction in the anterior chamber (AC), hypopyon, shallow

Financial interest: Nil

Conflict of interest: Nil

Received: 20.12.2017

Accepted: 31.12.2017

Corresponding author

Anu Manandhar,

Tilganga Institute of Ophthalmology

Gaushala, Bagmati Bridge,

Fax: 977-1-4474937

E-mail: anu.manandhar@tilganga.org



AC, low intraocular pressure (IOP), and white retrolental deposits. Other features described in SHAPU are - hyperemic optic discs, dilated tortuous segmented sheathed vessels and pale retinae with overlying fluffy white exudates (Manandhar et al, 2008). Intrastromal follicles in the corneal stroma have also been reported (Manandhar 2011).

The association of SHAPU with the white moth, Tussock, raises questions on the role this moth plays in the pathogenesis of SHAPU (Upadhyay et al, 1984). However, during the previous outbreaks, we heard more from the patients/parents about white moths with/without black striations identified as *Gazalina* species. Therefore, we consider moths of the *Gazalina* species a more likely candidate. *Gazalina*, is a member of the Processionary family of Notodontidae. Three species of *Gazalina* are found in Nepal, *Gazalina apsara*, *G. transversa* and *G. chrysolopha* (Figure 1). *Gazalina chrysolopha* has wide geographic distribution here and is also found in the neighboring countries like India and Bhutan (Raman, 1998). They hibernate in winter, usually emerging from April until November. The females have a golden brown tuft of 'toxic' barbed spines on their abdomen, which are constantly shed and can cause ocular irritation lasting 6-8 days. Oak and pine Processionary caterpillars are reported to cause various allergic conditions including conjunctivitis (Vega et al, 1999, Maier et al, 2004 & Gottshling et al, 2007).

In our experience, the clinical features of SHAPU are similar to those of endophthalmitis. Malla (2005) had described it as 'seasonal endophthalmitis'-a sterile suppurative condition. But we found bacteria in the vitreous of three cases (Manandhar et al, 2008). In the past outbreaks we have observed that the SHAPU cases get worse when treated with topical and oral steroid alone, which is unlikely to happen if it had just been inflammatory

reaction induced by moth hair follicle. Intravitreal antibiotics seem to show effective treatment outcome so far in our observation, again indicating possibility of bacterial invasion into the eyes. However, *Varicella Zoster virus* (VZV) was found in the aqueous of one case (Kathil et al, 2005) and anellovirus has been isolated from 30 out of 32 vitreous samples of SHAPU cases (Smits et al, 2012). Similar observation has been made by Lee et al (2015) in culture negative cases presumed to be infective endophthalmitis. However, it is not yet understood whether this virus is pathogenic or just an inflammatory marker. So it was important to find out if herpes group of virus could be the cause, as handful of cases did present with keratitis and granulomatous keratic precipitates.

In this study, vitreous samples of SHAPU affected eyes were analyzed to isolate potential pathogen. We performed bacterial culture and PCR for *Herpes Simplex virus* (HSV), VZV & *Cytomegalovirus* (CMV) attempted to more completely characterize the clinical features of SHAPU.

Methods

This was a prospective longitudinal hospital-based study of all patients attending TIO from 2009 and 2010 who met the following criteria: 1) Unilateral redness and visual loss of sudden onset and rapid progression; 2) Hypopyon or extensive posterior synechiae or fibrinous exudate in the AC; 3) Grade 4 cells in the AC, 4) Poor fundus view or leukocoria, in the absence of cataract; 5) Clinically visible moderate to severe vitreous inflammation or trace to significant echo dense shadows in the vitreous cavity in B-scan whenever posterior segment was not visible 6) Absence of systemic infection; 7) No history of penetrating ocular trauma or intraocular surgery.

At the initial visit, all patients (guardians in cases of children) were subjected to a

complete ocular history, detailed history of moth exposure, review of systems followed by physical examination to rule out non-ocular septic foci, a detailed ophthalmic examination, and B-scan ultrasonography for eyes with a poor view of the posterior segment and were shown a picture of *G. chrysolopha* to determine possible exposure (Figure 1). Corneal sensation was checked in patients old enough to respond verbally. Vitreous fluid samples were obtained from all patients (with the exception of few who refused treatment) for microbiological study and from some aqueous samples were also obtained.

Ocular fluids were assayed by Gram and giemsa stains and KOH preparation, cultured on blood, chocolate, Sabouraud's agar and in brain heart infusion broth. Aliquots of vitreous were frozen at -80°C and assayed at a later time for viral DNA [*Herpes simplex types 1 & 2 (HSV 1 & 2)*, *VZV* and *Cytomegalovirus (CMV)*] by polymerase chain reaction based assays.

For statistical analysis, all data was entered into Excel and analyzed with SPSS version 11.5.

Results

During the two-year study period we diagnosed 66 patients with SHAPU. All cases were unilateral. Patients were from 25 different districts of Nepal. The greatest number of cases (15) was from within the Kathmandu valley, followed by 8, 7 and 6 cases each from Dolokha Kavrepalanchoke and Sindhupalchoke districts, respectively. Sixty-seven percent of the cases came from hilly districts, 18% from Terai (the plains) and 15% from the mountainous region (Figure 2).

Thirty-six of the patients (54.5%) were female and 30 (45.4%) were male. Ages ranged from 9 months to 49 years. The mean age was a 10.96 ± 12.31 year, with 75.6% (50/66) being ≤ 14 years.

Out of the 66 cases, 55 (83.3%) presented in 2009, the first case in July 3, and the last in

December 14. In 2009 the greatest number of cases presented in the month of September (Figure 3). In 2010, the first case presented in January 7 and the last in August 1 with the majority presenting in July (Figure 4). Out of the 66 cases, 37 (56%) presented within a week, 18/66 cases (27.2%) after 8-15 days and 16.6% after ≥ 16 days of onset of symptoms.

Out of the 66 cases, 36 (55%) reported the presence of white moths in their living environment at the time of onset of symptoms, with 9 reporting the specific presence of *Gazalina*. However, only 15 cases (22.7%) reported a clear history of moth contact (8 with *Gazalina*), and 4 (6%) reported possible moth contact. Two cases reported possible contact with an insect other than a moth, and 5 reported onset of symptoms after mild blunt ocular trauma.

All 66 cases were apparently healthy except for one patient who had nausea and vomiting a few days prior to the onset of ocular symptoms. One patient reported a febrile illness following onset of ocular symptoms..

Forty-seven percent had involvement of the right eye and 53% the left eye. Out of 66 cases, 62 (93.9%) presented with visual acuity (V_A) less than 3/60. Corneal sensation was assessed in 28 eyes, and was absent or diminished in 15 (22.7%) eyes, and normal in 13 (19.7%) eyes. Fifteen eyes had edematous corneas. Five cases (7.6%) had multiple brown hair-like structures in the affected eye; 4 in the corneal stroma (Figure 5) and one in the anterior vitreous (Figure 6). Thirty-seven of the affected eyes (56%) had a hypopyon, 33 (50%) had an exudative membrane over the pupil, 4 (6%) had iris atrophy (Figure 7), and 10 (15.1%) had leukocoria due to vitreous opacification.

The IOP was evaluated in 60 cases, and was normal in 34 affected eyes (51.5%). Ten eyes (15.1%) had an elevated IOP (>22 mm Hg) and 16 eyes (24.7%) had IOPs of ≤ 7 mm Hg.

On the day of diagnosis B-scan ultrasound was performed in 64/66 affected eyes. In 25 eyes (39%), in 23 eyes (35.9%), and in 16 eyes (25%), there was marked, mild and inconspicuous vitreous echo-density, respectively. In all eyes the vitreous echo-densities were low to medium reflectivity.

Sixty-three of 66 patients (95.4%) received treatment. The other 3 cases either refused treatment or were lost to follow-up. Sixty-two of the 63 eyes had a vitreous biopsy and were treated with intravitreal injection of vancomycin (1mg/0.1ml) amikacin (0.4mg/0.1ml) and dexamethasone (0.4mg/0.1ml) (VAD) and systemic prednisolone (1mg/kg/day tapered over 1-2 months). In addition, 36 eyes required a core vitrectomy, and 30 eyes had a lensectomy. Thirty-five of 63 cases (55.6%) were also treated with one or more forms of antiviral therapy; 16 with oral acyclovir, 10 with oral and IV acyclovir and 9 with intravitreal gancyclovir injection.

The aspirated vitreous ranged in color from green to translucent and from thick to watery in consistency. By microscopy, 20 vitreous samples had WBCs. All vitreous samples had negative KOH preparation. In 9 cases (14.5%) gram positive bacteria grew from the vitreous (Figure 8). Six were identified as *Streptococcus pneumoniae*, 1 as *Streptococcus pyogenicus*, and 2 as *Staphylococcus aureus*. None of the vitreous samples grew fungus. Out of the 9 culture positive cases, 7 showed gram positive diplococci, on gram stain of vitreous fluid and 1 showed gram positive cocci. The gram stain of one culture negative vitreous biopsy also contained gram positive cocci. The vitreous from 48 of 66 cases was assayed by PCR for

viral DNA. All 48 samples were negative for *HSV 1*, *HSV 2*, *CMV* and *VZV* DNA.

Of the 46 aqueous samples that were obtained, WBCs were present in 23 samples and gram positive diplococci were noted in 3 eyes (with culture positive vitreous). All aqueous samples were culture-negative.

Of the 63 treated cases, the final V_A was $\geq 6/18$ in 14 eyes (22.2%), 6/18-6/60 in 6 eyes (9.5%), 6/60 – 3/60 in 2 eyes (3.1%) and 3/60 – NLP in 33 eyes (52.3%). For the sake of analysis, preverbal children who had complete clinical recovery and followed light and objects after treatment (4/63 eyes (6.3%)), were assumed to have final V_A of 6/6-6/18. Four of 63 patients (6.3%) were lost to follow up 1-3 days after intravitreal injection or vitrectomy. These cases were excluded from V_A analysis. In the remaining 59 cases the mean follow-up time was 19.2 weeks with a range of 1-96.5 weeks.

Of the 34 cases who presented within 7 days of onset of symptoms, 20 (58.8%) had a final $V_A \geq 6/60$ and 14 (41.2%) had a final $V_A < 6/60$. Of the 25 cases who presented after 7 days, only 4 (16.0%) had final $V_A \geq 6/60$ whereas 21 (84.0%) had a final $V_A < 6/60$. Thus, early clinical presentation was associated with a better visual outcome, $p=0.001$ (Fisher exact test) [Table 1].

Of the 26 cases treated with intravitreal VAD alone, 12 (46.2%) had final $V_A \leq 6/60$ and 14 (53.8%) had final $V_A > 6/60$. Of 32 cases treated with intravitreal VAD + antivirals, 11 (34.4%) had $V_A > 6/60$ and 21 (65.6%) had final $V_A < 6/60$. This difference was not statistically significant, $p= 0.362$ (Chi-square test), indicating that adding antiviral agents to the treatment had no apparent effect on final V_A (Table 2).



Figure 1: *Gazalina chrysolopha*

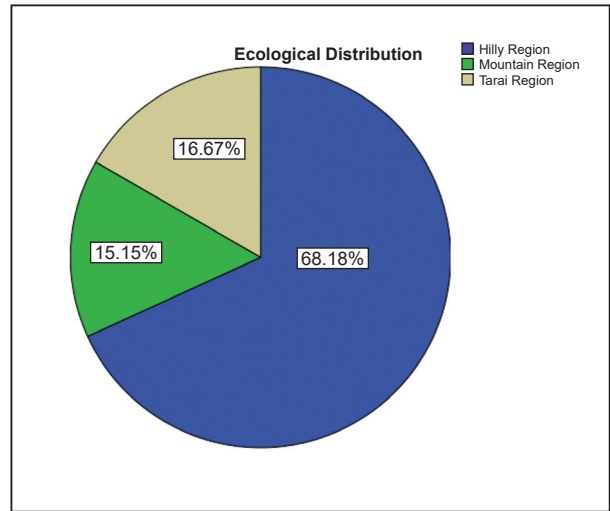


Figure 2:

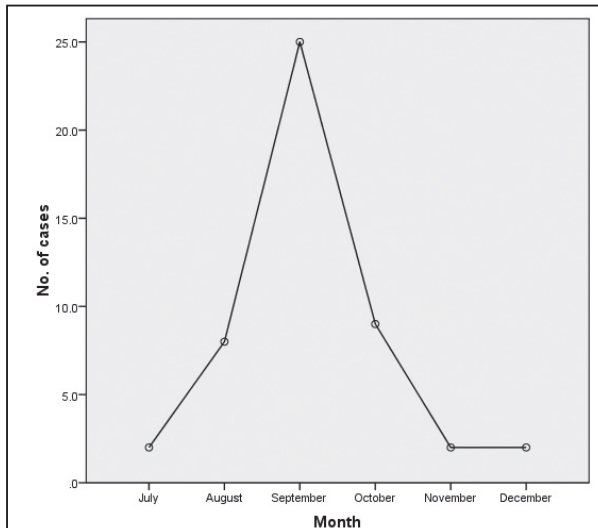


Figure 3: Autumn outbreak

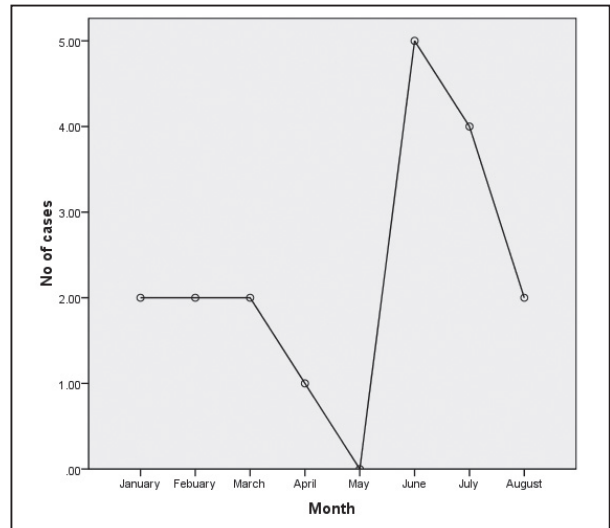


Figure 4: Summer outbreak 2010

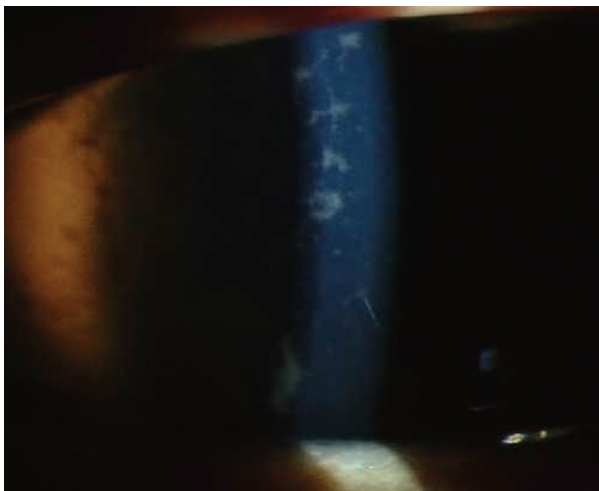


Figure 5: Hair follicle in corneal mid stroma in an eye with SHAPU




Figure 6: Hair follicle in anterior vitreous face

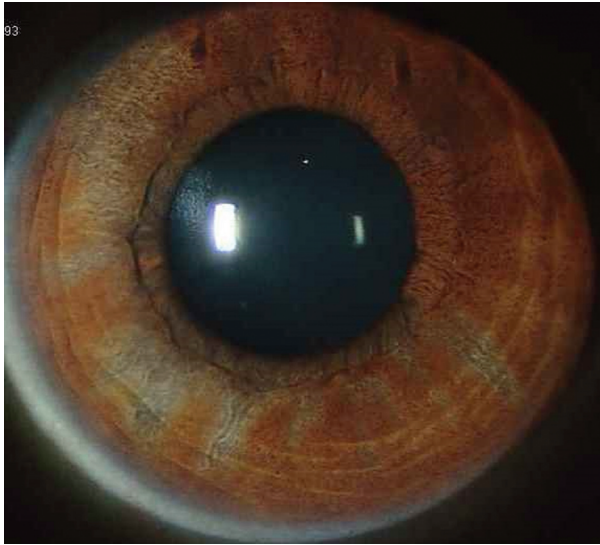


Figure 7: Patchy iris atrophy seen in the healing stage of SHAPU

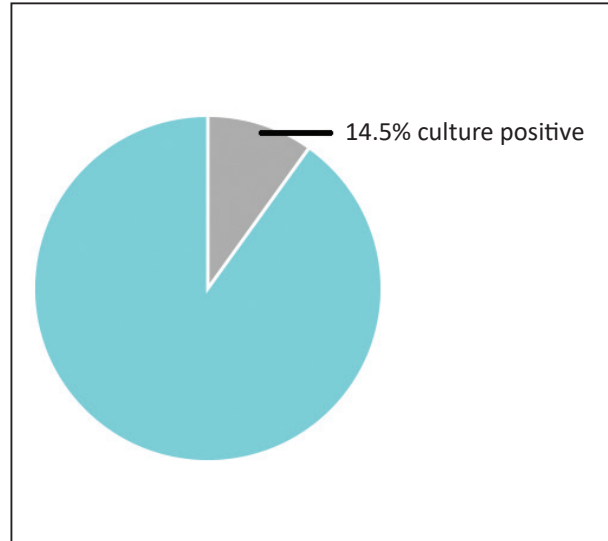


Figure 8: Vitreous culture result

Table 1: Time of Presentation and final visual acuity

Final visual acuity	Time of presentation from the onset of symptoms		Total	p= 0.001 (Fisher's exact test)
	≤7 days	>7 days		
<6/60	14 (41.2%)	21 (84.0%)	35 (59.3%)	
≥6/60	20 (58.3%)	4 (16.0%)	24 (40.7%)	
Total	34 (100%)	25 (100%)	59 (100%)	

Table 2: Treatment and final visual acuity

Final visual acuity	Treatment with		Total	p= 0.362 (Chi-square test)
	VAD+ antivirals	VAD only		
<6/60	21 (65.6%)	14 (53.8%)	35 (60.3%)	
≥6/60	11 (34.4%)	12 (46.2%)	23 (39.7%)	
Total	32 (100%)	26 (100%)	58 (100%)	

Discussion

Literature revealed five reports, each retrospectively describing between 12 and 32 cases of SHAPU (Malla, 1978, Upadhyay et al, 1984, Byanju et al, 2003, Manandhar et al, 2008, Shrestha, 2010). To our knowledge our study is the largest collection of SHAPU patients, and is the only series studied prospectively. We believe that this approach has allowed us to significantly broaden our understanding

of the epidemiology, clinical findings, and progression of SHAPU as well as to begin to understand its possible causes.

In previous studies SHAPU was described as occurring in the autumn, in two-year cycles (Malla, 1978, Upadhyay 1984, Byanju et al, 2003, Manandhar et al, 2008, Shrestha, 2010). However, 15% of the cases in our study presented in the summer of 2010. We had in fact observed 6 cases of SHAPU in the summer

of 2008 as well (unpublished observations). Thus, SHAPU appears to occur on a yearly basis, but with greater numbers in the autumn of every other year.

As with previous reports we found that a relatively high percentage of our patients with SHAPU (54.5%) reported white moths in their surrounding associated with onset of symptoms, with 22.7% of patients/ guardians reporting definite moth contact (Byanju et al, 2003 & Malla, 2005). Only 8 of the 66 patients (12.1%) with SHAPU had a history of ocular contact with a moth fitting the description of *Gazalina*. However, without a matched control group it is impossible to determine whether these associations are statistically significant.

In the current series we observed following new clinical findings- not described so far; corneal edema, reduced corneal sensation, iris atrophy and hair-like structures in vitreous (as well as cornea). Corneal edema & paresthesia and iris atrophy could be the effect of anellovirus or moth toxin. Another interesting observation was that liquefied vitreous was easily obtained from our patients just with the help of 26 or 23 G needle, even in patients that presented very early in their clinical course. This suggests very early involvement of the posterior segment of the eye.

In this study we carried out extensive microbiological testing. No *HSV*, *VZV* or *CMV* DNA was detected in the 48 eyes that were tested. Thus, unlike the report by Kathil et al (2005) we found no evidence for neither *VZV* nor *HSV* or *CMV* as the cause of SHAPU. Since vitreous cultures and KOH preps were negative for fungi, it is also unlikely that fungi play a role in the pathogenesis of SHAPU. In contrast, bacterial cultures from 9/62 vitreous samples (14.5%) were positive for gram-positive bacteria. This is consistent with an earlier report in which *Streptococcus pneumoniae* was isolated from 2/6 cases in the 2005 SHAPU outbreak (Manandhar et al, 2008).

Ocular or intraocular inflammatory/toxic stimulus has been observed with caterpillar/moth settae and tarantula hair (Haluska et al, 1983, Lasudry & Brightbill, 1997, Fraser et al, 1994, Choi & Rauf, 2003, Sood et al, 2004, Sengupta et al, 2010). Given the unusual epidemiology of SHAPU, absence of penetrating ocular trauma, absence evidence of systemic infection, the fine brown hairs in 5 eyes and the bacterial isolation from 9 eyes in this series one unifying hypothesis is that SHAPU is driven by ocular microtrauma induced by moth hairs and intraocular bacterial invasion through it directly or the hairs serving as a vehicle for bacterial intraocular delivery, resulting into a combination of ophthalmia nodosa and bacterial endophthalmitis at least in some cases. In support of this notion, 1/5 cases with fine brown hairs in the eye also grew *Streptococcus pyogenes* from the vitreous.

Conclusion

Possibility of herpes group of virus to be the cause of SHAPU is unlikely. At least 14.5% cases of SHAPU are proven to be bacterial endophthalmitis. SHAPU outbreak occurs every year but in two different seasons- autumn and summer. Antiviral agents did not add benefit to the treatment of SHAPU. Role of moth, especially the *Gazalina*, in the pathogenesis of SHAPU is still suspected. But more research is warranted to confirm it.

Acknowledgement

Himalayan cataract project, USA for financial support.

Proctor foundation, UCSF, USA for financial support

Vicky Cevallos for performing the PCR tests.

Dr G. Paudel and Dr R Thapa for surgical management of complications of the cases.

Dr J. Suwal for data collection and data entry

Khadka, N. Patel, P. Makaju for microbiological study



RK Suwal, S Makaju, B. Dahal for photography
Dr MK Shrestha, N. Maharjan for statistical
analysis and P Banjara for preparing graphs.

Govind Bista for helping on reference section.

References

Byanju RN, Pradhan E, Sapkota YD (2003). Visual outcome of vitrectomy in seasonal hyperacute panuveitis. *Kathmandu Univ Med J*; 1: 121-3.

Choi JT, Rauf A (2003). Ophthalmia nodosa secondary to tarantula hairs. *Eye (Lond)*; 17(3):433-4.

Fraser SG, Dowd TC, Bosanquet RC (1994). Intraocular caterpillar hairs (setae): clinical course and management. *Eye (Lond)*; 8 (Pt 5):596-8.

Gottschling S, Meyer S, Dill-Mueller D, Wurm D, Gortner L (2007) Outbreak report of airborne caterpillar dermatitis in a kindergarten. *Dermatology*; 215(1):5-9.

Haluska FG, Puliafito CA, Henriquez A, Albert DM (1983). Experimental gypsy moth (*Lymantria dispar*) ophthalmia nodosa. *Arch Ophthalmol* ; 101(5):799-801.

Hossler EW. Caterpillars and moths (2009). *Dermatol Ther*; 22(4):353-6.

Kathil P, Biswas J, Gopal L (2005). Demonstration of varicella zoster virus in a case of presumed seasonal hyperacute panuveitis. *Indian J Ophthalmol*; 53: 270-2.

Lasudry JG, Brightbill FS (1997). Ophthalmia nodosa caused by tarantula hairs. *J Pediatr Ophthalmol Strabismus*; 34(3):197-8.

Lee AY, Akileswaran L, Tibbetts MD, Sunir J. Garg SJ, Van Gelder RN(2015). Identification of Torque Teno Virus in Culture-Negative Endophthalmitis by Representational Deep DNA Sequencing. *Ophthalmology*; 122(3): 524–530.

Maier H, Spiegel W, Kinaciyan T, Honigsmann H (2004). Caterpillar dermatitis in two siblings due to the larvae of *Thaumetopoea processionea* L, the oak processionary caterpillar. *Dermatology*; 208:70–73.

Malla OK. Endophthalmitis probably caused by Tussock moth (1978). Proceedings first National Seminar on Prevention of Blindness. 44.

Malla OK. Sudden blindness in Nepal children (Editorial) (2005). *Kathmandu Univ Med J*: 3: 1-5.

Manandhar A, Paudel G, Rai CK et al Seasonal hyperacute panuveitis-recent scenario in Nepal (2008). *Nepal Med Coll J*; 10(3): 196-198

Manandhar A (2011). Seasonal hyperacute panuveitis-an update. *Curr Opin of Ophthalmol*; 22:496-501.

Raman MK. Outbreak of *Gazalina chrysolopha* Kollar (Lepidoptera: Notodontidae) and of *Alnus nepalensis* in eastern and central Bhutan (1998). *Insect Environment* 4(3): 65

Sengupta S, Reddy PR, Jamyang Gyatsho J et al. Risk factors for intraocular penetration of caterpillar hair in Ophthalmia Nodosa (2010). A retrospective analysis. *Indian J Ophthalmol*; 58(6): 540-543.

Shrestha E (2010). A profile and treatment outcome of seasonal hyper-acute panuveitis. *Nep J Oph* ; 2(3): 35-38.

Smits SL, Manandhar A, van Loenen FB, Leeuwen MV, Baarsma S, Dorrestijn N, Osterhaus A D.M.E, Margolis TP, Vergans G M. G. M (2012). High Prevalence of Anelloviruses in Vitreous Fluid of Children With Seasonal Hyperacute Panuveitis. *J Infect Dis*; 205(12):1877-84

Sood P, Tuli R, Puri R, Sharma R (2004). Seasonal epidemic of ocular caterpillar



hairinjuries in the Kangra District of India. *Ophthalmic Epidemiology*; 11(1): 3–8.

Upadhyay MP, Rai NC, Ogg JE, Shrestha BR (1984). Seasonal hyperacute panuveitis of unknown etiology. *Ann Ophthalmol*; 16: 88-44.

Upadhyay MP, Rai NC, Ogg JE, Shrestha BR (1984). Seasonal hyperacute panuveitis.

Uveitis update. Amsterdam. *Excerpta Medica*. Saari KM (editor), Elsevier Science (publisher);:257-262

Vega JM, Moneo I, Armentia A, Fernández A, Vega J, De La Fuente R, Sánchez P, Sanchís ME (1999). Allergy to the pine processionary caterpillar (*Thaumetopoea pityocampa*). *Clin Exp Allergy*; 29(10):1418-23.