

# Case Report on Ovarian Tumour

Dr. (Lt. Col.) Lalita Joshi  
MBBS, DGO.  
Dept. Chief Gynae./Obs

## Introduction

Ovarian enlargements, cystic or solid may occur at any age. Functional and inflammatory enlargements of ovary develop almost exclusively during child bearing age. They may be asymptomatic and produce local discomfort menstrual disturbances, infertility, or rarely cause acute symptoms due to complications like haemorrhage, rupture or torsion.

Malignant tumors of ovaries is lower in incidence to that of cervix and uterine endometrium. Ovarian cancers account for 5% of all gynecological cancers. They are associated with nulliparity, infertility, abnormal breast swellings. It is well known that repeated gonadotrophic stimulation of ovaries and uninterrupted cycles of ovulation predispose to ovarian cancer. Factors suppressing ovulation such as repeated pregnancies, lactation and oral contraceptives are known to be protective.

## Case report

Name of Patient:- SMP

Age./Sex:- 48/F.

Date of Admission:- 2055.2.20

C/o Mass abdomen - 2 yrs.  
Backache + Swelling of legs - 1 yr.  
Discomfort after meals - 1 yr.  
Pain epigastric region (dullache) - 1 month.  
Frequency of micturation - 1 month.

LMP- Falgun 2054 since then she has been having bleeding P/V off and on. This could be due to congestion of uterine vessels.

O/H.- P<sub>6+0</sub> last child 9 yrs.

P/H. - Not relevant.

## H/o:- Present illness:

Patient admitted to Birendra Hospital on 20<sup>th</sup> Jestha 2055 as a case of ascitis in surgical ward. Referred for Gynae consultation. Patient on careful questioning said she noticed a lump in her (R) lower abdomen 2 yrs. back when she had an attack of abdominal pain. She applied pressure to the area for pain relief and after an hour she felt fine; after this she never cared for the lump.

Since last 1 month patient has dull epigastric pain with frequency of micturation and also the mass seemed to increase, so she came for medical help. Laparotomy decided, and on 2055.3.2 she was operated. A large ovarian cyst (L) removed with TAH & RSO. Her post-operative days were uneventful. Stitches removed on 10<sup>th</sup> day and patient discharged on 15<sup>th</sup> day.

## On examination:

- Patient emaciated.
- Oedema of legs +
- Pallor + +

- P/A = Inspection - tense distention of abdomen extending from epigastrium to hypogastric region. Lateral sides flat, engorged veins ++.
- = Percussion - dull note in middle, shifting dullness not elicited, fluid thrill +.
- = Palpation - Abdomen tense.  
- Cystic feel.  
- Upper and lower limits of mass not identified.  
- No mobility
- = Auscultation - silent.
- P/V. - Uterus size not assessed.  
- Fullness in lateral and posterior fornices.  
- Minimal cystocele.

### Investigations:

- Routine pre-op blood test normal.
- Hb - 8.2 gm% after 2 units 11.2gm%
- |     |  |      |
|-----|--|------|
| LFT |  | NAD. |
| CXR |  |      |
| IVP |  |      |
- USG - Huge ascitis
- MRI - Inconclusive, reported cystic mass.

### Findings at operation:

Uterus bulky but normal looking. (L) ovarian cyst wt. 18 kg., glistening thick surface with adhesion to the anterior abdominal wall freed digitally, posteriorly the cyst was free. Big engorged veins all over. (R) ovary double the normal size, cystic. Liver and other organs normal. No free fluid in the abdominal cavity.

### Histopathological report:

#### Macroscopic findings:

- (L) Multiloculated cyst consisting of chocolate colour fluid with smaller cysts containing mucinous material.
- (R) Ovary follicular haematomas. Endometrium unremarkable. Cervix squamous metaplasia with chronic cervicitis.

#### Microscopic findings:

Mucinous cystadenoma with atypicality of cells at some places. No multilayering or stromal invasion or solid areas.

Papillae formation seen at some places - borderline mucinous cystadenoma.

#### Differential diagnosis:

1. Pregnancy - Amenorrhoea.  
- Fetal heartsound.  
- USG confirmative.
2. Ascitis - Midline resonance with dullness in flanks on percussion.
3. Large hydronephrosis - Projects forwards into the abdomen and penetrates back into the loin. It is situated high up in the abdomen above the pelvis. IVP to establish diagnosis.

## Discussion:-

Out of all ovarian tumors epithelial tumors account for 70 - 80%. Mucinous cystadenoma is the commonest of these epithelial ones about 20% and may reach enormous proportions and still remain benign. About 6% may have malignant foci. Shaw in 1932 reported a cyst of 91 kg.

It is always good to give large incision (Xiphisternum - pubis) and deliver the cyst intact and tapping should be condemned due to possibility of cancer cells being disseminated over peritoneal cavity if tumors unlike the some may have benign, boderline and malignant elements in same tumor hence extreme sampling should be done for H/P reporting.

Origin of tumor not clear but one theory says tumor represent extension of ovarian mullerionosis with metaplesia of ovarian surface epithelium into cervical epithelium, Tumors has demonstrated this transition from Walthard's epithelium into high columnar epithelium of a mucinous cyst. Histologically cell of tumor paralleled in body by those of cervix and large intestine.

Mucinous cystadenomas usually consist of jelly like material but sometimes contain green or chocolate coloured material depending on presence of blood pigments derived from previous intracystic haemorrhage.

Histological cell hallmark of mucinous tumor of low malignant potential (borderline) is stratification of epithelial lining, the formation of tufts arising from papillary projections and absence of destructive stromal invasion.

With large mucinous tumors patient may have what is referred as OVARIAN CACHEXIA where patient emaciated. Such cachexia has no relation to development of malignant change in the tumors.

## Conclusion

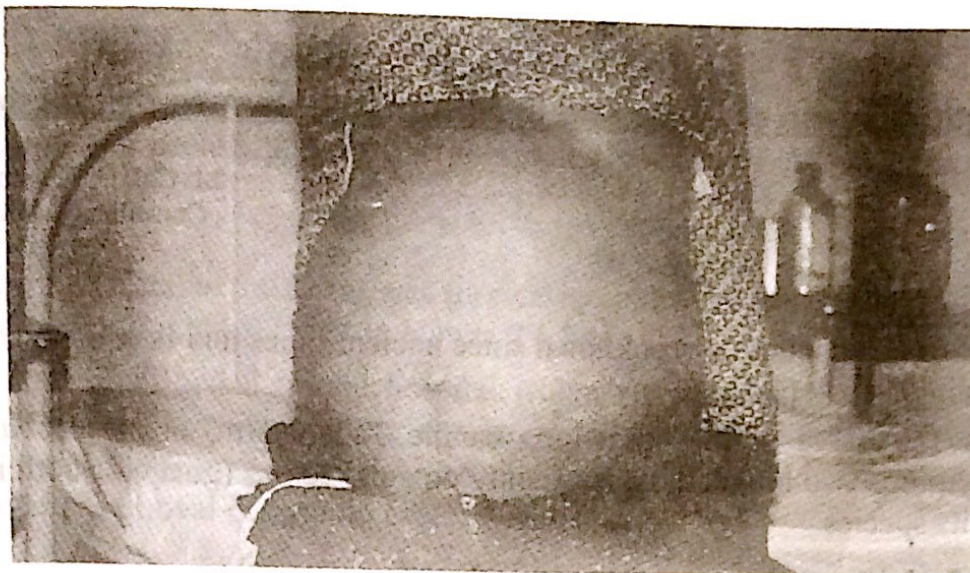
In our patient there was confusion in distinguishing between a large ovarian cyst and ascitis. The only clinical finding supportive to diagnosis was the dullness in the midline on percussion. In ascitis the note is dull over the flanks and abdomen is tympanitic in midline, also shifting dullness may be obtained. Hence in my opinion besides other investigations clinical examination should not be overlooked.

Our patient was histologically catagorised as boderline mucinous cystadenoma, but there is no clear evidence that chemotherapy is of value after surgery. Hence for such cases in my opinion a careful follow-up is mandatory after initial surgery.

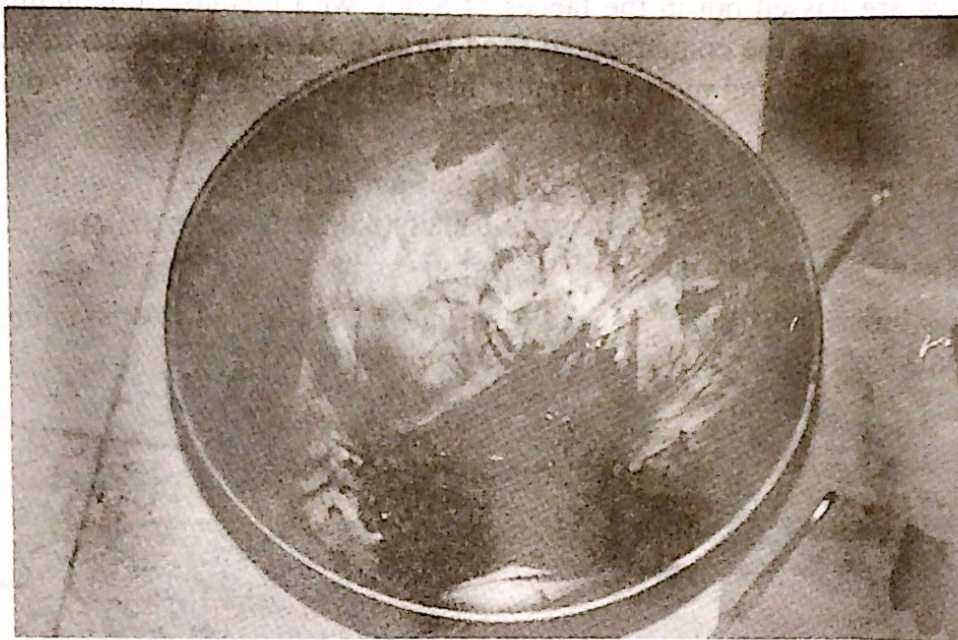## References:

1. Howkins & Bourne, shaws textbook of Gynae, Disorders of ovary 1997, 445 - 465, 473 -474.
2. Charles (R) whitfield, Dewhurst text of Obst & Gynae for postgraduates. Benign & Malignant tumors of ovary 1996, 764.
3. V.R. Tindall, Jeffcoates Principles of Gynae, Primary ovarian tumors 1987, 465.
4. Michale Peckham, Herbert. Pineds and umberto veronesi, Oxford textbook of Oncology vol - 1, Histopathological classification & typing of solid tumors 1995, 311.
5. Journal of Royal College assessment test review No 97/10

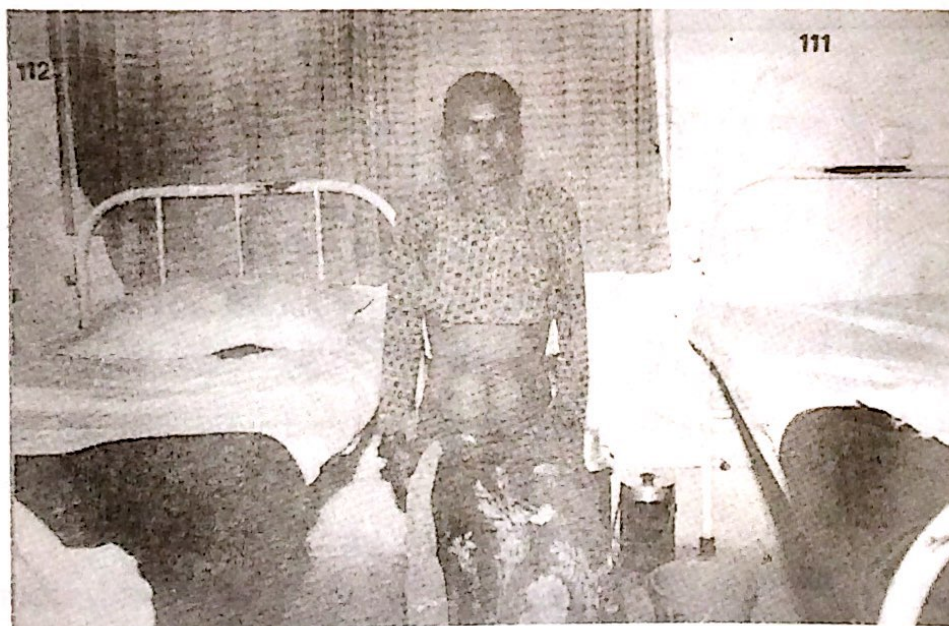



Picture of patients before surgery



Picture of Ovarian Tumour



Picture of patient after Surgery