

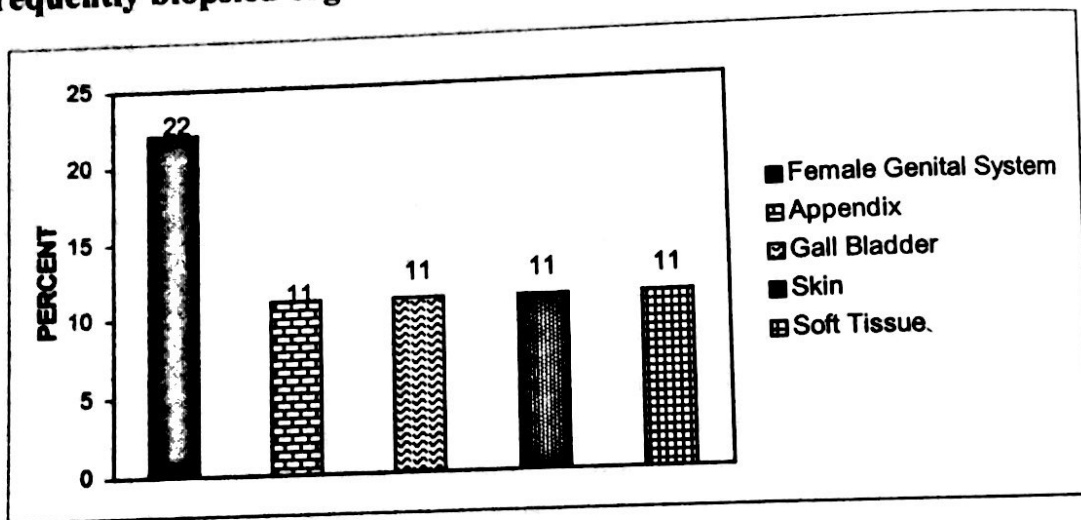
HISTOPATHOLOGICAL ANALYSIS OF BIOPSY SPECIMENS OF ONE YEAR AT SHREE BIRENDRA HOSPITAL



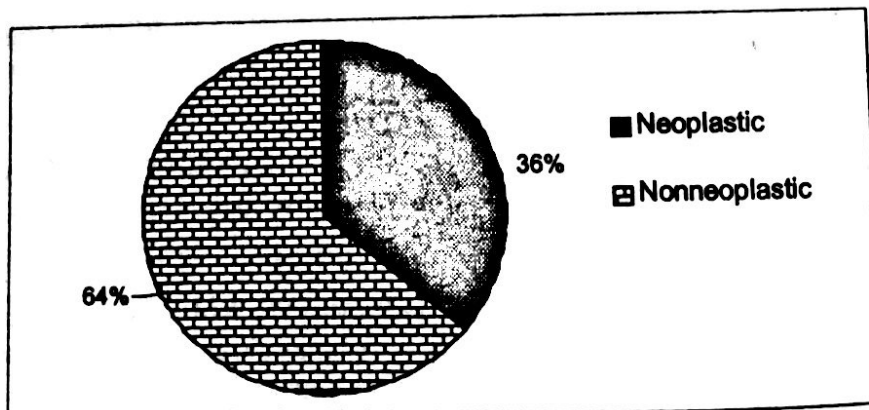
Lt. Col. Dr. Rajesh Panth, MD
Head of Department of Pathology

Diagrammatic and tabular presentation of diagnoses of biopsy specimens received in one year helps us to refine our knowledge about the incidence and prevalence of various lesions for which histopathological examination is requested. The following is a humble attempt to analyze a total of 1296 lesions diagnosed at the Army Hospital in the year 2060 B.S.

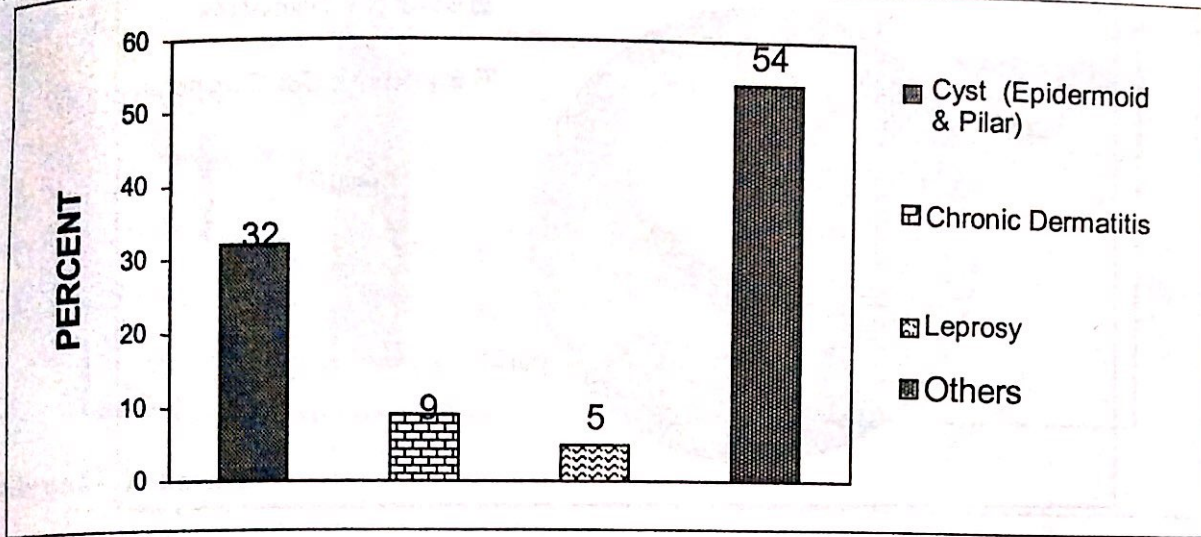
Most frequently biopsied organs:



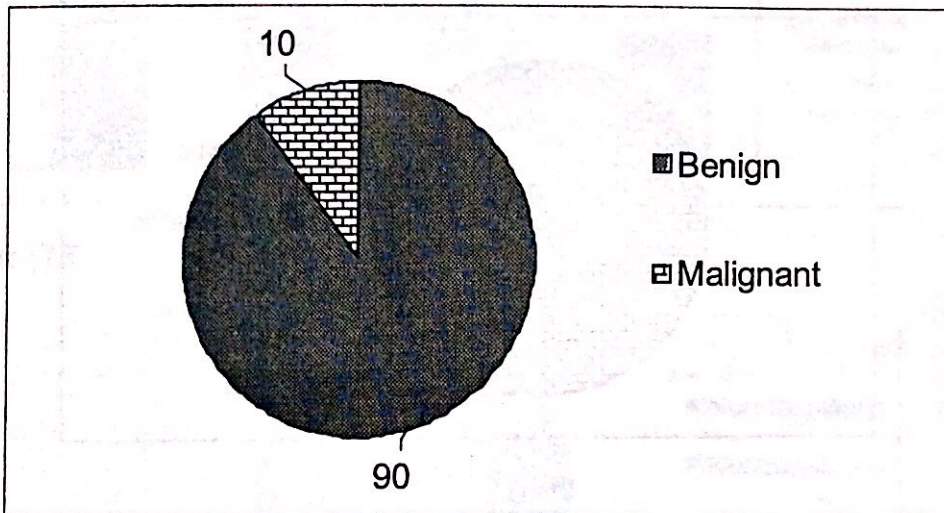
Skin (145): Lesions



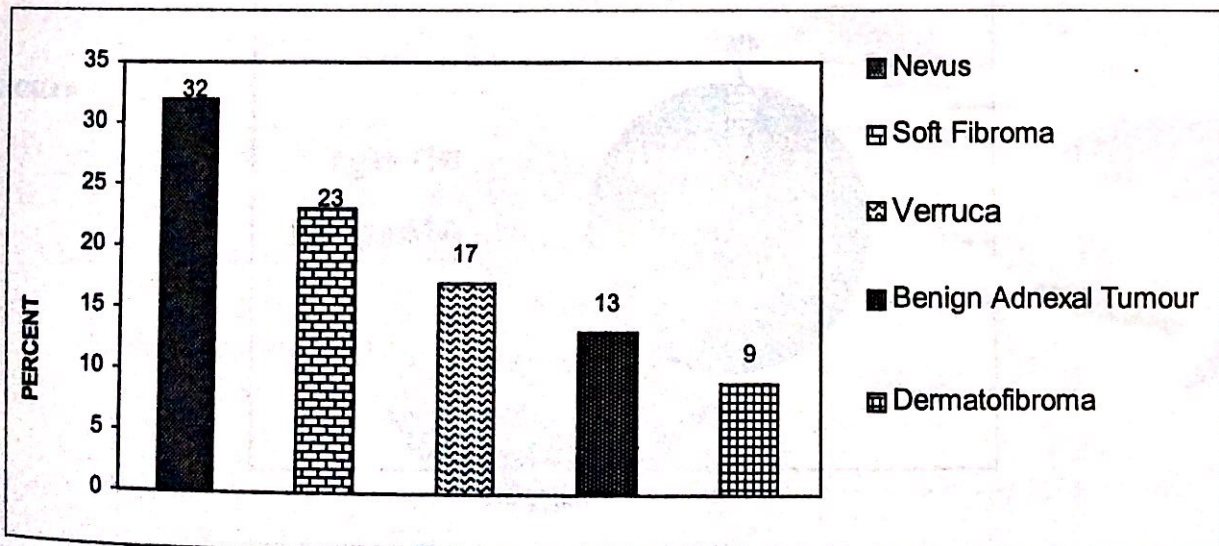
Noneoplastic Lesions



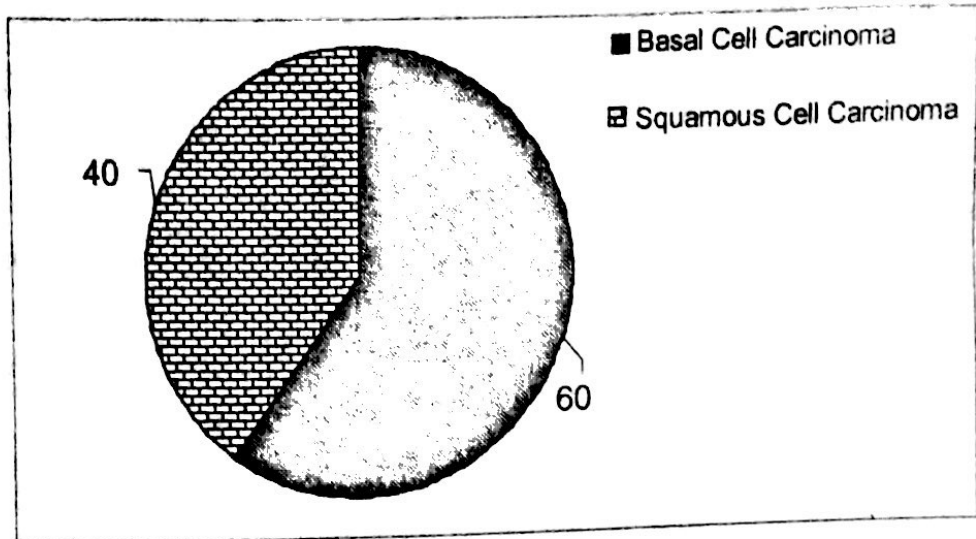
Tumours



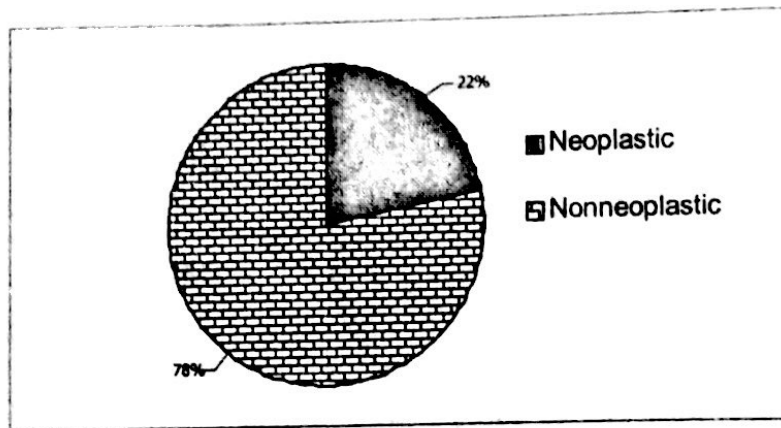
Benign Tumours



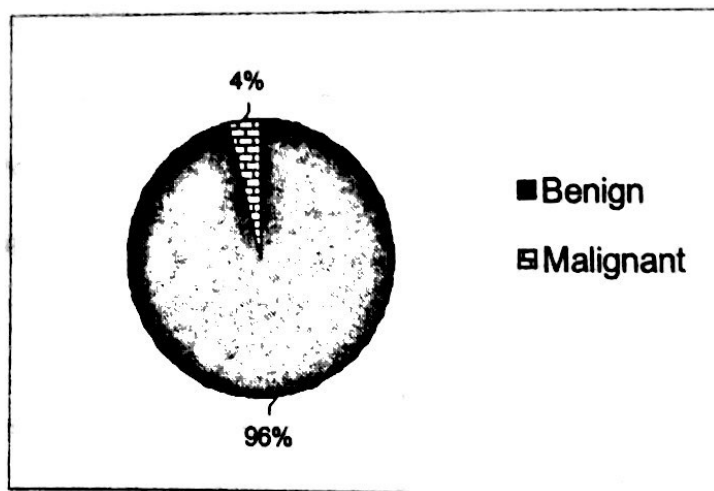
Malignant Tumours




Soft Tissue (108) Lesions



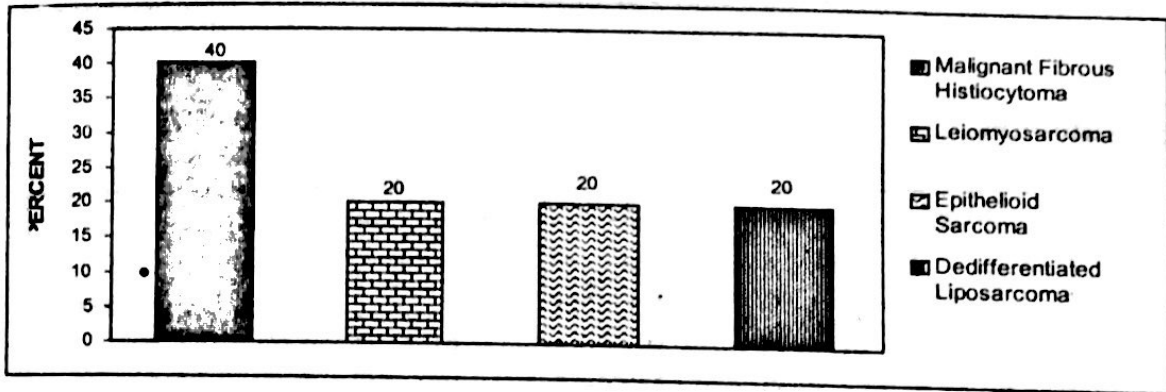
Tumours



Benign Tumours




Malignant Tumours

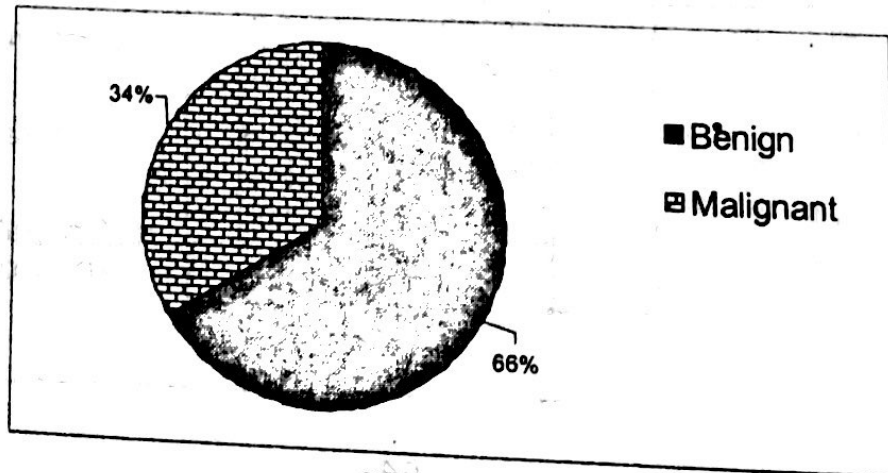


Bone and Joint (25)

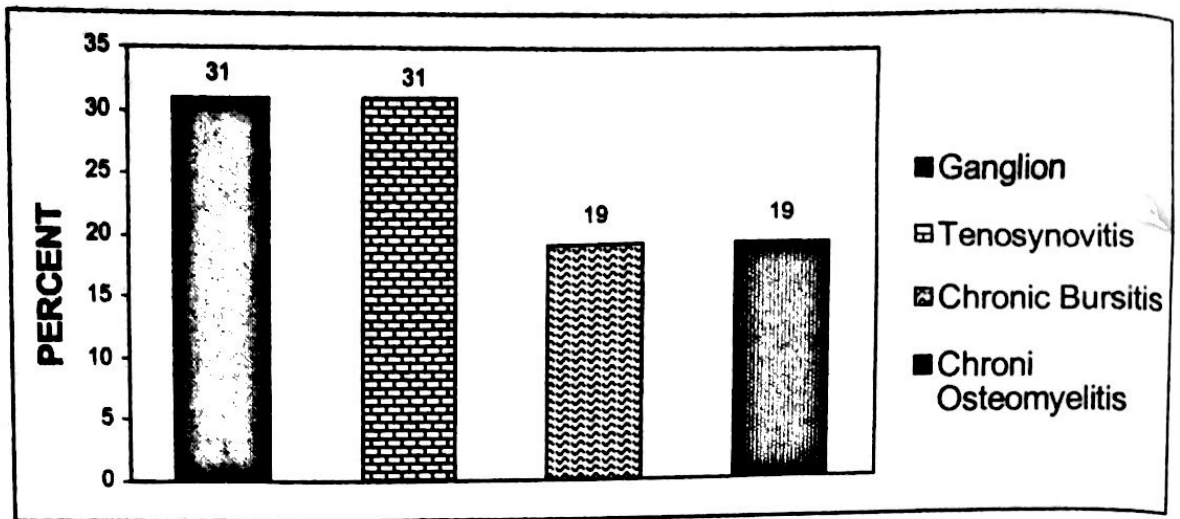
Lesions



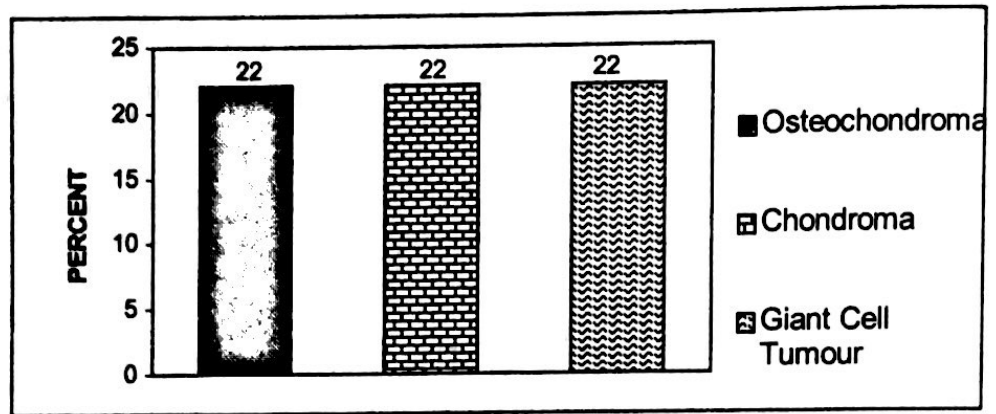
Tumours



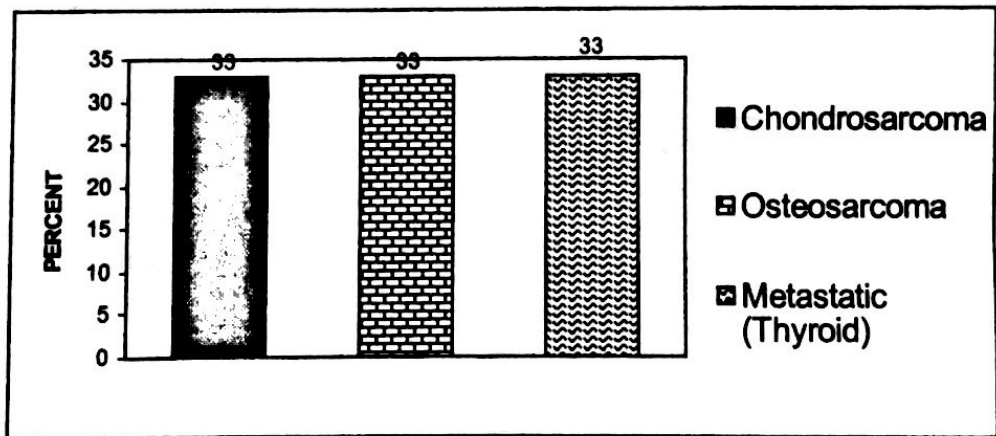
Nonneoplastic Lesions



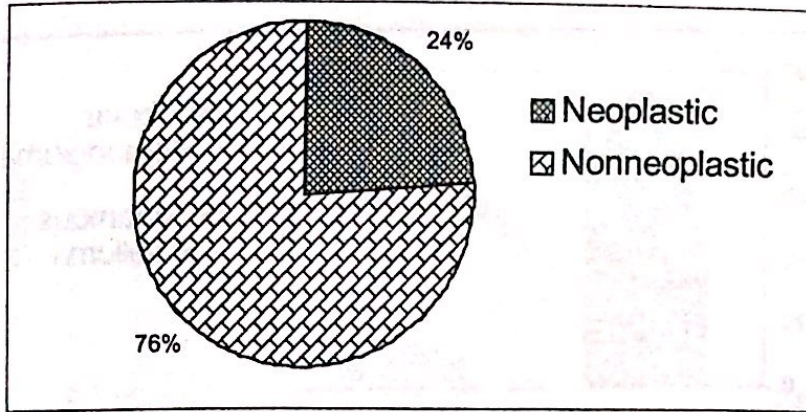
Benign Tumours



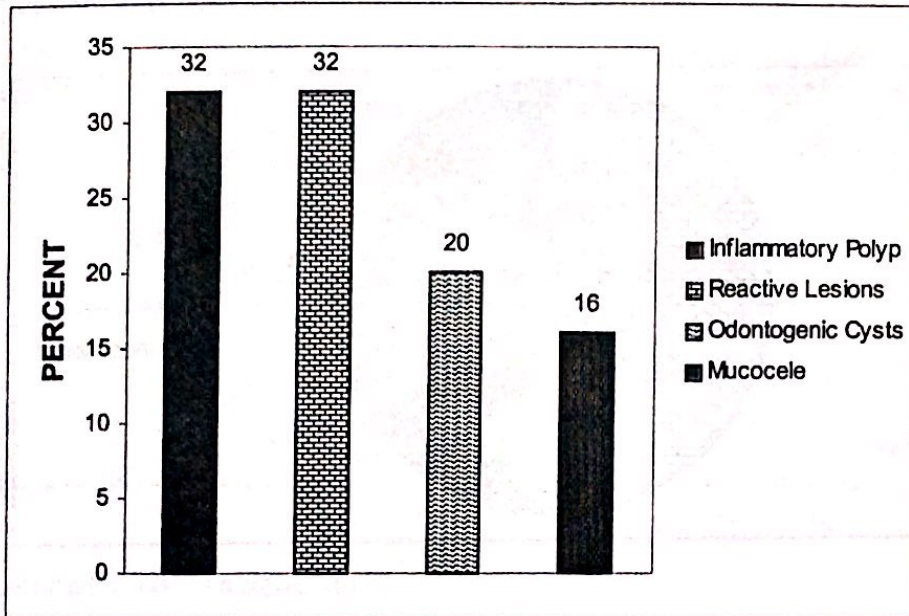
Malignant Tumours



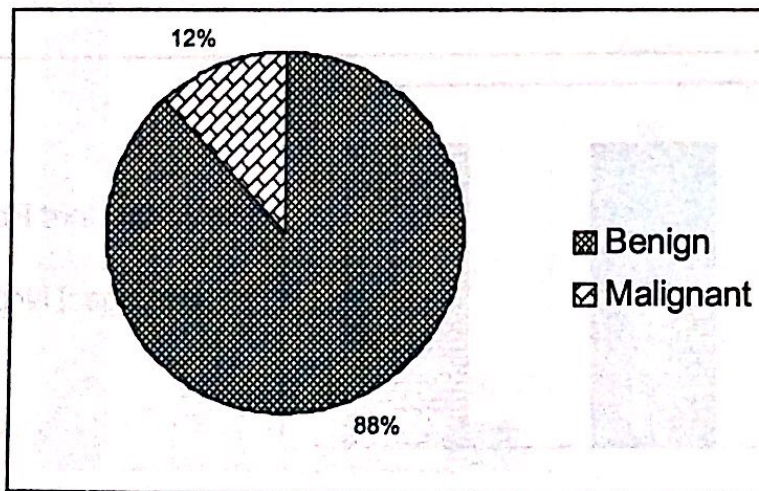
**Oronasal Cavity (33)
Lesions**



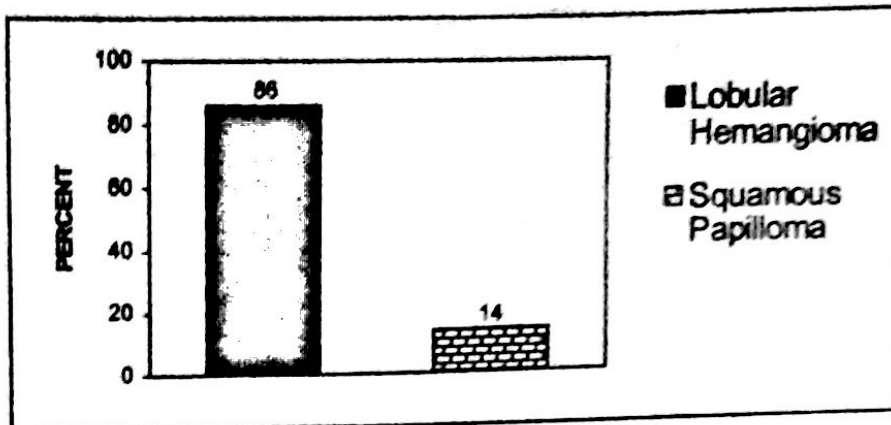
Nonneoplastic Lesions




Tumours



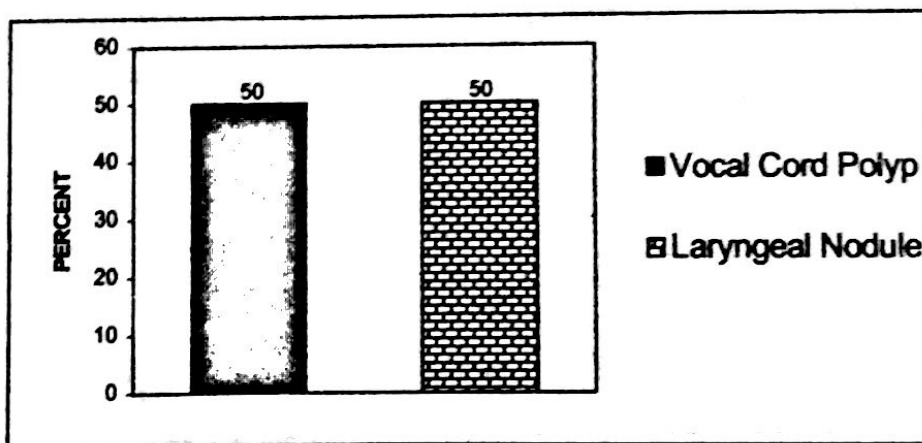
Benign Tumours

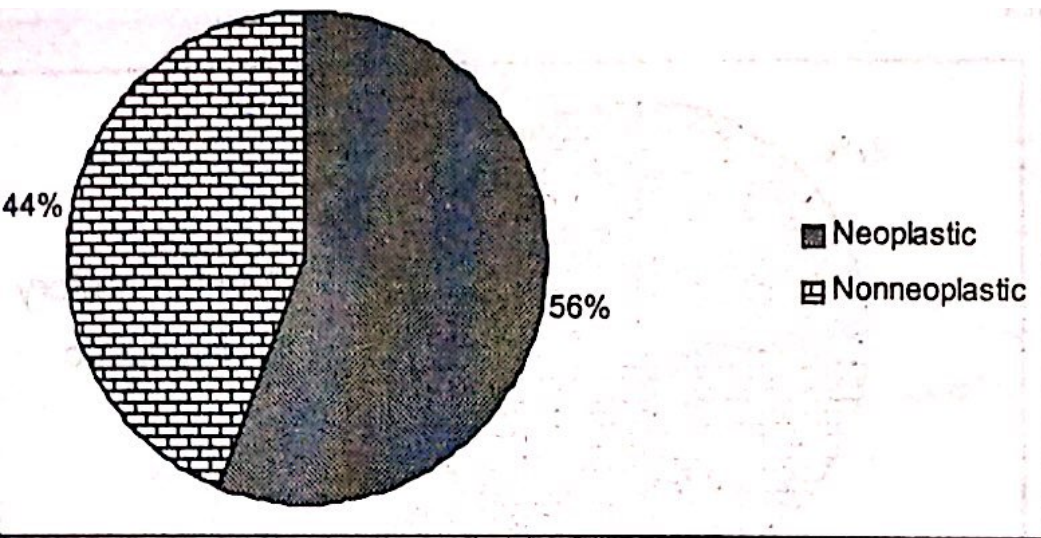


Larynx (11) Lesions

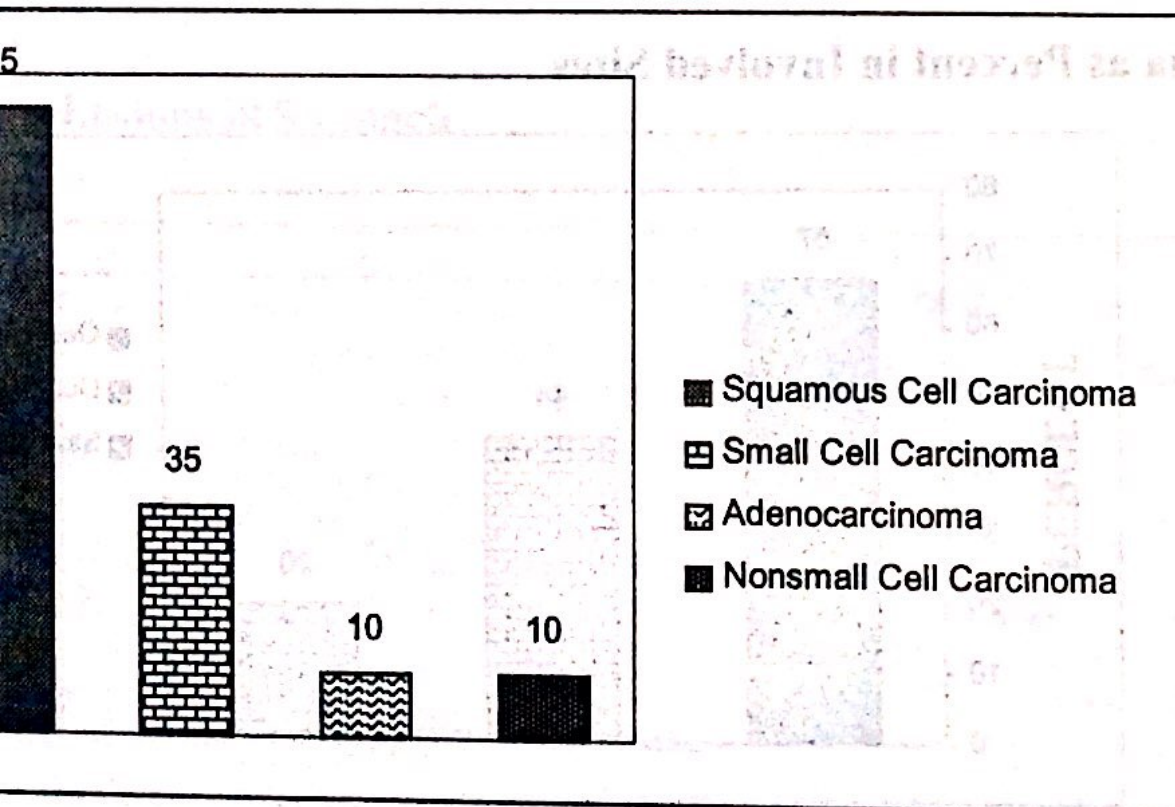


Nonneoplastic Lesions

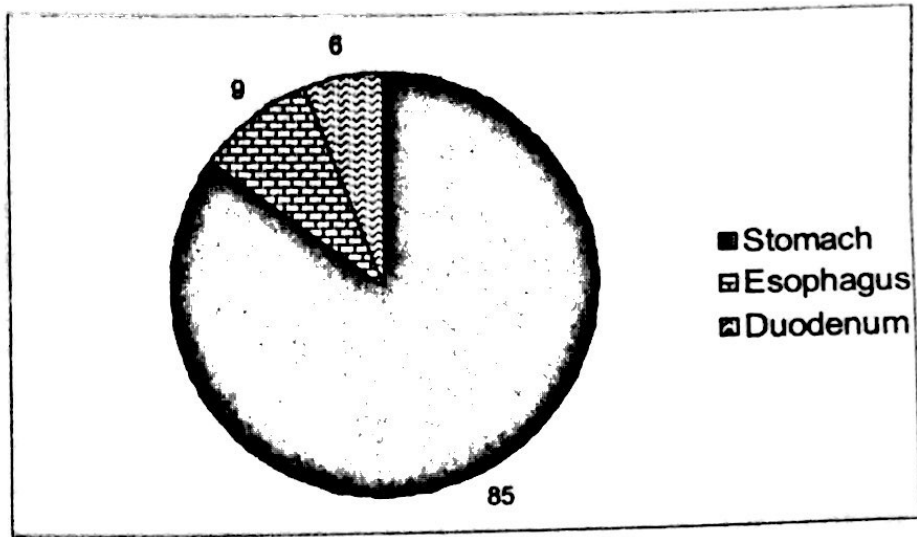




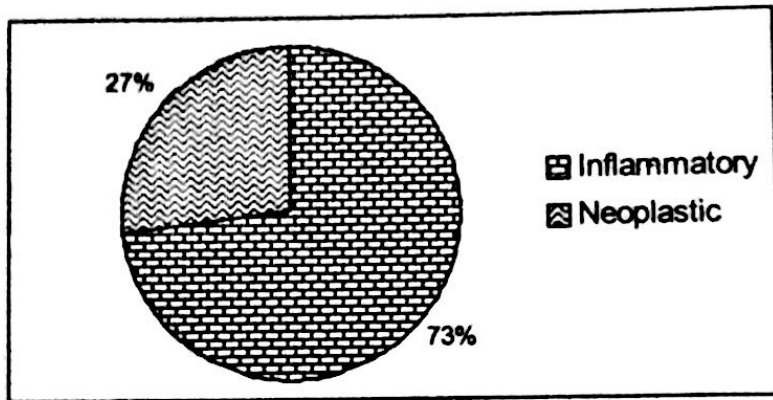
(All Malignant)



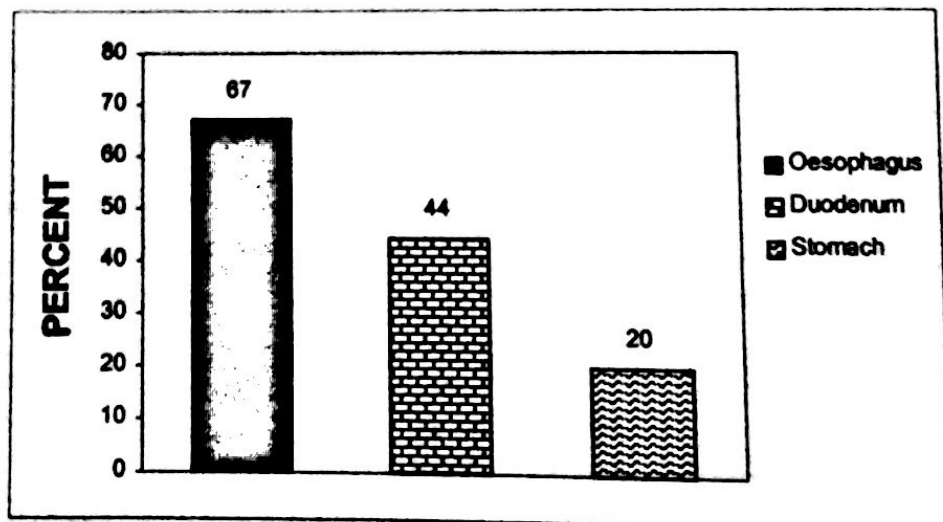
**Endoscopic Biopsy (99)
Sites**



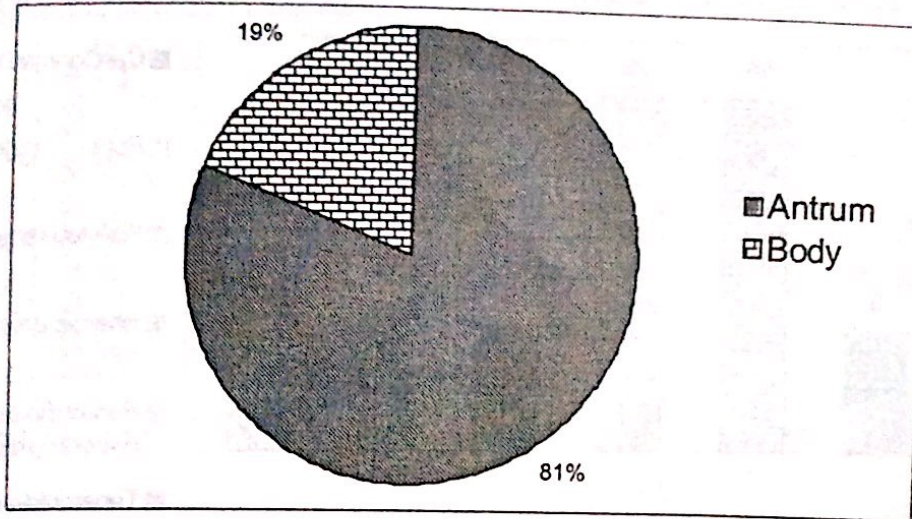
Nature of Lesions



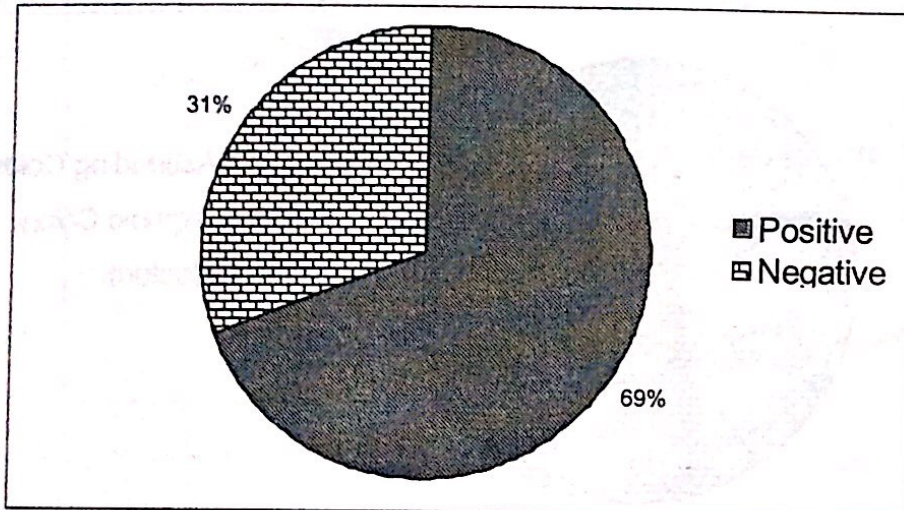
Carcinoma as Percent in Involved Sites



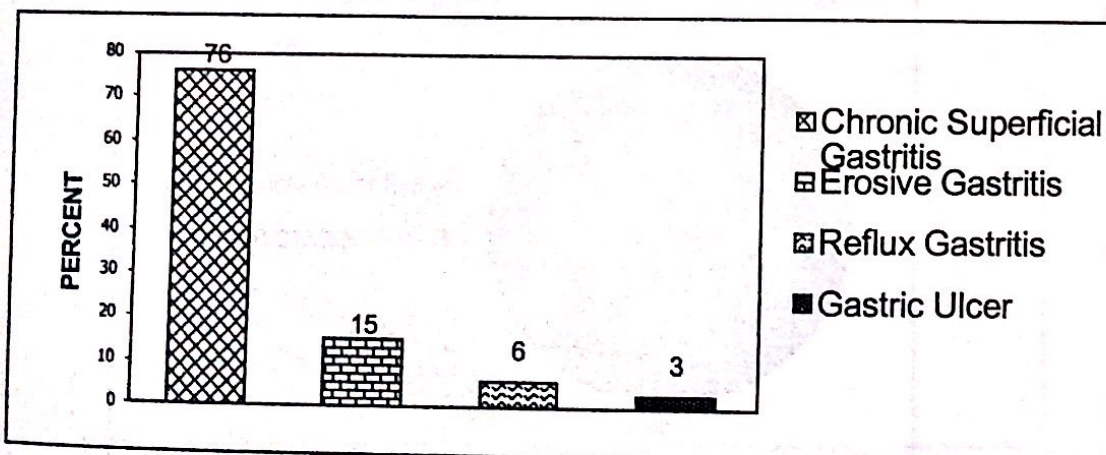
Site of Chronic Gastritis



Helicobacter Pylori in Gastritis

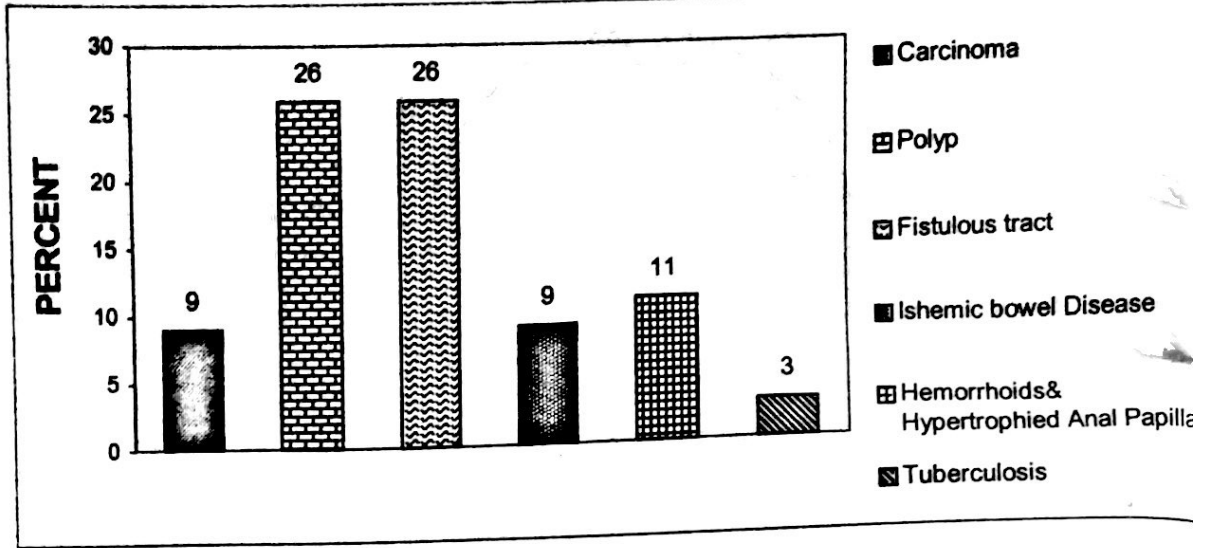


Types of Inflammatory Lesions in Stomach



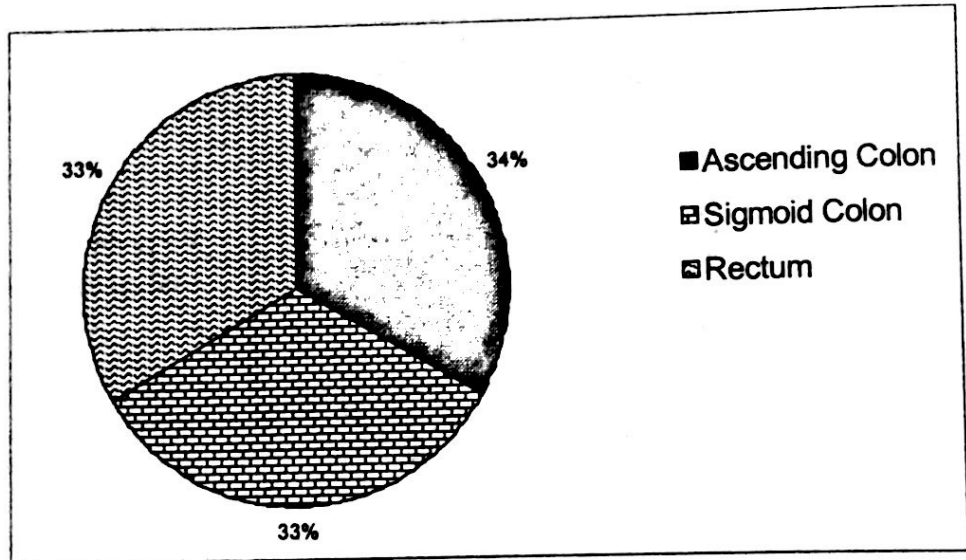
Intestines (35)

Lesions



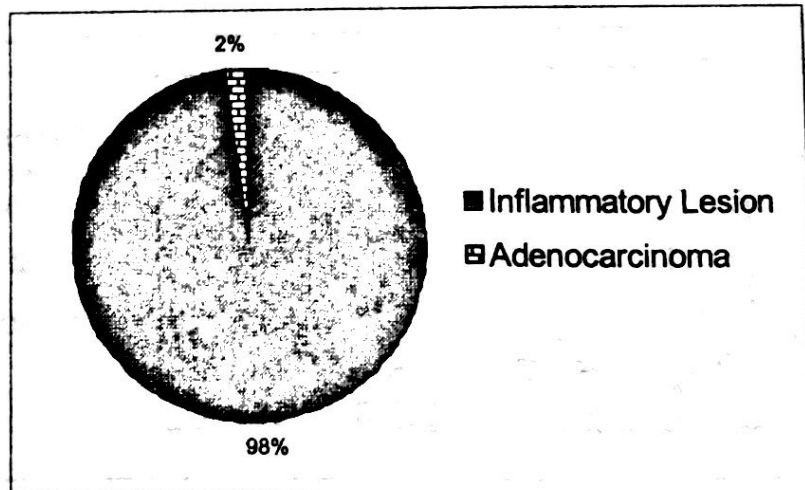
Intestines (35)

Lesions

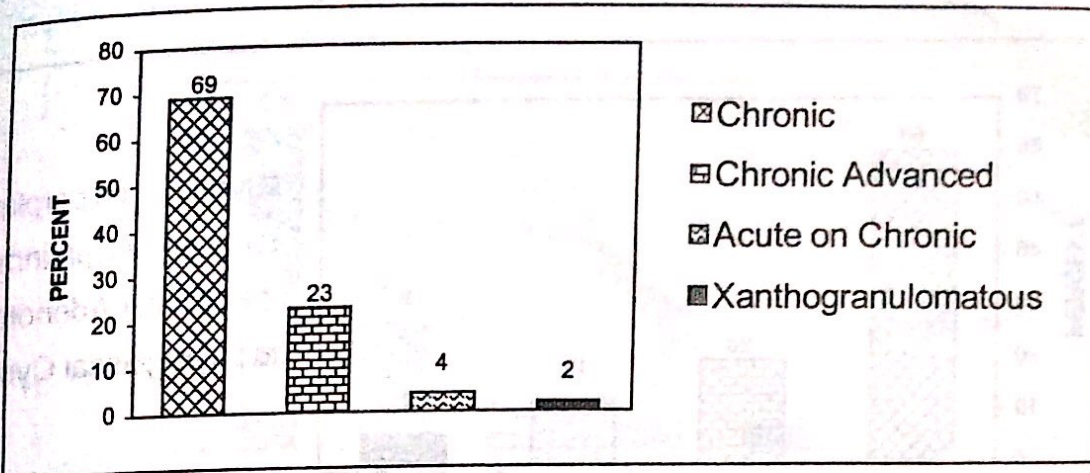


Gall Bladder (144)

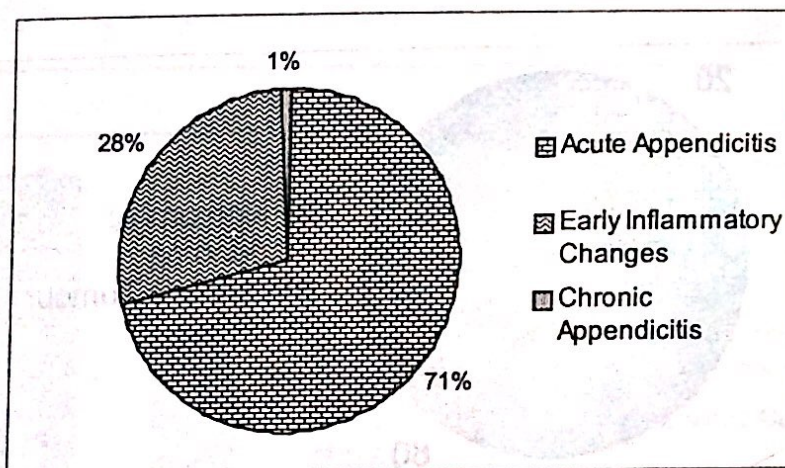
Lesions



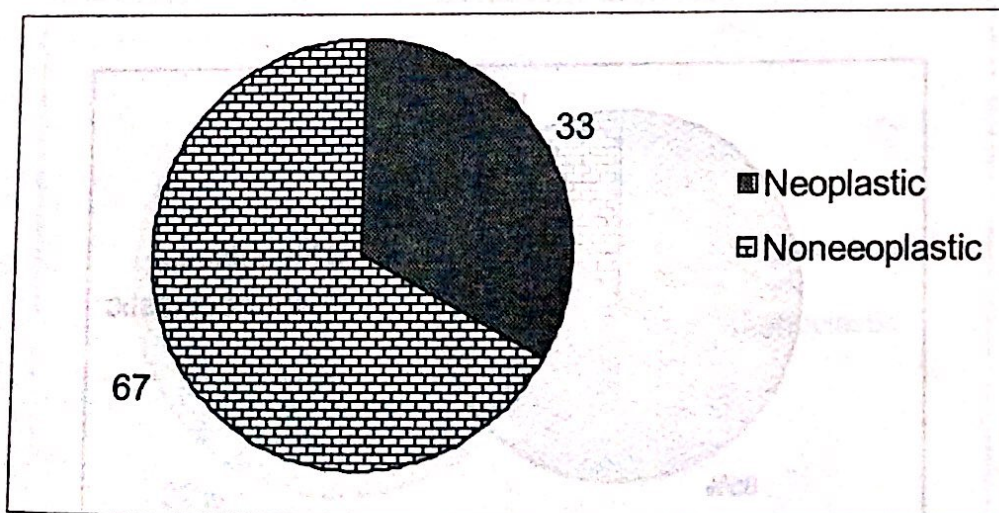
Types of Cholecystitis



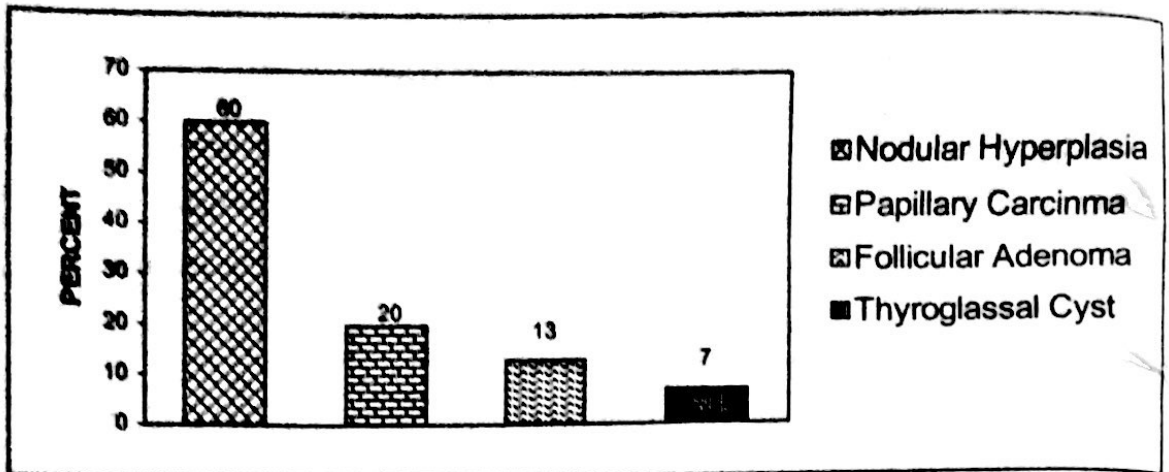
Appendix (146) Lesions



Thyroid (15) Lesions

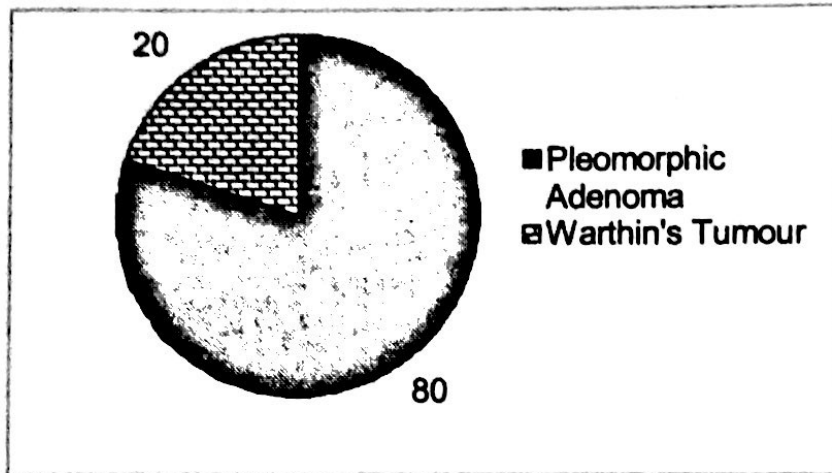


Lesions



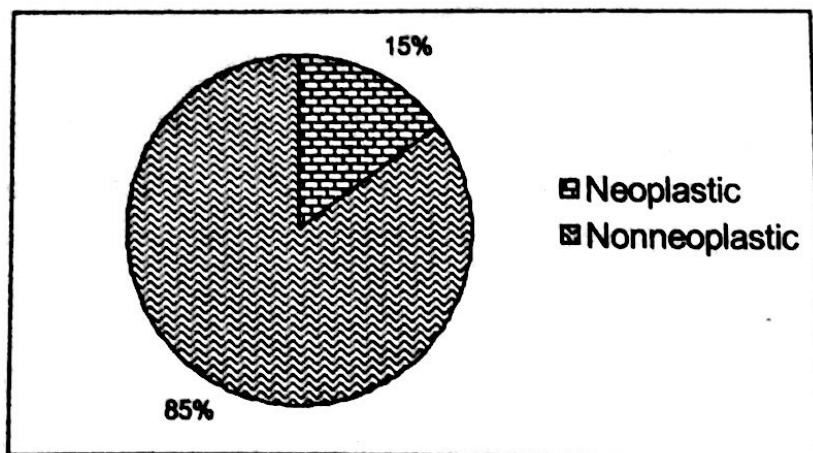
Salivary Gland (5)

Lesions

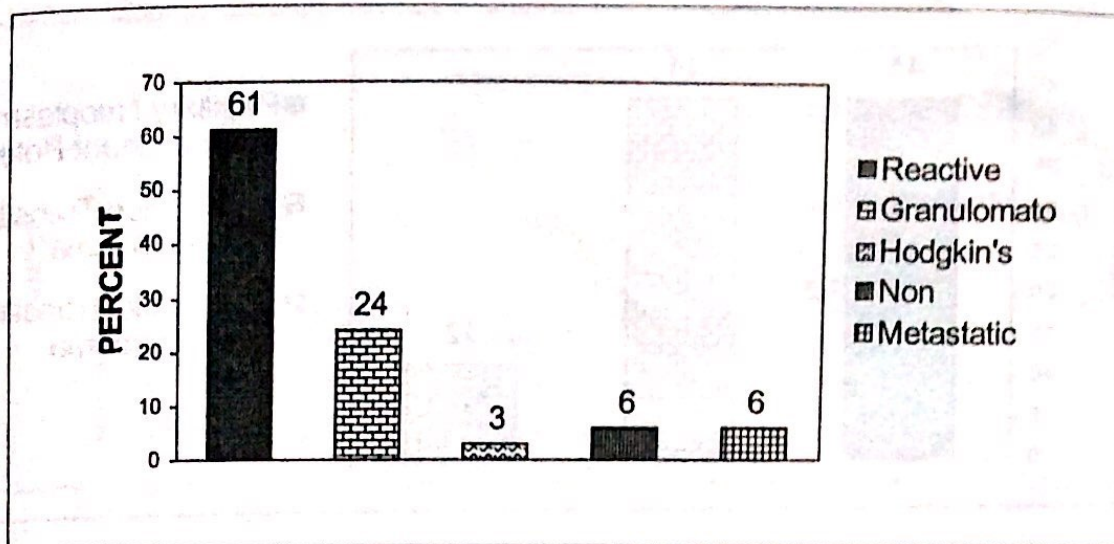


Lymph Nodes (33)

Lesions

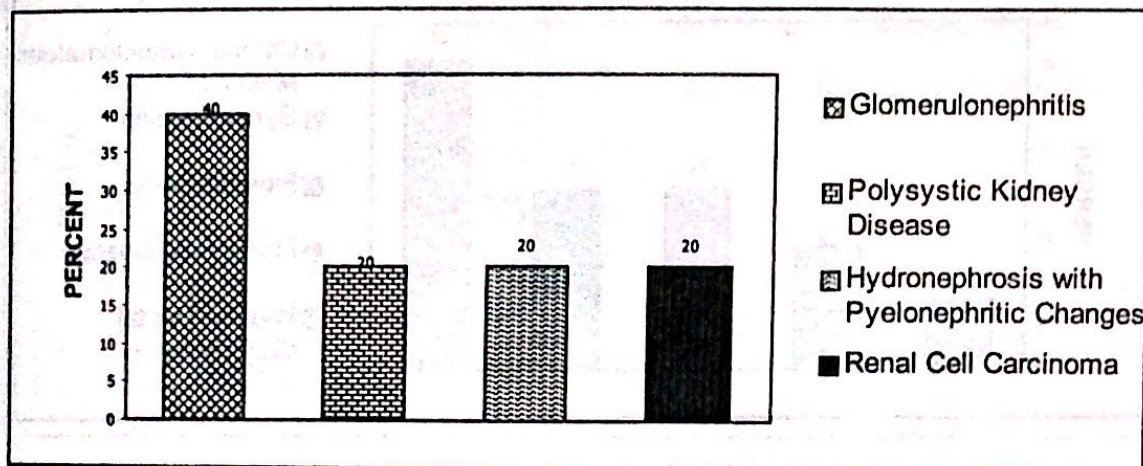


Lesions



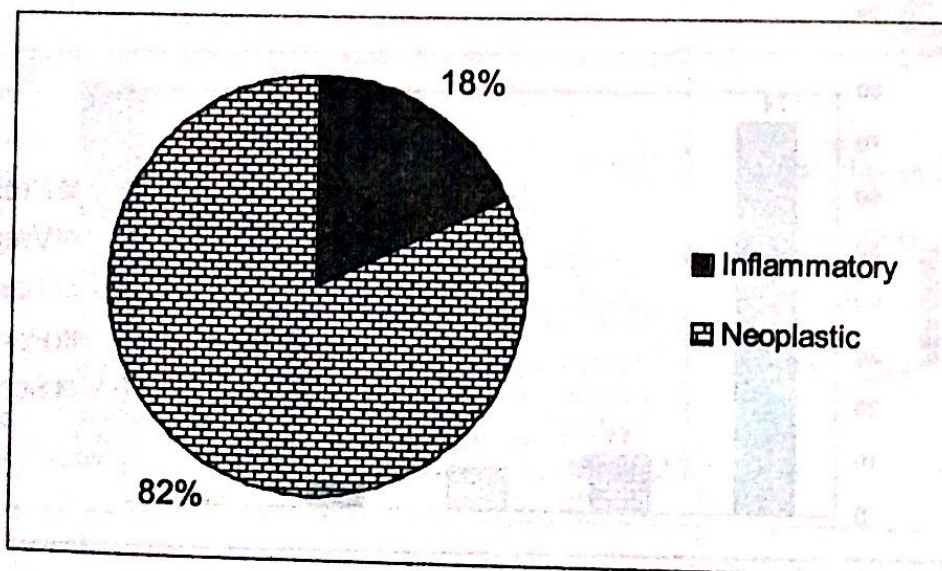
Kidney (5)

Lesions

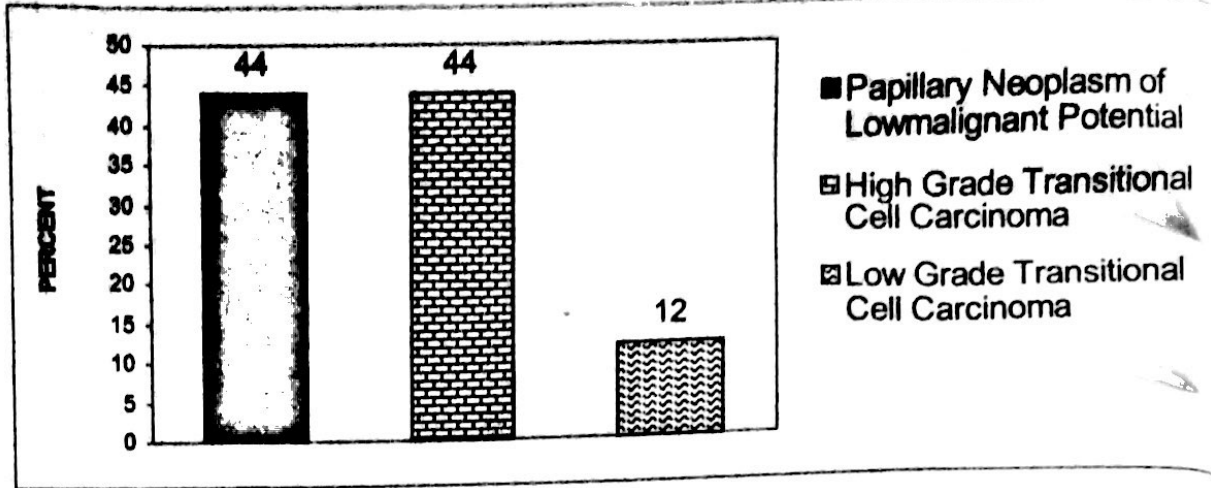


Urinary Bladder (11)

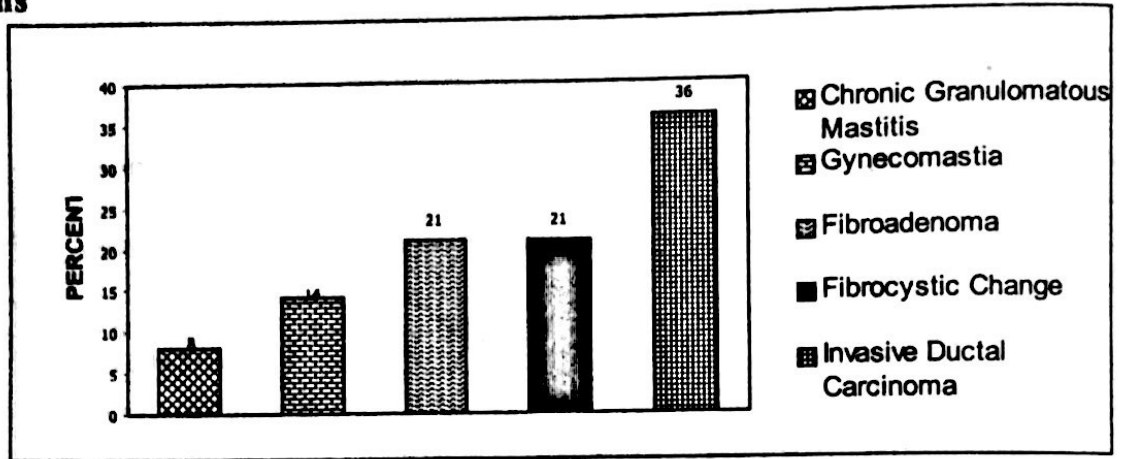
Lesions



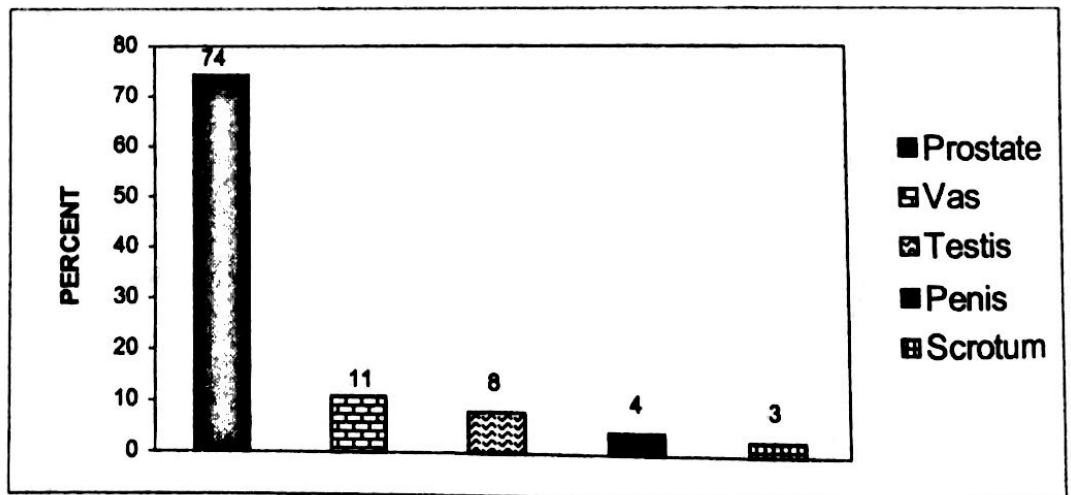
Neoplastic Lesions



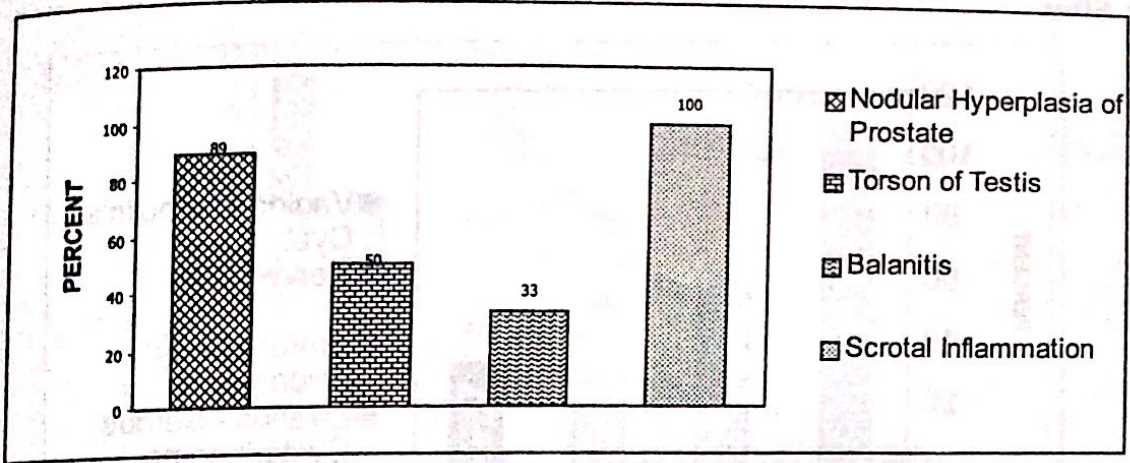
Breast (14) Lesions



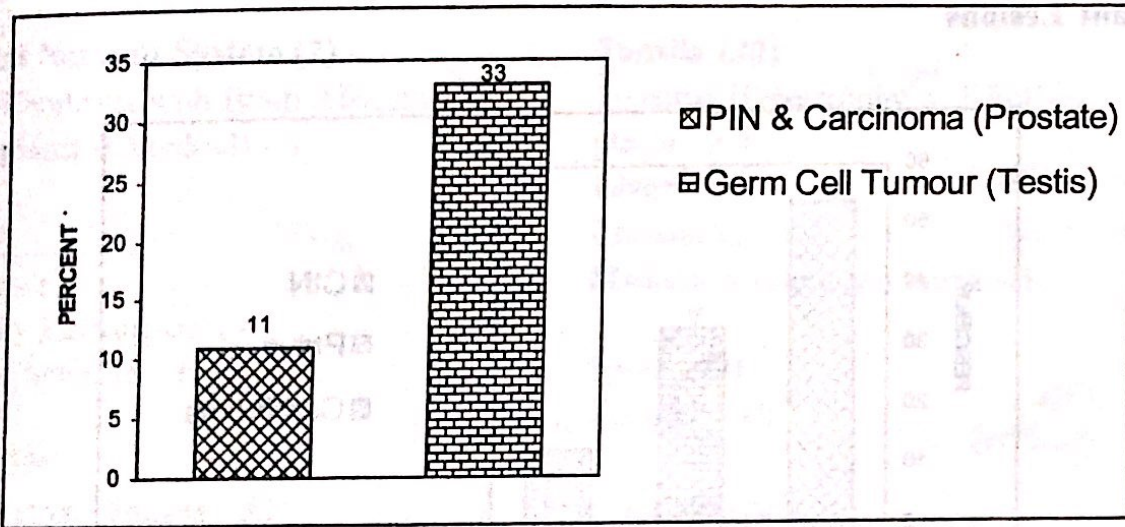
Male Genital System (72) Biopsy Sites



Commonest Lesions

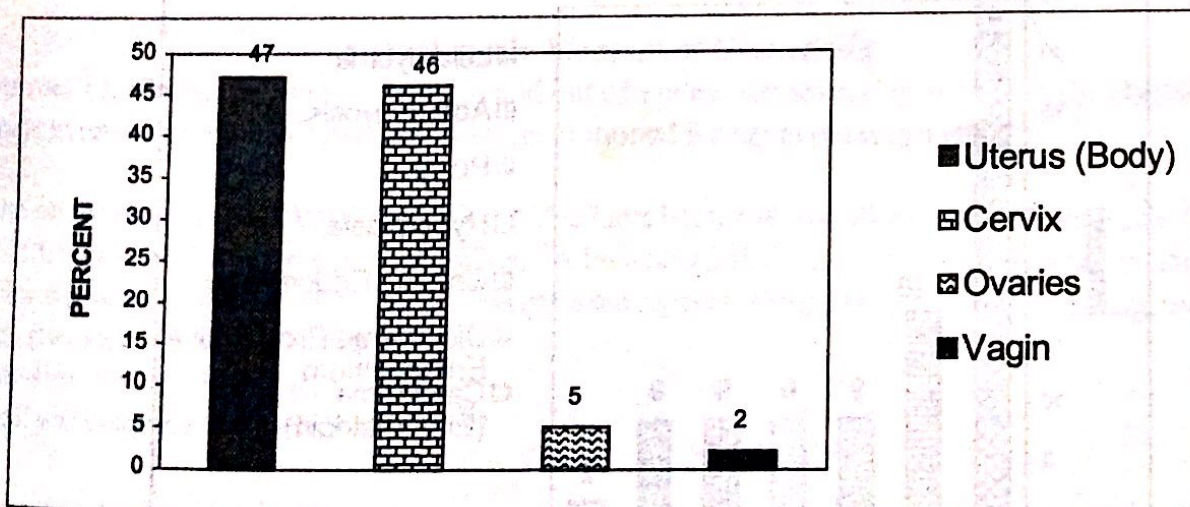


Neoplastic Lesions



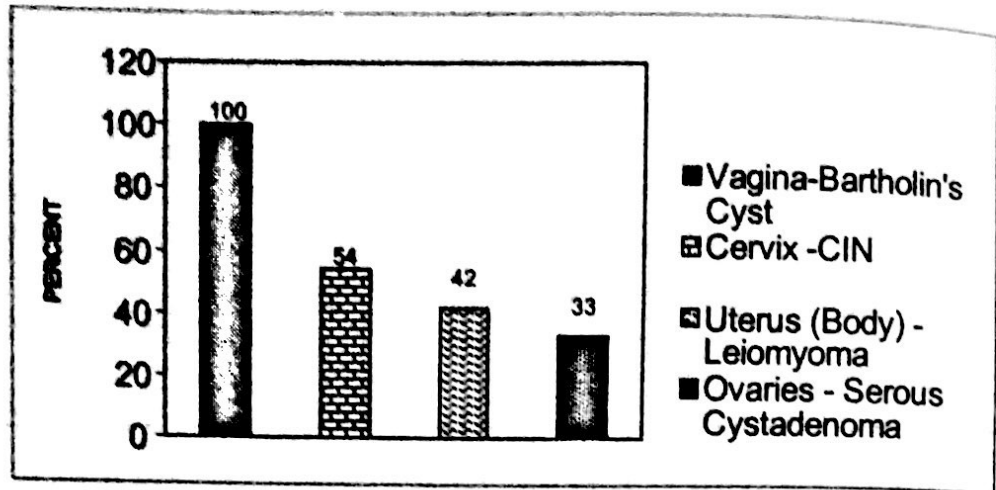
Female Genital System (289)

Biopsy Sites



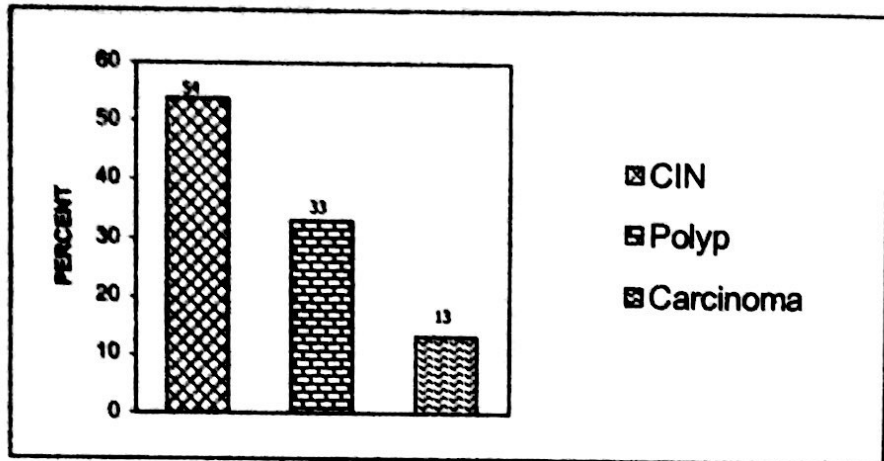
Female Genital System (289)

Biopsy Sites

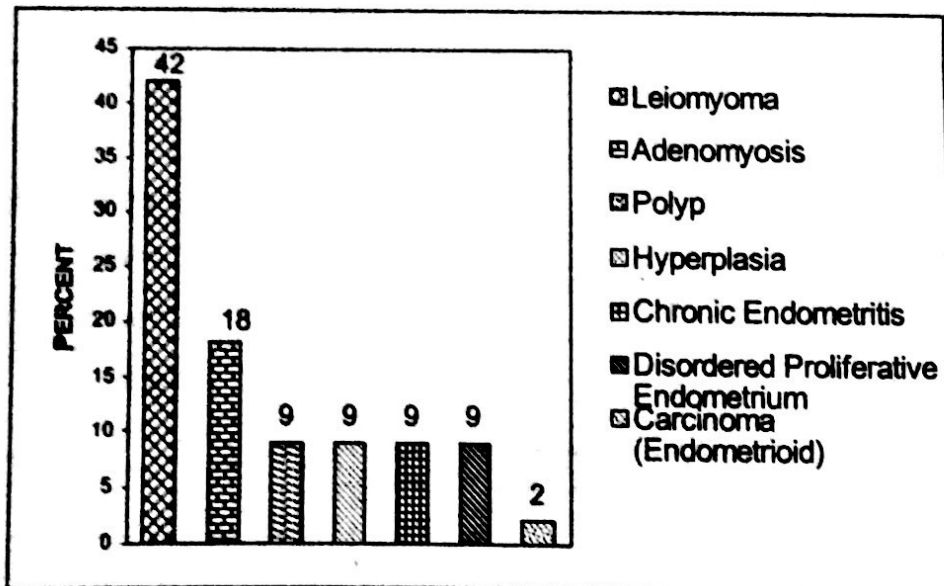


Significant Lesions

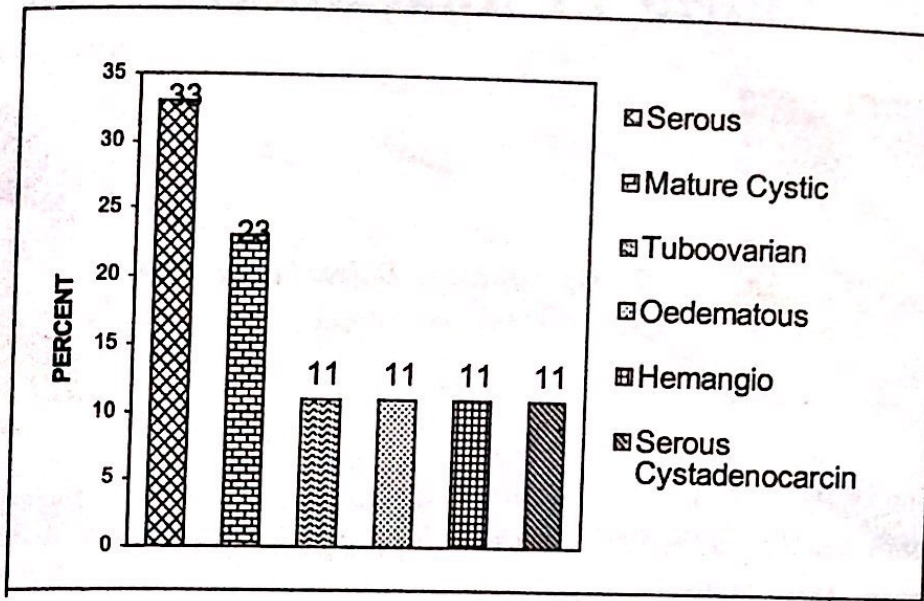
Cervix



Uterus (Body)



Ovaries



Central Nervous System (2)

- Acute Cerebritis with Brain Abscess - 1
- Meningioma (Chordoid) - 1

Eye (3)

- Trauma - 1
- Capillary Hemangioma - 1
- Chronic Scleritis - 1

PIVD (23)

- Degenerative Changes - All

Tonsils (30)

- Tonsillar Hypertrophy with Follicular Hyperplasia - All

Liver (2)

- Chronic Hepatitis - 1
- Metastatic Adenocarcinoma - 1

Spleen (3)

- Rupture - All

Bone Marrow (1)

- Hyperplastic Marrow

□□□

Interns Joke Competition (First Prize)

A Husband's Moment of Realisation

A woman's husband had been slipping in and out of a coma for several months, yet she stayed by his bedside every single day. When he came to, he motioned for her to come nearer.

As she sat by him, he said, "You know what? You have been with me all through the bad times. When I got fired, you were there to support me. When my business failed, you were there. When I got shot, you were by my side. When we lost the house, you gave me support. When my health started failing, you were still by my side... You know what?"

"What dear?" She asked gently.

"I think you bring me bad luck."

Compiled by:
Dr. Kishori Mahat