

Correlation between Invasive Intracranial Pressure Monitoring and Optic Nerve Sheath Diameter in Patients with Traumatic Brain Injury

Shrestha B,¹ Shrestha P,² Ghale P,² Lakshmi pathy G²

¹Department of Surgery -Neurosurgery Unit
Dhulikhel Hospital, Kathmandu University Hospital,
Kathmandu University School of Medical Sciences,
Dhulikhel, Kavre, Nepal.

²Department of Neurosurgery
Upendra Devkota Memorial National Institute
of Neurological and Allied Sciences,
Bansbari, Kathmandu, Nepal.

Corresponding Author

Bibhusan Shrestha

Department of Surgery -Neurosurgery Unit
Dhulikhel Hospital, Kathmandu University Hospital,
Kathmandu University School of Medical Sciences,
Dhulikhel, Kavre, Nepal.
E-mail: sbibhusan@hotmail.com

Citation

Shrestha B, Shrestha P, Ghale P, Lakshmi pathy G. Correlation between Invasive Intracranial Pressure Monitoring and Optic Nerve Sheath Diameter in Patients with Traumatic Brain Injury. *Kathmandu Univ Med J.* 2021;74(2):221-4.

ABSTRACT

Background

In management of patients with traumatic brain injury, intracranial pressure holds an important place. Any untoward rise in intracranial pressure portends dreaded complications. Hence, any delay in detecting the issue is considered unacceptable.

Objective

This study focuses on analyzing the correlation between ultrasound derived optic nerve sheath diameter and intracranial pressure values derived from invasive intracranial pressure monitoring system in a neurosurgical patient with severe traumatic brain injury.

Method

A prospective observational study was performed using a convenience sample technique including all adult patients with traumatic brain injury who had invasive intracranial monitors placed as part of their clinical care. Ocular ultrasound was performed with 5 - 7.5 MHz linear probe of ACUSON X300 ultrasound system while simultaneous intracranial pressure readings were obtained directly from an invasive intracranial pressure monitoring system. The association between optic nerve sheath diameter and invasive intracranial pressure reading was assessed with the Pearson's correlation coefficient and a receiver operator characteristic curve was created to determine the optimal optic nerve sheath diameter cutoff to detect intracranial pressure > 15 cm H₂O.

Result

One hundred and fifteen ocular ultrasounds were performed on 30 individual patients. The mean age of the population involved in this study is 42.13 years ± 1.89 with male preponderance in the ratio of 6:1. Pearson's correlation coefficient of optic nerve sheath diameter and intracranial pressure was found to be 0.844 (p < 0.000) demonstrating a significant positive correlation. The area under the receiver operating characteristic curve was found to be 0.961 (95% confidence interval = 0.93 to 0.99). Based on analysis of the receiver operating characteristic curve, optic nerve sheath diameter > 4.85 mm performed best to detect intracranial pressure > 15 cm H₂O with a sensitivity of 93.5% and specificity of 83%.

Conclusion

Optic nerve sheath diameter is a dependable screening tool to evaluate for elevated intracranial pressure among patients with traumatic nerve injury.

KEY WORDS

Intracranial pressure, Optic nerve sheath diameter, Screening

INTRODUCTION

The notion of monitoring the intracranial pressure as a pointer of dysfunctional intracranial compliance is based upon a historical principle proposed by Monroe and Kellie years ago.^{1,2} Beyond the amount of compensatory reserve available, various catastrophic neurological sequelae occurs leading to untoward outcome in a variety of brain pathologies such as traumatic brain injury, intracranial space-occupying lesions, intracranial hemorrhage, and subarachnoid hemorrhage.³

In terms of accuracy and reliability to date, the intraventricular catheter system is considered the gold standard.⁴ Nevertheless, they are a health-resource intensive modality and are associated with possibilities of complications like hemorrhage and infection.^{4,5} So, with an idea to overcome the associated complications and further to develop a screening tool to avert unnecessary invasive procedures, the idea of non-invasive techniques such as measurement of optic nerve sheath diameter (ONSD) to monitor intracranial pressure flourished. Many works of literature have quoted for and against the technique as routine alternatives in comparison to ventriculostomy. However, to date concrete evidence to establish and guide their use as an alternative to invasive techniques is lacking.

METHODS

We performed a prospective observational study of patients over 18 years who were admitted to neurologic intensive care unit with invasive intracranial monitoring placed as part of their clinical care. This study was approved by the institutional review board of Upendra Devkota Memorial National Institute of Neurological and Allied Sciences, Bansbari, Nepal.

Sample size was calculated using G*Power ver. 3.1.9.4. Correlational bivariate normal model statistics test and A priori type power analysis tool were considered to calculate the sample size. With input parameters as alpha error of 0.05, hypothetical effect size of 0.5, and power of 0.8, the sample size was derived. Patients were enrolled as a convenience sample based on the availability of treating surgeons. Patients, less than 18 years of age or patients with significant ocular trauma were excluded. Informed consents were obtained from patients' family members prior to enrollment. Patients were enrolled between May 1, 2017 to Feb 29, 2020.

The procedures were performed by a single investigator who was trained to perform ocular ultrasonography. Ocular Ultrasounds were performed on ACUSON X300 machine (Siemens Healthcare GmbH, Erlangen, Germany) with a 5-7.5 MHz linear probe using standard ophthalmic B-mode on closed eyelids. The linear probe was applied on the temporal part of the closed upper eyelid with coupling gel. Care was taken not to apply unnecessary pressure

on the globe of eyes. The probe was angled medially and caudally until the hypoechoic optic nerve could be clearly demonstrated posterior to the globe. The optic nerve sheath diameter was then measured 3mm behind the posterior scleral surface of the globe at an angle perpendicular to the optic nerve entry point. For each patient, the investigator performed a single measurement on each eye in the transverse plane while simultaneous intracranial pressure readings were obtained directly from the invasive intracranial pressure monitoring unit. intracranial pressure measurements were continuously recorded electronically during the time frame required to complete ultrasonographic measurements for both eyes. After that these measurements were averaged to yield a mean intracranial pressure for each subject.

Data acquired were analyzed with SPSS (Version 16, SPSS, Chicago, IL). The Pearson's correlation coefficient with a two-tailed p-value was used to assess an association between the two measurements. A receiver operator characteristic (ROC) curve was constructed to determine the optimal optic nerve sheath diameter cutoff to detect intracranial pressure > 15 cm of H₂O.

RESULTS

One hundred fifteen ocular ultrasonographic evaluations were performed on 30 patients, 26 male, and 4 females, with an average age of 42.13 years \pm S.D. 1.89 (range 18-70 years). Among those considered, 80% of them had an alleged history of road traffic accidents resulting in traumatic brain injury, and the remaining 20% were cases with head injury due to fall. All patients considered had Glasgow coma scale (GCS) less than eight at presentation. Pearson's correlation coefficient was used to assess the relationship between the two variables, and it was found to be 0.844 ($p < 0.0000$) (fig. 1). Further, as we had used actual invasive intracranial pressure as the criterion standard, we created a ROC curve to establish the optimal cutoff to optimize ONSD sensitivity and specificity (fig. 2).

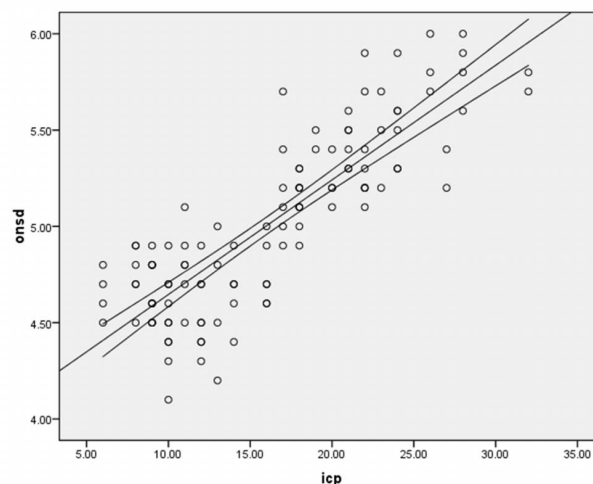


Figure 1. Scatter plot showing correlation between optic nerve sheath diameter and invasive intracranial pressure.

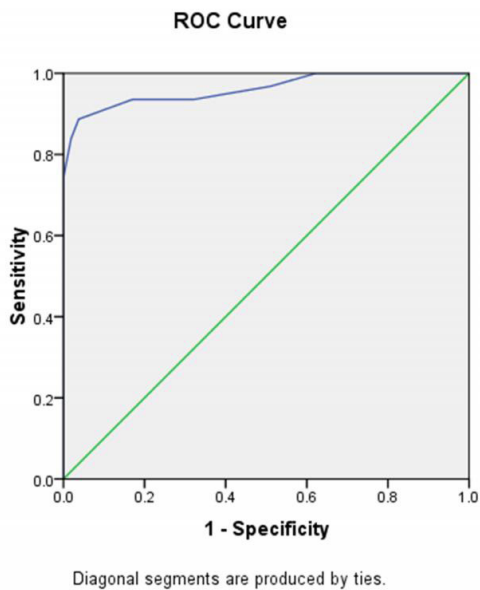


Figure 2. Receiver operator curve created between optic nerve sheath diameter and intracranial pressure status.

The ROC curve demonstrated an area under the curve of 0.961 (95% CI = 0.93 to 0.99). With evaluation of area under curve (AUC) characteristics ONSD value of 4.85 yielded the most favorable balance of test characteristics, with a resulting sensitivity of 93.5% and specificity of 83%.

DISCUSSION

Owing to the special anatomy of the optic nerve, with its sheath being continuous with the meninges, cerebrospinal fluid (CSF) can move freely between the subarachnoid spaces of the intracranial and intraorbital areas. Therefore, patients who suffer from conditions that may increase intracranial pressure may experience an increase of optic nerve sheath diameter.⁶⁻¹⁰ This argument was further substantiated when various papers quoted with their experience that there exists a significant relationship between increased intracranial pressure and optic nerve sheath diameter when evaluated by various modalities involving CT and ultrasound.⁷⁻¹²

Hence in search of an alternative to invasive test for measurement of intracranial pressure, various non-invasive tests such as transcranial doppler ultrasonography and tympanic membrane displacement was tried. Unlike ultrasonography, other monitoring methods such as transcranial doppler ultrasonography and tympanic membrane displacement requires special equipment, were time-consuming and operator-dependent with a high percentage of unsuccessful measurements.^{9,10} Further, these methods were inadequate in urgent situations. But with ultrasonographically derived optic nerve sheath diameter, it was reproducible, easy to perform in emergency scenarios and also an easily learned procedure for medical practitioners with low intra- and inter-observer variation.^{11,12}

To substantiate these findings in our study, we considered 30 patients, 26 male and 4 females, with an average age of 42.13 years \pm S.D. 1.89 (range 18-70 years). Among those included, mean of age group affected, distribution between sexes and cause for severe head injury appeared to be congruent with data offered in the paper by Khadka et al. from one of the oldest neurosurgical tertiary facilities in Nepal.¹³ Similar results were also mirrored by Pathak et al. when selectively considering patients with severe head injury in Kanpur, India.¹⁴

Considering the statistical relationship between ultrasonographically measured optic nerve sheath diameter and invasive intracranial pressure, Geeraerts et al. reported significant positive correlation ($r = 0.71$, $p < 0.01$) similar to our findings $r = 0.844$ ($p < 0.0000$).¹⁵ Blavias et al. also supported similar results while performing bedside ultrasonography to measure optic nerve sheath diameter in emergency setup to diagnose raised intracranial pressure among suspected neurosurgical patients.¹⁶ However, his study differed from our study as he considered CT scan as his gold standard in comparison to invasive intracranial pressure monitoring in our study. Further, results similar to our study from Newman et al. upon assessing and monitoring children with hydrocephalus suspected of having raised intracranial pressure made the issue even more concrete.¹⁷

However, among these studies, the optimal cut-off value for identifying increased intracranial pressure was notably higher than what we observed with our data set, (5.86 mm with a sensitivity of 95% and a specificity of 79% in study of Geeraerts et al. against 4.85 with sensitivity of 93.5% and specificity of 83% in our study).¹⁵ Similarly, other authors from the west also quoted higher values as cut off level for optic nerve sheath diameter while comparing it with invasive intracranial pressure.¹⁶ But point to be noted in these studies were that these studies considered a higher level of intracranial pressure threshold with an intent to intervene in those situations rather than only to diagnose the situation with supranormal intracranial pressure.^{15,18}

Further various studies from different parts of the globes also supported the racial factor confounding the normal size of optic nerve sheath diameter. Ballantyne et al. and various other papers from the west quoted normal value of optic nerve sheath diameter ranging from 2.4 to 4.7 mm (mean, 3.2-3.6 mm) among healthy adults.^{19,20} However, studies from Nepal and its neighboring countries noted higher mean optic nerve sheath diameter as normal among healthy volunteers in their respective country (range 3.8-5.4 mm).²¹⁻²⁴ Hence, the cut-off value attained in this study deem to be a good threshold level to diagnose the increase in intracranial pressure.

The result of this study is limited by its small sample size. Hence, multicenter study with a much larger concentration of the patient population with severe traumatic brain

injury should be partnered into this study to gain further concrete insight into the issue. Also, the observations were performed by a single investigator with limited experience in ocular ultrasonography, which may have limited the generalizability of the results to other observers.

CONCLUSION

It is ascertained that there exists a significant positive correlation between optic nerve sheath diameter measured by ultrasound and invasive intracranial pressure measured simultaneously. Hence, ultrasound derived optic nerve sheath diameter can be used as a screening tool to evaluate intracranial pressure in emergency setting as and when required.

REFERENCES

1. Monro A. Observations on the structure and function of the nervous system. Edinburgh: Creech and Johnson, 1783.
2. Kellie G. An account of the appearances observed in the dissection of two of the three individuals presumed to have perished in the storm of the 3rd, and whose bodies were discovered in the vicinity of Leith on the morning of the 4th November 1821 with some reflections on the pathology of the brain. *Transac Medico Chirurg Soc Edinburgh*. 1824; 1: 84-169
3. Nag DS, Sahu S, Swain A, Kant S. Intracranial pressure monitoring: Gold standard and recent innovations. *World J Clin Cases*. 2019; 7(13): 1535-53
4. Binz DD, Toussaint LG, Friedman JA. Hemorrhagic complications of ventriculostomy placement: a meta-analysis. *Neurocrit Care*. 2009; 10:253-6.
5. Lozier AP, Sciacca RR, Romagnoli MF, Connolly ES, et al. Ventriculostomy-related infections: a critical review of the literature. *Neurosurgery*. 2002; 51:170-81.
6. Helmke K, Hansen HC. Fundamentals of transorbital sonographic evaluation of optic nerve sheath expansion under intracranial hypertension II. Patient study. *Pediatr Radiol*. 1996; 26(10):706-10.
7. Blaivas M, Theodoro D, Sierzenski PR. Elevated intracranial pressure detected by bedside emergency ultrasonography of the optic nerve sheath. *Acad Emerg Med*. 2003; 10(4):376-81.
8. Tayal VS, Neulander M, Norton HJ, Foster T, Saunders T, Blaivas M. Emergency department sonographic measurement of optic nerve sheath diameter to detect findings of increased intracranial pressure in adult head injury patients. *Ann Emerg Med*. 2007; 49(4):508-14.
9. Rosenberg JB SA, Savel RH, Eisen LA. Non-invasive methods of estimating intracranial pressure. *Neurocrit Care*. 2011; 15(3):10.
10. Kristiansson HNE, Bartek J Jr, Andresen M, Reinstrup P, Romner B. Measuring elevated intracranial pressure through noninvasive methods: a review of the literature. *J Neurosurg Anesthesiol*. 2013; 25 (4):14.
11. Ballantyne SA, O'Neill G, Hamilton R, Hollman AS. Observer variation in the sonographic measurement of optic nerve sheath diameter in normal adults. *Eur J Ultrasound*. 2002; 15(3):145-9.
12. Maissan IM D P, Haitsma IK, Hoeks SE, Gommers D, Stolker RJ. Ultrasonographic measured optic nerve sheath diameter as an accurate and quick monitor for changes in intracranial pressure. *Journal of Neurosurgery*. 2015; 123(3):5
13. Khadka NK, Karmacharya BG, Jha R, Adhikary DR, Sharma GR, Bista P, et al. An Audit of Head Injury at Bir Hospital. *Nepal Journal of Neuroscience*. 2013 Jul 1;10(2).
14. Pathak AK, Dev R, Awasthi PM. Study of Injuries among Road Traffic Accident Victim at LLR Hospital, GSVM Medical College, Kanpur UP. *Galore International Journal of Health Sciences and Research*. 2020;5(1):80-3.
15. Geeraerts T, Merceron S, Benhamou D, Vigue B, Duranteau J. Non-invasive assessment of intracranial pressure using ocular sonography in neurocritical care patients. *Intensive Care Med*. 2008; 34 (11):2062-7
16. Blaivas M, Theodoro D, Sierzenski PR. Elevated intracranial pressure detected by bedside emergency ultrasonography of the optic nerve sheath. *Acad Emerg Med*. 2003;10:376-81
17. Newman WD, Hollman AS, Dutton GN, Carachi R. Measurement of optic nerve sheath diameter by ultrasound: a means of detecting acute raised intracranial pressure in hydrocephalus. *British journal of ophthalmology*. 2002 Oct 1;86(10):1109-13.
18. Soldatos T, Karakitsos D, Chatzimichail K, Papatheanasiou M, Gouliamos A, Karabinis A. Optic nerve sonography in the diagnostic evaluation of adult brain injury. *Critical care*. 2008 Jun;12(3):1-7.
19. Ballantyne SA, O'Neill G, Hamilton R, Hollman AS. Observer variation in the sonographic measurement of optic nerve sheath diameter in normal adults. *Eur J Ultrasound*. 2002; 15(3):145-9.
20. Goeres P, Zeiler FA, Unger B, Karakitsos D, Gillman LM. Ultrasound assessment of optic nerve sheath diameter in healthy volunteers. *J Crit Care*. 2016; 31(1):168-71.
21. Maude RR, Hossain MA, Hassan MU, Osbourne S, Sayeed KL, et al. Transorbital sonographic evaluation of normal optic nerve sheath diameter in healthy volunteers in Bangladesh. *PLoS One*. 2013; 8(12): e81013.
22. Amini A, Kariman H, Arhami Dolatabadi A, Hatamabadi HR, Derakhshanfar H, Mansouri B, et al. Use of the sonographic diameter of optic nerve sheath to estimate intracranial pressure. *Am J Emerg Med*. 2013; 31(1):236-9.
23. Shrestha GS. Transorbital sonographic evaluation of normal optic nerve sheath diameter in healthy Nepalese adults. *J Neuroanaesthesiol Crit Care*. 2016; 3:115-8.
24. KC B, Thapa A. Study of Optic Nerve Sheath Diameter in Normal Nepalese Adults Using Ultrasound. *BJHS* 2018;3(1)5: 357-60.