

Functional Outcome of Pediatric Monteggia Fracture Dislocation Treated Surgically in a Tertiary Care Centre of Nepal

Dhoju D, Parajuli B

Department of Orthopedics and Traumatology,
Dhulikhel Hospital, Kathmandu University Hospital,
Kathmandu University School of Medical Sciences,
Dhulikhel, Kavre, Nepal.

Corresponding Author

Darshan Dhoju

Department of Orthopedics and Traumatology,
Dhulikhel Hospital, Kathmandu University Hospital,
Kathmandu University School of Medical Sciences,
Dhulikhel, Kavre, Nepal.

E-mail: docdhoju@hotmail.com

Citation

Dhoju D, Parajuli B. Functional Outcome of Pediatric Monteggia Fracture Dislocation Treated Surgically in a Tertiary Care Centre of Nepal. *Kathmandu Univ Med J.* 2021;74(2):164-7.

ABSTRACT

Background

Monteggia fracture dislocation may need operative management. The fracture of ulna is reduced by closed or open reduction followed by stabilization of ulna with Rush pin, K-wires or Dynamic compression plate.

Objective

To evaluate the Mayo Elbow Performance Score of patients with Monteggia fracture dislocation treated operatively.

Method

It is a retrospective study conducted at Dhulikhel Hospital, Kathmandu University Hospital. All the pediatric patients with Monteggia fracture dislocation managed operatively from January 2011- December 2019 were included in the study. The functional outcome scoring of the effected elbow using Mayo Elbow Performance Score was done in the last follow up.

Result

Forty eight surgically managed Monteggia patients had a mean age of 7.23 ± 2.9 years with male predominance. Left side was the dominant side of involvement with 29 patients. Bado type 1 was the most common type (81.3%). Most of the patient underwent closed reduction and fixation with Rush pin (n=40). All of the patient has excellent (89.6%) to good (10.4%) functional outcome.

Conclusion

Operative management of Monteggia fracture dislocation with complete ulna fracture has excellent to good outcome.

KEY WORDS

Functional outcome, Monteggia fracture dislocation, Operative management, Rush pin

INTRODUCTION

Monteggia fracture dislocation, first described by GB Monteggia in 1814, is a fracture of the upper third of ulna with a dislocation of the radial head.¹ It is a relatively uncommon fracture accounting for 1% of pediatric elbow and forearm fractures with an annual incidence of 1:100,000.² It has been classified into 4 main types and 2 equivalent lesions by JL Bado in 1962.¹ The most common lesion is Bado type I (70%) followed by Bado type III (23%). The incidence for type II and type IV lesions is 3-6% and 1% respectively.³

Although many authors recommend closed reduction and cast immobilization for Monteggia fracture dislocations, failure or loss of reduction and late instability may occur in up to 20% of cases.⁴ Given the deforming muscular forces and inherent soft tissue disruption, maintenance of ulnar length and alignment may not be possible by closed means in all cases, particularly in the setting of complete ulnar fracture.^{5,6} Furthermore, a missed diagnosis exposes the patient to higher morbidity and the complexity of management increases for the treating surgeon as early as 2 weeks after the initial injury.⁷

There are very limited studies done to evaluate functional outcome of elbow using Mayo elbow performance score in patients with Monteggia fracture dislocation treated surgically. Moreover, studies where ulna stabilization in Monteggia fracture using Rush pin is very scanty. Our study has therefore evaluated the Mayo Elbow Performance Score (MEPS) of patients with Monteggia fracture dislocation treated operatively using Rush pin in majority of patients.

METHODS

It is a retrospective study conducted in Department of Orthopedics and Traumatology of Dhulikhel Hospital. All the pediatric patients diagnosed as Monteggia fracture dislocation and presenting to our department from January 2011 to December 2019 were included in the study. Approval for research was taken from Institutional review board of the Kathmandu University Hospital.

Monteggia fracture was diagnosed from the routine antero- posterior and lateral radiograph taken at the time of admission. The fracture was classified according to Bado classification. After anesthetic assessment, patients were consented and listed for manipulation under general anesthesia (MUA) in the operating theater. All Monteggia fractures were treated by a consultant orthopedic surgeon within 24 hours of hospital admission. Initial closed reduction was attempted for simple ulnar fractures and if the reduction of both the ulna and the radial head was satisfactory, limb was immobilized in long arm cast with elbow in 90-100 degree flexion and fore arm in full supination. A satisfactory closed reduction was judged on the basis of the position and the stability of the ulnar fracture

and the satisfactory reduction and maintenance of the position of the radial head. For other patients with proper reduction but unstable radial head, closed reduction and internal fixation of ulna with appropriate size Rush pin was done. For the patients whose reduction was not achieved by closed means, open reduction of ulna was done and fracture was stabilized using plate and screws or Rush pin. Annular ligament repair or reconstruction was not done in any patients included in the study. The immobilization with cast was maintained for 4 weeks following which elbow ROM was started. All the patients were followed up after 2 weeks, 6 weeks, 3 months and 6 months and at the time of implant removal. The functional outcome scoring of the effected elbow using MEPS was done in the last follow up (when patients were admitted for implant removal).

Data was initially recorded in Microsoft excel and later on transferred to IBM SPSS version 24 for statistical analysis.

RESULTS

Out of total 70 Monteggia fracture dislocation patients treated in our center from January 2011 to December 2019, 22 patients with plastic deformation and green stick fracture of ulna were managed conservatively using closed reduction and long arm cast application. The remaining 48 patients underwent surgical treatment and were included in the study. No patient required vascular intervention or had an associated compartment syndrome. All patients had sustained low-energy closed injuries. The mean age of the patients treated surgically was 7.23 ± 2.9 years. Twenty six (54.2%) patients were male and left side was the dominant side of involvement with 29 (60.4%) patients. Thirty nine (81.3%) patients had Bado type 1, 6 (12.5%) had type 3 and 3 (6.3%) had type 4 Monteggia fracture dislocation. In 42 (87.5%) patients closed reduction was possible and were stabilized with Rush pin in 40 patients (fig. 1, fig. 2) and K wire in 2 patients. The remaining 6 patients had to undergo open reduction and internal fixation with DCP (3 patients) or Rush pin (3 patients). Follow up of patients ranged from 8 months to 27 months with a mean follow up of 12.73 ± 4.26 months. Mayo elbow performance score was evaluated in the last follow up. The average performance score was 91.69 ± 4.9 with 43 (89.6%) patients having excellent outcome and 5 (10.4%) patients having good outcome. There was no statistically difference in MEPS between the Bado types. (Table 1) Five (10.4%) patients developed olecranon bursitis and 1 patient had exposed Rush pin after 8 months of surgery for which Rush pin removal was done.

Table 1. Functional outcome according to type of monteggia fracture dislocation.

Monteggia Fracture Dislocation Type	MEPS	Kruskal Wallis test
Bado 1	91.74 ± 4.64	p = 0.645
Bado 3	90.83 ± 7.99	
Bado 4	92.00 ± 0.00	

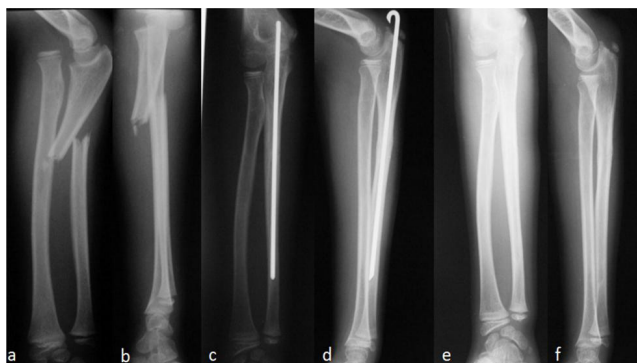


Figure 1. Bado type 1 Monteggia fracture dislocation a,b: Pre operative AP and Lateral view. c,d: Post operative AP and lateral view with Rush pin in situ. e,f: AP and lateral view after rush pin removal

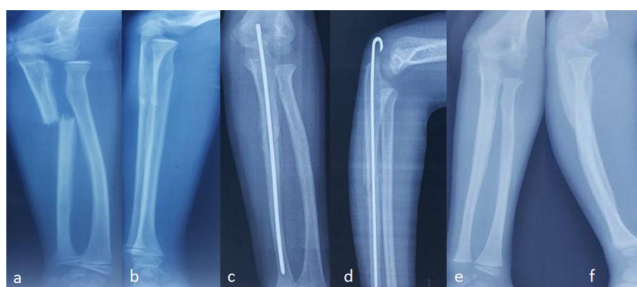

Figure 2. Bado type 3 Monteggia fracture dislocation a,b: Pre operative AP and Lateral view. c,d: Post operative AP and lateral view with Rush pin in situ. e,f: Ap and lateral view after rush pin removal

DISCUSSION

The keys to good results in Monteggia fracture are early recognition of the injury and a stable reduction of the proximal radio-ulnar joint, which requires a sound, anatomical reduction of the ulnar fracture.⁵ Fractures of immature bone, including plastic deformation and buckle and greenstick fractures, are usually more stable, allowing maintenance of anatomical reduction in a cast.⁸ Open or closed reduction and intramedullary nailing is required for complete transverse and short oblique fractures; however long oblique and comminuted ulna fracture may often require plates and screws.^{5,9,10} Our study suggests closed reduction and internal fixation of ulna using Rush pin is a good treatment option for Monteggia fracture with complete/unstable ulna fracture.

The mean age of the patients in our study was 7.23 years which is similar to the study by Leonidou et al. (7.5 years) but higher than the study by Ring et al. (5.9 years) and Peng et al. (6.59 years).^{3,5,11} Majority of patients in our study were male (54%) with left sided injury in 60%. This is similar to the finding in the study by Peng et al. in 25 patients arriving to hospital within 2 weeks of injury (76% male, 52% left sided injury).¹¹

Majority of Monteggia fracture was Bado type 1 (81.3%) followed by Bado type 3 (12.5%) and Bado type 4 (2%). We had no patient with Bado type 2 Monteggia fracture. This finding is similar to the finding by Peng et al. (Bado type 1=

73.8%, Bado type 3= 21.4%), Leonidou et al. (Bado type 1= 70%, Bado type 3= 20%), Ring et al. (Bado type 1= 55.5%, Bado type 3= 30.5%) and Foran et al. (Bado type 1= 63%, Bado type 3= 26%).^{3,5,11,13}

In our study, 48 patients (68.5%) out of 70 patients underwent operative management. Among all the operated patients, 43 (89.6%) had Rush pin stabilization of ulna after reduction. In the study by Ring et al. the number of operated patients was 18 (50%) out of 36 patients.⁵ Among the operated 18 patients, 9 (50%) had intramedullary wire stabilization of ulna. Ring et al. favored selective operative fixation of unstable ulna fractures which provided reliable reduction and caused few complications.⁵ Similarly, in the study by Peng et al., 16 (64%) out of 25 patients presenting to hospital within 2 weeks (fresh group) had undergone operative treatment and intramedullary wire stabilization was done in 6 (37.5%) patients.¹¹ However, in the study by Guven et al., only 30% of patient underwent operative management.¹² Similar finding is seen in the study by Leonidou et al. and Foran et al. where they have operated only 20% and 17% of total patients respectively and all three studies favored non operative management for majority of Monteggia fracture if a close follow up of patient can be achieved.^{3,13} Therefore, it is still debatable regarding whether operative or non operative treatment is better for majority of Monteggia fractures. A prospective multicentric study with higher number of patients comparing both the modalities of treatment is required to make a proper recommendation.

Our study had a mean Mayo Elbow Performance score of 91.69 ± 4.9 with 90% patients having excellent outcome and 10% patients having good outcome. This finding is similar to the finding in the study by Peng et al. where the average MEPS was 96.3 ± 2.7 in the fresh group of 25 patients (patients presenting to hospital within 2 weeks of injury) with 84% having excellent outcome, 12% having good outcome and 4% having fair outcome.¹¹ This signifies operative management of majority of Monteggia fractures yield excellent to good results.

We had a complication rate of 12.5% (6 patients) among operated patients and 8.5% overall (out of total 70 patients) which is higher than the complication rate in the study by Ramski et al. where there were 6 (5%) complications overall: 1 ulna nonunion, 2 compartment syndromes, and 3 transient nerve palsies/neuropathies.⁶ The study by Ring et al. in 36 patients with Monteggia fracture showed no complications.⁵ Similarly there are no complications reported by Leonidou et al. in their study of 40 patients.³ The higher complication rate in our study may be due to higher proportion of operated patients and lack of easy hospital accessibility in earlier stages of complication.

A single centred retrospective study with limited sample size are the major limitation to this study. Functional outcome evaluation was done at variable time-frame which could be a bias to outcome score.

CONCLUSION

Operative management of Monteggia fracture dislocation has excellent functional outcome with average MEPS of

91.69 ± 4.9 and 12.5% complication rate at a mean follow up of 12.73 ± 4.26 months.

REFERENCES

- Letts M, Loch R, Wiens J. Monteggia fracture-dislocations in children. *The Journal of bone and joint surgery*. British volume. Nov 1985;67(5):724-7.
- Landin LA. Fracture Patterns in Children: Analysis of 8,682 Fractures with Special Reference to Incidence, Etiology and Secular Changes in a Swedish Urban Population 1950–1979. *Acta Orthopaedica Scandinavica*. 1983;54(sup202):3-109.
- Leonidou A, Pagkalos J, Lepetsos P, Antonis K, Flieger I, Tsiridis E, et al. Pediatric Monteggia fractures: a single-center study of the management of 40 patients. *Journal of pediatric orthopedics*. Jun 2012;32(4):352-6.
- Dormans J, Rang M. The problem of Monteggia fracture-dislocations in children. *The Orthopedic Clinics of North America*. 1990; 21(2): 251-6.
- Ring D, Waters PM. Operative fixation of Monteggia fractures in children. *The Journal of bone and joint surgery*. British volume. 1996;78(5):734-9.
- Ramski DE, Hennrikus WP, Bae DS, Baldwin KD, Patel NM, Waters PM, et al. Pediatric Monteggia fractures: a multicenter examination of treatment strategy and early clinical and radiographic results. *Journal of Pediatric Orthopaedics*. 2015;35(2):115-20.
- Hubbard J, Chauhan A, Fitzgerald R, Abrams R, Mubarak S, Sangimino M. Missed Pediatric Monteggia Fractures. *JBJS reviews*. Jun 2018;6(6):e2.
- Olney BW, Menelaus MB. Monteggia and equivalent lesions in childhood. *Journal of Pediatric Orthopaedics*. 1989;9(2):219-223.
- Bae DS. Successful strategies for managing Monteggia injuries. *Journal of Pediatric Orthopaedics*. 2016;36:S67-S70.
- Rehim SA, Maynard MA, Sebastin SJ, Chung KC. Monteggia fracture dislocations: a historical review. *The Journal of hand surgery*. Jul 2014;39(7):1384-94.
- He JP, Hao Y, Shao JF. Comparison of treatment methods for pediatric Monteggia fracture: Met vs missed radial head dislocation. *Medicine*. Jan 2019;98(2):e13942.
- Güven M, Eren A, Kadioğlu B, Yavuz U, Kiliçoğlu V, Ozkan K. The results of treatment in pediatric Monteggia equivalent lesions. *Acta orthopaedica et traumatologica turcica*. Mar-Apr 2008;42(2):90-96.
- Foran I, Upasani VV, Wallace CD, Britt E, Bastrom TP, Bomar JD, et al. Acute pediatric Monteggia fractures: a conservative approach to stabilization. *Journal of Pediatric Orthopaedics*. 2017;37(6):e335-e341.