

Ultrasound Guided Stellate Ganglion Block with Dexmedetomidine as an Adjuvant in Complex Regional Pain Syndrome (CRPS)

Shrestha BR, Lama S, Shrestha U

Department of Anaesthesiology

Kathmandu Medical College Teaching Hospital

Sinamangal, Katmandu.

Corresponding Author

Babu Raja Shrestha

Department of Anaesthesiology

Kathmandu Medical College Teaching Hospital

Sinamangal, Katmandu.

E-mail: barashrestha@yahoo.co.in

ABSTRACT

This is a case report of successful use of ultrasound for stellate ganglion (SG) blocks in CRPS I in 11 patients using local anesthetic bupivacaine with injection dexmedetomidine as an adjunct. Ultrasound helped us to deposit Local anesthetics in target area without any noticeable side effects and trauma to adjacent structures.

KEY WORDS

Block, Complex regional pain syndrome, Dexmedetomidine, Stellate ganglion, Ultrasound

Citation

Shrestha BR, Lama S, Shrestha U. Ultrasound Guided Stellate Ganglion Block with Dexmedetomidine as an Adjuvant in Complex Regional Pain Syndrome (CRPS). *Kathmandu Univ Med J.* 2021;73(1):148-51.

INTRODUCTION

Complex Regional Pain Syndrome (CRPS) develops when persistent noxious stimuli from traumatized part of the limb leads to peripheral and central sensitization along with autonomic nervous system involvement. This is a chronic pain condition with continued burning pain with deep sensation of pressure around the affected area, swelling and trophic changes leading to severe degree of disability and loss of function in the limb.

With the advent of ultrasonography (USG), treatment of this condition by stellate ganglion block has greatly increased in terms of safety, precision and efficacy. We have found a good, acceptable result of stellate ganglion (SG) block using USG in this case report of eleven patients diagnosed to have CRPS I during a period of 5 years (2014 Oct – 2018 Nov) in Kathmandu Medical College Teaching Hospital.

CASE REPORT

In this case report, the age of patients ranged from 17 to 72 years, average body weight was 56.8 kilograms. Predominantly there were female patients with the ratio of F: M (9:2).

The minimum duration the patients were suffering with pain till the administration of stellate ganglion block was 4 weeks to a maximum of 28 weeks. Right upper limb was the dominant limb with the diagnosis. One patient had involvement of both the upper limbs with the history of minor fall on hands. Remaining all patients were referred to us with history of immobilization (following Plaster of Paris cast application) or after surgical recovery post Open Reduction and Internal Fixation.

All the patients at presentation gave history of burning sensation, throbbing lancinating pain and numbness in the affected limb. Physical examination revealed swelling, decreased painful mobility due to joint stiffness,

Table 1. Patient characteristics

Age (yr)	Sex	Weight (kgs)	Duration of pain (weeks)	Affected Upper limb	Signs/Symptoms*	VAS (0-10)	Examination
17	F	45	12	R	1,2,3,4,6	8	Edema, Joint stiffness
48	F	50	4	R	1,2,6	7	Sweating, Allodynia, Edema, Moisture
36	F	55	8	R	1,2,3,4,6	7	Hyperalgesia, Edema
30	F	60	6	R	2,3,4,6	8	Temperature, Asymmetry Tenderness, Sweating
65	F	58	10	R	1,3,4,6	8	Stiffness, Edema
52	F	60	12	R	1,2,3,4,6	8	Allodynia, Stiffness, Nail Loss, Hair Loss
24	F	62	8	R	1,3,4,6	7	Edema, Joint stiffness
58	F	55	5	L	2,3,4,6	9	Hair Loss, Allodynia, Hyperesthesia, Edema
72	M	51	28	R+L	1,2,3,4,5,6	9	Allodynia, Skin Color Changes, Edema
32	F	65	7	R	2,3,4,6	7	Temperature Asymmetry, Joint Stiffness, Hyperesthesia
40	M	64	18	L	2,3,4,6	8	Edema, Joint Stiffness, Hyperesthesia

*Signs and symptoms

1-Burning

2-Cold sensation

3-Shooting pain

4-Tingling sensation

5-Pins and needles

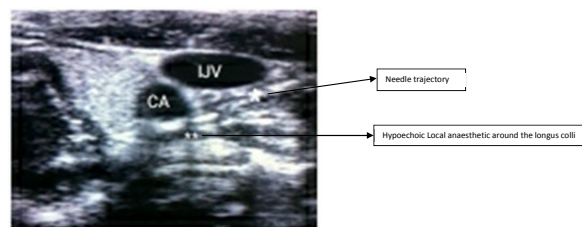
6-Numbness

hyperesthesia and allodynia and even trophic changes in some patients (Table 1), with altered temperature changes when compared to the contralateral limb.

Majority of patients (9 out of 11) were on Pregabalin, Nonsteroidal Anti-Inflammatory Drugs and Paracetamol. Average Visual Analog Score (VAS) for pain was >7 (in scale ranging from 0-10 where 0=no pain and 10=worst pain possible) with psychosomatic component in all the patients. Depending on the history and physical examination and in absence of other obvious vascular and neuronal pathologies, our consensus was to categorize them as CRPS I and written informed consent were taken for SG block.

All patients had basic hemogram, coagulation profile and a baseline ECG and attended the Operating Room on Nil per os. With secured intravenous line and continuous ECG monitoring, the area of interest was prepared aseptically. Using 10 MHz linear USG probe (Mindray Z6) at the level of cricoid cartilage, the transverse process of C7 was identified. Stellate ganglion lies topographically medial to scalene muscles, lateral to the longus colli, esophagus and trachea, and anterior to the transverse processes and prevertebral fascia, and the ganglia is placed posterior to the vertebral artery at C7 level (fig. 1). Under skin infiltration with local anesthetics and utilizing in-plane technique, 21G Stimuplex needle (B Braun, Germany) was directed to the anterior of longus colli and beneath the internal jugular vein under real time visualization of the tip and shaft of the needle. After confirmation of negative aspiration of

blood or any fluid, 10 ml of 0.25% of Inj. Bupivacaine (0.5% Anawin™, 5 mcg/ml, Neon Pharmaceuticals, India) with 15 mcg of Inj. Dexmedetomidine (Xamdex™, 100 mcg/ml, Abbott) was slowly deposited just anterior to the longus



CA- carotid artery, IJV- Internal Jugular Vein

Figure 1. Ultrasound showing the needle trajectory and the local anaesthetic around the longus colli muscle

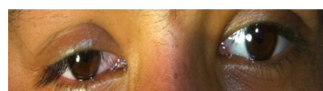

Figure 2. Development of Horner's syndrome after USG guided SG block (Reproduced with permission)

colli muscle. The muscle surrounded with a band of local anesthetic could be visualized as a hypo echoic area. The patients were monitored and observed for subsequent development of the block effect.

Horner's syndrome developed in 8 patients with ipsilateral vasodilatation and nasal stuffiness; in 3 patients, only vasodilatation was noted (fig. 2). Four patients developed hoarseness of voice and dysphagia which disappeared on its own at the time of discharge.

Table 2. Table showing change in VAS following Stellate Ganglion Blocks

Patient number	VAS (pre-procedure)	VAS following 1 st SG Block	VAS following 2 nd SG Block	VAS following 3 rd SG Block
1	8	4	5	0
2	7	5	5	3 to 0
3	7	4	4	0
4	8	5	5	4 to 0
5	8	4	5	3 to 0
6	8	7	7	7
7	7	5	5	3 to 0
8	9	5	5	3 to 0
9	9	8	9	9
10	7	4	5	0
11	8	5	4	0

In the post-operative ward, after 2 hours of VAS assessment, the median VAS score in these patients with the first SG block dropped to average 50% of their initial in 9 patients, whereas the VAS remained the same in 2 patients (6th and 9th patient as shown in Table 2).

Patients on the second visit after 5 days revealed similar VAS for pain as noted in postoperative period post stellate ganglion block prior to the block in 9 patients. In 2 patients, however, who had pain (patients no 6 and 9), VAS stayed at 7 and 8 respectively. They underwent second SG block in the same fashion as the first block. Effective block was confirmed in them with development of Horner's syndrome and vasodilatation. Immediate pain score was reassuring in individual patient with 30% to 50% improvement from VAS score of average 4 to 5. However, the 6th and 9th patient showed no better outcome. They were advised to attend the third procedure after 5 days again. Upon assessment after subsequent 5 days, four patients had VAS score 0/10, with four patients - three, one patient having VAS 4/10 and >7/10 (6th and 9th patient), respectively.

All the patients except four patients with VAS 0/10 underwent third SG block. They were monitored in the postoperative ward and asked to visit after 5 days. The VAS score after the 5 days visit was 0/10 in five patients with restoration of function, cessation of swelling and burning pain. The two patients (6th and 9th) failed completely to show any clinical improvement even after 3rd SG block. They declined further treatment with huge frustration.

During the procedure no inadvertent complications and damage to surrounding structures was noticed and they were uneventful.

DISCUSSION

CRPS I is a chronic neuropathic pain disorder that might limit the functions of the affected limb, sometimes it can

be irreversible. This is a progressive pain condition that results after trauma and immobilization. Early diagnosis of CRPS I and subsequent ganglion block might help reverse the progression. CRPS I is a clinical diagnosis based on the criteria as per Budapest criteria 2003.^{1,2}

The precision of SG block can be increased using real time ultrasound guidance and minimize transgressing important anatomical structures around the target area.³

In this case report, we observed successful results after second block in four patients and only after the subsequent third block five days apart in nine patients. The pain intensity and edema of the limbs progressively reduced with restoration of function. It is observed that chronicity and longer time lapse prior to the SG block might lead to negative outcome as observed in our patients (6th and 9th patient).

The failure to achieve result in these two patients even after observed features of successful block could be due to, besides chronicity to diagnostic incorrectness, over diagnosis or even absence of the ganglia as it is absent in 15% to 20% of the population.⁴

We used dexmedetomidine 15 mcg as an adjuvant with bupivacaine in our patients for stellate ganglion block. As CRPS I is a sympathetically mediated disorder, alpha-2 agonists might reduce the symptoms by blocking the sympathetic activity.⁵ There is a report of clonidine (alpha-2 agonist) being used in lumbar sympathetic block for the lower limb CRPS I with favorable outcome. Alpha-2 agonists produce an anti-nociceptive effect.

We observed gradual decrease in VAS score and swelling in affected limbs with repeated SG blocks especially after second to third block. Literature mentions even five continuous blocks in CRPS I of lower limbs during six weeks.⁶

In this case report, four patients developed hoarseness of voice which resolved on its own with time prior to discharge. Kapral et al. reported RLN (right laryngeal nerve) palsy in only 1 patient of 12 patients in whom ultrasonography showed the spread of the local anesthetic between the carotid sheath, thyroid gland, and the esophagus.⁷ This is the reason why bilateral simultaneous stellate ganglion blocks are not recommended.

The pathophysiology of CRPS based on the literature is associated with sympathetic nervous system dysfunction. Thus, SG block is considered in CRPS I with varied results. However, definitive indication of stellate ganglion block warrants more RCTs.

Ultrasound can safely be employed to block stellate ganglion in CRPS I. Addition of Dexmedetomidine as an adjuvant did not produce any undesirable effects in this case report.

REFERENCES

1. Urits I, Shen AH, Jones MR, Viswanath O, Kaye AD. Complex Regional Pain Syndrome, Current Concepts and Treatment Options. *Current Pain and Headache Reports* [Internet]. *Springer Science and Business Media LLC*. 2018 Feb; 22(2). [PubMed | DOI]
2. Ott S, Maihöfner C. Signs and Symptoms in 1,043 Patients with Complex Regional Pain Syndrome. *The Journal of Pain* [Internet]. Elsevier BV; 2018 Jun;19(6):599–611. [PubMed | Full Text | DOI]
3. Narouze S. Ultrasound-Guided Stellate Ganglion Block: Safety and Efficacy. *Current Pain and Headache Reports* [Internet]. *Springer Science and Business Media LLC*. 2014 Apr 24;18(6).[PubMed | DOI]
4. Mehrotra M, Reddy V, Singh P. Neuroanatomy, Stellate Ganglion. [Updated 2020 Jul 31]. In: StatPearls [Internet]. *Treasure Island (FL): Stat Pearls Publishing*. 2020 Jan. [PubMed | DOI]
5. Coursin DB, Coursin DB, Maccioli GA. Dexmedetomidine. *Current Opinion in Critical Care* [Internet]. *Ovid Technologies (Wolters Kluwer Health)*. 2001 Aug;7(4):221–6. [PubMed | DOI]
6. Hakim KK, Abd El Fatah A. Clonidine in lumbar sympathetic block for lower limb complex regional pain syndrome. *Ain-Shams Journal of Anaesthesiology* [Internet]. Medknow; 2014; 7(3):320-6.
7. Kapral S, Krafft P, Gosch M, Fleischmann D, Weinstabl C. Ultrasound imaging for stellate ganglion block: direct visualization of puncture site and local anesthetic spread. A pilot study. *Reg Anesth*. 1995;20(4):323–8. [PubMed]