

# Childhood Mesenteric Adenitis -The Spectrum of Findings

Shrestha AL,<sup>1</sup> Adhikari G<sup>2</sup>

<sup>1</sup>Department of Neonatal and Pediatric Surgery

<sup>2</sup>Department of Radiology and Interventions

Grande International Hospital,

Dhapasi, Tokha Road, Kathmandu.

## Corresponding Author

Ashish Lal Shrestha

Department of Neonatal and Pediatric Surgery,

Grande International Hospital,

Dhapasi, Tokha Road, Kathmandu.

E-mail: ashishlalshrestha75@gmail.com

## Citation

Shrestha AL, Adhikari G. Childhood Mesenteric Adenitis -The Spectrum of Findings. *Kathmandu Univ Med J.* 2021;73(1):47-51.

## ABSTRACT

### Background

Mesenteric adenitis in children ( $\leq 18$  years) can present with varied findings often causing a diagnostic confusion. In children, considering the inadequacies in history and physical examination, an accurate clinic-radiological diagnosis backed up with laboratory data as indicated becomes important to avoid misdiagnosis and futile interventions.

### Objective

To study the profile of children evaluated for acute abdominal pain and diagnosed as mesenteric adenitis.

### Method

A retrospective review of children with abdominal symptoms, diagnosed to have mesenteric adenitis between January 2018 and December 2020.

### Result

A total of 85 patients (63 males, 22 females) were identified presenting at mean age of 6 years (range 4 months-16 years). Primary Mesenteric Adenitis (PA) was found in 62, Secondary Mesenteric Adenitis (SA) in 11 and Complicated Primary Mesenteric Adenitis (CPA) was identified in 12. All with PA responded well to supportive care. Those with SA were treated for the primary cause and the ones with Complicated Primary Mesenteric Adenitis were managed by treating the complication. All had a favorable outcome.

### Conclusion

When managing a child with abdominal pain, mesenteric adenitis should be considered. Once clinically suspected, tailored management approach results in fruitful outcome.

## KEY WORDS

*Abdominal pain, Mesenteric adenitis, Ultrasound*

## INTRODUCTION

Mesenteric adenitis is a frequent radiological finding in children presenting with abdominal pain. It often presents with dramatic findings mimicking other sinister intra abdominal pathologies. Generally, mesenteric lymph nodes  $\geq 3$  in number and with a short-axis diameter of  $\geq 8$  mm are used as criteria to diagnose Mesenteric adenitis.

It has been noted to be either a primary finding attributable to the cause of abdominal symptoms or secondary to a variety of intra-abdominal conditions and sometimes even with associated complications. On the whole, the condition seems to follow a spectrum in its presentation

We hereby present our data on children treated for mesenteric adenitis with a favorable outcome.

## METHODS

A retrospective study was performed at Grande International Hospital, Tokha Road, Kathmandu, Nepal between 2018 and 2020. Following institutional approval (IRC. Reg. No. 22/2020), a total of 85 patients were recruited. Relevant medical records were reviewed of children  $\leq 18$  years with acute abdominal pain ( $< 5$  days) and mesenteric adenitis on ultrasound, regardless of cause. The ultrasound criteria of lymph nodes  $\geq 3$  in the mesentery with a short-axis diameter of  $\geq 8$  mm was followed. Ultrasound detected incidental mesenteric adenitis and children being evaluated for chronic or recurrent abdominal pain were excluded.

For clinically suspected primary mesenteric adenitis, only ultrasound was ordered. When other pathologies were considered, an ultrasound along with other relevant blood investigations was done as clinically indicated.

Mesenteric adenitis in absence of other intra abdominal pathologies was called PA. When adenitis was secondary to other intra abdominal source, it was called SA. When adenitis was found to coexist with a related complication, it was called CPA. The demographic details were studied and surgical findings were tabulated wherever relevant along with outcomes. The results were analyzed using SPSS 25.0 (SPSS Inc, Chicago, IL, USA).

Summary statistics were used for reporting demographic and clinical characteristics. Categorical variables were expressed as number (%) and continuous variables as mean  $\pm$  standard deviation or median with inter-quartile ranges depending on the distribution of the variable. Chi-square test or the Fisher's exact test was used to ascertain the association between categorical variables.

T-test was used for the analysis of continuous data. The cutoff values of parameters for discrimination of the groups were determined using the receiver operating characteristic (ROC) analysis. At each value, the sensitivity and specificity for each outcome under study were plotted,

thus generating an ROC curve. A p-value of  $< 0.05$  was taken to be statistically significant.

## RESULTS

A total of 85 patients (63 males, 22 females) were identified presenting at a mean age of 3 years (range 4 months-16 years).

**Table 1. Showing age group and distribution of cases of mesenteric adenitis**

| Age (years)        | Number |
|--------------------|--------|
| Preschool (0-6)    | 53     |
| School (7-12)      | 20     |
| Adolescent (13-18) | 12     |
| Total              | 85     |

PA was found in 62, SA in 11 and CPA was identified in 12 as shown in Table 2.

**Table 2. Showing the disease type of mesenteric adenitis**

| Disease type                            | Number |
|---|--------|
| Primary Mesenteric Adenitis             | 62     |
| Secondary Mesenteric Adenitis           | 11     |
| Complicated Primary Mesenteric Adenitis | 12     |
| Total                                   | 85     |

Of 62 children with PA, 21 were suspected to have it on clinical grounds.

Of 21/62, all had peri-umbilical pain with radiation to (Right Iliac Fossa) RIF in 2, 2 had low grade fever, 2 had associated non-bilious vomiting and 1 had loose stools.

Physical findings included normal hydration and soft abdomen without guarding or signs of peritonism. Ultrasound with clinical correlation confirmed the diagnosis. No other investigations were ordered. All were managed with analgesics, hydration and bed rest for few days and as outpatient basis.

Of 41/62, site of pain was peri-umbilical in 31, RIF in 7 and diffuse generalized pain was noted in 3. Fifteen had vomiting, 5 had loose stools and 8 had fever at presentation. Due to inability in making a clinical distinction, a complete blood count was ordered in addition to ultrasound.

A mean Neutrophil/Lymphocyte Ratio (NLR) ratio of 2.7 and Lymphocyte/Monocyte ratio (LMR) of 5.2 was obtained. Once confirmed sonologically, all the 41 children were managed conservatively in lines of PA. Only 10 patients requiring parenteral fluids for dehydration correction were admitted for a mean period of 2 days for supportive care.

All the 62 patients with PA had favorable outcome. They were followed up till 3 years and did not have recurrence of pain.

Of 11 children with SA, 9/11 (81%) had adenitis secondary to appendicular etiology as shown in figure 1.

The mean NLR and LMR were 5.85 and 3.15 respectively for this group. Of these, 2 with resolving appendicitis were treated with oral antibiotics and analgesics as outpatients while the remaining 7 with acute symptoms underwent Laparoscopic appendectomy as a form of surgical management. All had a positive outcome and remained asymptomatic at 3 years follow up.

Of the remaining 2/11, 1 had infective colitis that was treated conservatively and 1 had Ileo-Caecal Tuberculosis that was confirmed on colonoscopy and biopsy. The latter patient was evaluated for sudden abdominal pain of 5 days with significant loss of weight and appetite over 3 months. She was started on Anti-Tuberculous therapy and did well at 6 months, 1 year and 3 years follow up.

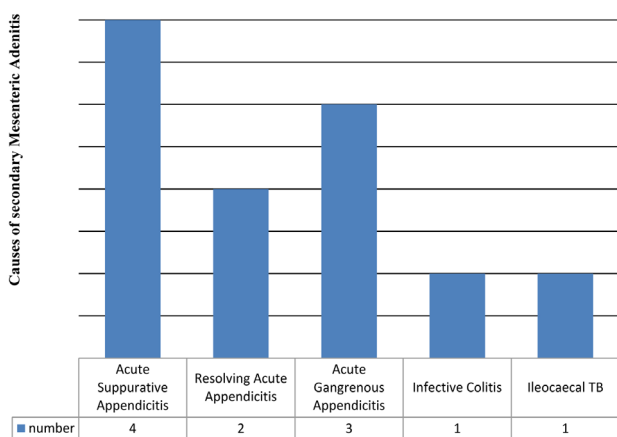


Figure 1. Causes of Secondary mesenteric adenitis

Twelve children with CPA had developed intussusceptions as a probable complication of mesenteric adenitis as shown in Table 3.

Table 3. Management of Complicated Adenitis

| Complicated Mesenteric Adenitis | Number    | Management                              |
|---------------------------------|-----------|---|
| Transient Intussusception       | 7         | Conservative                            |
| Established Intussusception     | 5         | Ultrasound Guided Hydrostatic Reduction |
| <b>Total</b>                    | <b>12</b> |   |

Of these 12 patients, 5 had peri-umbilical pain, 5 had RIF pain, 2 had diffuse pain, 9 had vomiting, 3 had fever, 2 had incessant crying and 3 had loose stools.

In 8/12 children blood tests were done as a priority to rule out other causes followed by ultrasound. Of 8, the mean NLR and LMR were found to be 2.1 and 5.1 respectively. While in the remaining 4 ultrasound alone was sufficient to confirm the diagnosis. Ultrasound had shown mesenteric adenitis along with associated intussusceptions.

Of these, 5 had established ileo-colic intussusceptions and underwent successful hydrostatic saline reductions under Ultrasound guidance. The rest had transient intussusceptions that were rescreened with an ultrasound a few hours later and noted to have spontaneous resolution. All were followed up till 3 years and had no event of recurrence or pain.

## DISCUSSION

Acute abdomen in children accounts for up to 10% of Emergency Room visits and is described as sudden abdominal pain of non traumatic origin presenting within 5 days of onset.<sup>1</sup> Limited with unreliable history and inconsistent clinical findings in children, this often poses a diagnostic challenge.

As important it is to avoid missing sinister pathologies requiring early intervention, equal attention needs to be provided to the conditions that can be managed conservatively. In this context, mesenteric adenitis deserves a special mention in view of its acuteness of presentation and clinical syndrome that may lead to inadvertent surgical interventions. While varying reports of mesenteric adenitis exist in the global literature, by and large, its possibility as a cause of abdominal symptoms cannot be ignored.<sup>2-4</sup>

Often considered, the most frequent clinical mask of acute appendicitis, mesenteric adenitis can mimic a variety of conditions including intussusceptions and gastroenteritis.<sup>5-7</sup> From earliest considerations that included tuberculosis as an etiological factor to a routinely recommended appendectomy, much seems to have evolved in its management now that a definitive pre-operative diagnosis is possible in most situations.<sup>6,8</sup> Even the nodal size used earlier has been largely seeded by the current size criteria on ultrasound as a reference guide to diagnosis in order to avoid false positivity of findings.<sup>6,9,10</sup> A variety of clinicopathological, etiological and temporal classifications have been devised that are thought stimulating to understand if a relatable classification can be followed for Nepalese children as well.<sup>6,7,9</sup>

Instead, a part of the spectrum was observed in our study based on which a unique classification was devised. In keeping with few studies, we identified, acute non specific mesenteric adenitis to be a disease of preschool children ( $\leq 6$  years) with a male predominance (M: F=2.8:1).<sup>8,10,11</sup>

Since majority of children (52/62) with PA had peri-umbilical pain with radiation to RIF in 9/62 and associated symptom complex closely related to appendicitis, it was concluded that a sonological study was mandatory in most children. Considering the relative rarity of acute appendicitis in first decade of life, for any child presenting in this age with symptoms alike appendicitis but contrasting in terms of less sick appearance and low grade temperature ( $\leq 38^\circ\text{C}$ ) and differing in examination characters: 1. Mild

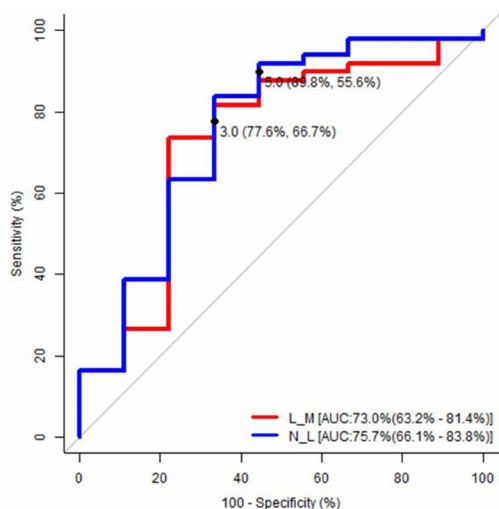
**Table 4. Statistical work up to ascertain LMR and NLR cut off points.**

| Area under the ROC curve (AUC) |                |        |                 |                 |               |       |
|--------------------------------|----------------|--------|-----------------|-----------------|---------------|-------|
| Variable                       | AUC            | SE     | 95% CI          |                 |               |       |
| (L:M) L_M                      | 0.73           | 0.106  | 0.632, 0.814    |                 |               |       |
| (N:L) N_L                      | 0.757          | 0.104  | 0.661, 0.838    |                 |               |       |
| Summary                        |                |        |                 |                 |               |       |
| Variable                       | Youden index J | Cutoff | Sensitivity (%) | Specificity (%) | LR +          | LR -  |
| (L:M) L_M                      | 0.442          | 3      | 77.551          | 66.667          | 2.327         | 0.337 |
| (N:L) N_L                      | 0.454          | 5      | 89.796          | 55.556          | 2.02          | 0.184 |
| Comparison                     |                |        |                 |                 |               |       |
| Comparison                     | AUC Diff.      | SE     | Z - Statistic   | P - Value       | Adj P - Value |       |
| L_M & N_L                      | 0.027          | 0.103  | 0.263           | 0.792           | 0.792         |       |

or diffuse tenderness that is more on deep palpation 2. Absent rebound tenderness 3. Shifting tenderness (shift of tenderness from right to left lower abdomen at change of position from supine to left lateral), the first investigation of choice should be ultrasound followed by blood tests if required.

In contrary, for children beyond the first decade, ultrasound alongside blood tests seems to be a reasonable working plan. A higher LMR in PA and a higher NLR ratio in acute appendicitis should help in hinting the diagnosis in most cases aided with findings of ultrasound.

Based on statistical analyses, a cutoff value of the LMR to favor the possibility of PA or CPA was assigned using table 4 and ROC curve analyses (fig. 2)



**Figure 2. ROC curve**

Based on the most prominent point on the ROC curve for sensitivity (73.5%) and specificity (66.6%), a cutoff value of 3.0 was recommended. (fig. 2). The area under the curve (AUC) was 73 (95% CI: 63.21% - 81.4%,  $p < 0.015$ ). Also, the cutoff value of the NLR for SA (secondary to appendicitis) was decided using ROC curve analyses likewise. Based on the most prominent point on the ROC curve for sensitivity (89.8%) and specificity (55.6%), a cutoff value of 5.0, was recommended (fig. 2). The area under the curve (AUC) was 75.7 (95% CI: 66.1% - 83.8%,  $p < 0.007$ ).

Once diagnosed, PA in view of predominantly viral etiology can be managed expectantly with correction of hydration and electrolytes in those with vomiting and dehydration, pain control and bed rest. Based on clinical judgment, both inpatient and outpatient management can follow.

In our set of patients, it was noted that most (81%) of the SA was appendicular in origin excepting 2, of which one was Tuberculous and the other was infectious colitis of probable Yersinial etiology. In latter, in absence of stool culture the diagnosis is only retrospective and speculative.<sup>12</sup> The standard management plan should follow in this category.

A third category of CA was suggested in view of mesenteric adenitis that was coexistent with complications namely intussusceptions. With a sensitivity and specificity of 98%, sonography is the present imaging modality of choice to diagnose intussusceptions that may or may not require intervention.<sup>13</sup> Again, clinical distinction based on history and examination findings are not always sufficient to make a diagnosis with surety with  $\leq 40\%$  having a classical presentation of a triad consisting of colicky abdominal pain, a palpable mass and red currant jelly stools.<sup>13</sup> In these patients the treatment of associated complications holds priority.

On the whole, mesenteric adenitis seems to follow a spectrum in its presentation of which only a fraction could be deciphered in our set of patients. We recommend an index of clinical suspicion and goal directed investigations for timely recognition and avoidance of futile interventions.

**CONCLUSION**

Mesenteric Adenitis is an important cause of Pediatric Acute abdomen and can present with spectrum of findings. In preschool children considering likelihood of PA following clinical assessment, ultrasound should be the first investigation of choice as it offers radiological aid to distinction in most patients. Blood investigations can be reserved for selected children in whom appendicitis is still

a possibility. A NLR of  $> 5$  may indicate Acute appendicitis or SA with likely appendicular etiology while LMR of  $> 3$  may favor PA or CPA. When SA is diagnosed, primary source needs to be addressed and for CPA, the specific complication should be treated.

## REFERENCES

1. Hijaz NM, Friesen CA. Managing acute abdominal pain in pediatric patients: current perspectives [Internet]. Vol. 8, *Pediatric Health, Medicine and Therapeutics*. Dove Press; 2017 [cited 2021 Jan 23]. p. 83–91. Available from: <https://www.dovepress.com/managing-acute-abdominal-pain-in-pediatric-patients-current-perspectiv-peer-reviewed-fulltext-article-PHMT>
2. Balakrishnan VS, Aroor S, Kumar S, Kini PG, Saseendran A. Mesenteric lymphadenopathy in children with chronic abdominal pain. *Sri Lanka J Child Health*. 2018 Jan 1;47(4):348–53.
3. Sabal S, Poswal L, Gediya S, Goyal S. Mesenteric lymphadenopathy in children with recurrent abdominal pain. *Int J Contemp Pediatr*. 2017 Jun 21;4(4):1525–8.
4. Rathaus V, Shapiro M, Grunebaum M, Zissin R. Enlarged mesenteric lymph nodes in asymptomatic children: the value of the finding in various imaging modalities. *Br J Radiol*. 2005 Jan;78(925):30–3.
5. Özdamar MY, Karavaş E. Acute mesenteric lymphadenitis in children: findings related to differential diagnosis and hospitalization. *Arch Med Sci AMS*. 2020;16(2):313–20.
6. Helbling R, Conficconi E, Wyttenbach M, Benetti C, Simonetti GD, Bianchetti MG, et al. Acute Nonspecific Mesenteric Lymphadenitis: More Than “No Need for Surgery.” *Bio Med Res Int*. 2017;2017:9784565.
7. Sologub EA, Karaseva OV, Timofeeva AG. Non-specific mesenteric lymphadenitis in children (literature review) [Internet]. Vol. 10, *Pediatric pharmacology*. 2013 [cited 2021 Jan 21]. p. 18-25–25. Available from: <https://www.pedpharma.ru/jour/article/view/249>
8. KM, Wadhwa L. Clinical profile and causes of mesenteric lymphadenitis in children. *Int J Contemp Pediatr*. 2016 Dec 28;3(2):550–2.
9. Maconi G, Radice E, Porro GB. Mesenteric Lymphadenopathy. In: Maconi G, Porro GB, editors. *Ultrasound of the Gastrointestinal Tract* [Internet]. Berlin, Heidelberg: Springer; 2007 [cited 2021 Jan 21]. p. 11–8. (Medical Radiology). Available from: [https://doi.org/10.1007/978-3-540-49841-4\\_2](https://doi.org/10.1007/978-3-540-49841-4_2)
10. Cai B, Yi H, Zhang W. Reference intervals of mesenteric lymph node size according to lymphocyte counts in asymptomatic children. *PLoS One*. 2020;15(2):e0228734.
11. Chanchlani R. Clinical Profile and Management of Mesenteric Lymphadenitis in Children - Our Experience [Internet]. *International Journal of Orthopaedics Traumatology & Surgical Sciences*. 2015 [cited 2020 Dec 19]. Available from: <https://ijotss.com/>
12. Bertelli L, Masetti R, Bardasi G, Maretti M, Gargano T, Corsini I, et al. Two cases of abdominal pain in children with mesenteric lymphadenitis due to Yersinia pseudotuberculosis infection. *J Pediatr*. 2014 Aug;165(2):411-411.e1.
13. Sanchez TR, Corwin MT, Davoodian A, Stein-Wexler R. Sonography of Abdominal Pain in Children: Appendicitis and Its Common Mimics. *J Ultrasound Med Off J Am Inst Ultrasound Med*. 2016 Mar;35(3):627-35.

## ACKNOWLEDGEMENT

The authors would like to specially thank Mr. Bijesh Yadav for providing statistical input for the study.