

Percutaneous Ilio-Sacral Screw Fixation in Supine Position under Fluoroscopy Guidance.

Shrestha D, Dhoju D, Shrestha R, Sharma V

Department of Orthopaedic and Traumatology
Dhulikhel Hospital, Kathmandu University Hospital
Dhulikhel, Kavre

Corresponding Author

Dipak Shrestha
Department of Orthopaedic and Traumatology
Dhulikhel Hospital, Kathmandu University Hospital
Dhulikhel, Kavre
E-mail: dsmsortho@gmail.com

Citation

Shrestha D, Dhoju D, Shrestha R, Sharma V. Percutaneous Ilio-Sacral Screw Fixation in Supine Position under Fluoroscopy Guidance. *Kathmandu Univ Med J* 2015;49(1):56-60.

ABSTRACT

Background

Pelvic ring disruption when treated conservatively can be associated with prolonged hospital stay and immobilization, mal-union, chronic pain, limb length discrepancy if they are treated conservatively. Open reduction and fixation in an already compromised soft tissue and hemodynamically unstable patient causes more soft tissue injury, hematoma, infection and neurovascular injury. Percutaneous ilio-sacral joint fixation can be an alternative technique for sacro-iliac joint injury and sacral fracture.

Objective

To evaluate technique and safety of percutaneous ilio-sacral screw fixation in supine position under single fluoroscopy guidance for sacral fracture and sacro-iliac joint disruption.

Method

Twenty one patients either with sacral fracture or sacro-iliac joint disruption with percutaneous ilio-sacral screw fixation with cannulated cancellous screw fixation in between 2008 to 2014 were retrospectively evaluated including AP, inlet and outlet views of pelvis X rays and CT scan. Tile's classification and Dennis classification were used for pelvis and sacral injury.

Result

Thirty five percutaneous ilio-sacral screws were placed (Male: 6, Female: 15; range: 15 to 54) for sacral fracture involving zone 2 (8 with sacral fracture only and 5 with pelvis injury; Tile's type B in four and type C in one) and sacro-iliac joint injury (Tile's type B in three and type C in five). Commonest mode of injury was motor vehicle accidents (10) followed by fall related injury (6). Injury hospital interval and injury surgery interval was five hours to 13 days and 2 to 20 days respectively. Follow period was 3 months to 6 years. One patient developed post-operative deep vein thrombosis and another patient had post-operative haematoma. Two screws were juxtra-foramial. Good to excellent outcome were in 16 patients, fair in four and poor in one patient (Majeed Scoring).

Conclusion

Percutaneous ilio-sacral screw fixation for sacro-iliac joint injury and sacral fracture with C arm guidance is safe and minimally invasive technique. Clear images and accurate interpretation of X-rays, CT scans and per operative C arm images are important to avoid malpositioning of screws and iatrogenic neurovascular injuries.

KEY WORDS

Percutaneous screw fixation, sacral fracture, sacro iliac joint injury

INTRODUCTION

With increasing numbers of high velocity injuries, such as motor vehicle accidents, pelvis and acetabular fractures are also in increasing trend. Pelvic ring disruption carries high morbidity like hemorrhage, mal-union, chronic pain, limb length discrepancy.¹ When they are treated conservatively, prolonged hospital stay and prolonged immobilization are necessary. Secured and anatomical fixation of pelvic ring in unstable pelvis is important but open techniques of reduction and fixation in an already compromised soft tissue and hemodynamically unstable patient can lead to complications such as extensive soft tissue injury, hematoma, infection and increased chances of neurovascular injury.² Delaying surgery for few weeks till patient's and local condition become favorable causes difficult reduction and extensive soft tissue mobilization during surgery. As an alternative, percutaneous technique of ilio-sacral joint fixation can be performed safely for sacro-iliac joint injury and sacral fracture with minimal soft tissue injury, minimal blood loss and less post-operative complications.^{1,3}

Present retrospective study evaluates technique and safety of percutaneous ilio-sacral screw fixation in supine position under single fluoroscopy guidance for sacral fracture and sacro-iliac joint disruption.

METHODS

Among 23 patients either with sacral fracture or sacro-iliac joint disruption who underwent percutaneous ilio-sacral screw fixation with cannulated cancellous screw (CCS) fixation or open reduction and internal fixation with reconstruction plate in between 2008 to 2014 by senior author DS were retrospectively evaluated. Twenty one patients with percutaneous ilio-sacral screw fixation were included as a study group. After initial resuscitation, patient with unstable pelvis injury with sacro-iliac joint disruption or sacral fracture were stabilized with external fixator or upper tibial skeletal traction and attempt of closed reduction was made with skeletal traction. Detail radiographic evaluation of pelvis including antero-posterior, inlet and outlet views of pelvis and CT scan was performed. Classification of pelvis injury was done according to Tile's classification and sacral fracture with Dennis classification. Sacral fracture involving central, middle and posterior sacrum were considered unstable.

Surgical technique

All patients were operated on supine position with radiolucent table. Pelvis was slightly elevated with folded towel under ipsilateral buttock, kept at edge of table. True lateral view of pelvis, inlet, outlet and antero-posterior views were ensured and marked on the C-arm. The position of C-arm on the floor in relation to Operation table was also marked which was helpful in easy and quick access to

views during surgery. True lateral view was ensured when two sciatic notches overlap with each other and end plates of S1 vertebra were also overlapped. Iliac cortical density (ICD) needed to be well defined for secure entry point for ilio-sacral screw fixation. True inlet view was obtained when anterior edge of S1 and S2 overlap and vertebral canal was well defined. Similarly, when superior edge of symphysis pubis overlapped S2, true outlet view was confirmed.(Fig. 1)

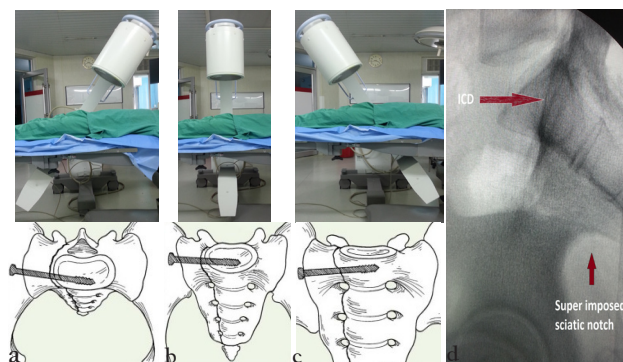


Figure 1. Position of C arm and schematic images of inlet, AP and outlet views (a to c), lateral view showing ICD and overlapped sciatic notch (d)

After draping and part preparation, reduction of sacro-iliac joint or sacral fracture was ensured. Upper tibial skeletal traction was used for longitudinal traction. If required, percutaneously applied ball spiked pelvis clamps on iliac blade was used to get reduction. Entry point for sacral screw was confirmed on lateral view. It should be below and behind ICD. A stab incision was made and 2 mm guide wire was gently tapped into iliac blade at entry point so that it didn't get dislodged during subsequent procedure. C-arm was now rotated to obtain Inlet, outlet and AP view and guide wire was advanced further in such a way that, guide wire was superior to S1 foramen in outlet view, below L5-S1 intervertebral disc space in AP view, within S1 body in inlet view.(Fig. 1) Once positioning of guide wire was ensured in all views and confirmed that it was not extra-osseous or into vertebral canal, required length of screw was measured indirectly. Appropriate length 7 mm cannulated cancellous screw (CCS) was passed under C arm guidance after drilling with 4.5 mm cannulated drill. While passing two screws, simultaneous advancing both screws turn by turn was helpful when they were very near to each other. Partially threaded CCS with washer was used for sacro-iliac joint disruption and fully threaded CCS for sacral fracture. Similar procedure was repeated for contra lateral side when required.

Position of screws were evaluated in post-operative X-rays and CT scan (Fig. 2) and divided into intra-osseous (when cancellous bone are present all around screws in all sections of CT scan), juxtra-foraminal (lack of cortical rim but intact cortex) and extra-osseous (any cortical discontinuity).⁴ Non weight bearing mobilization was started depending upon pain tolerance and associated other injuries.

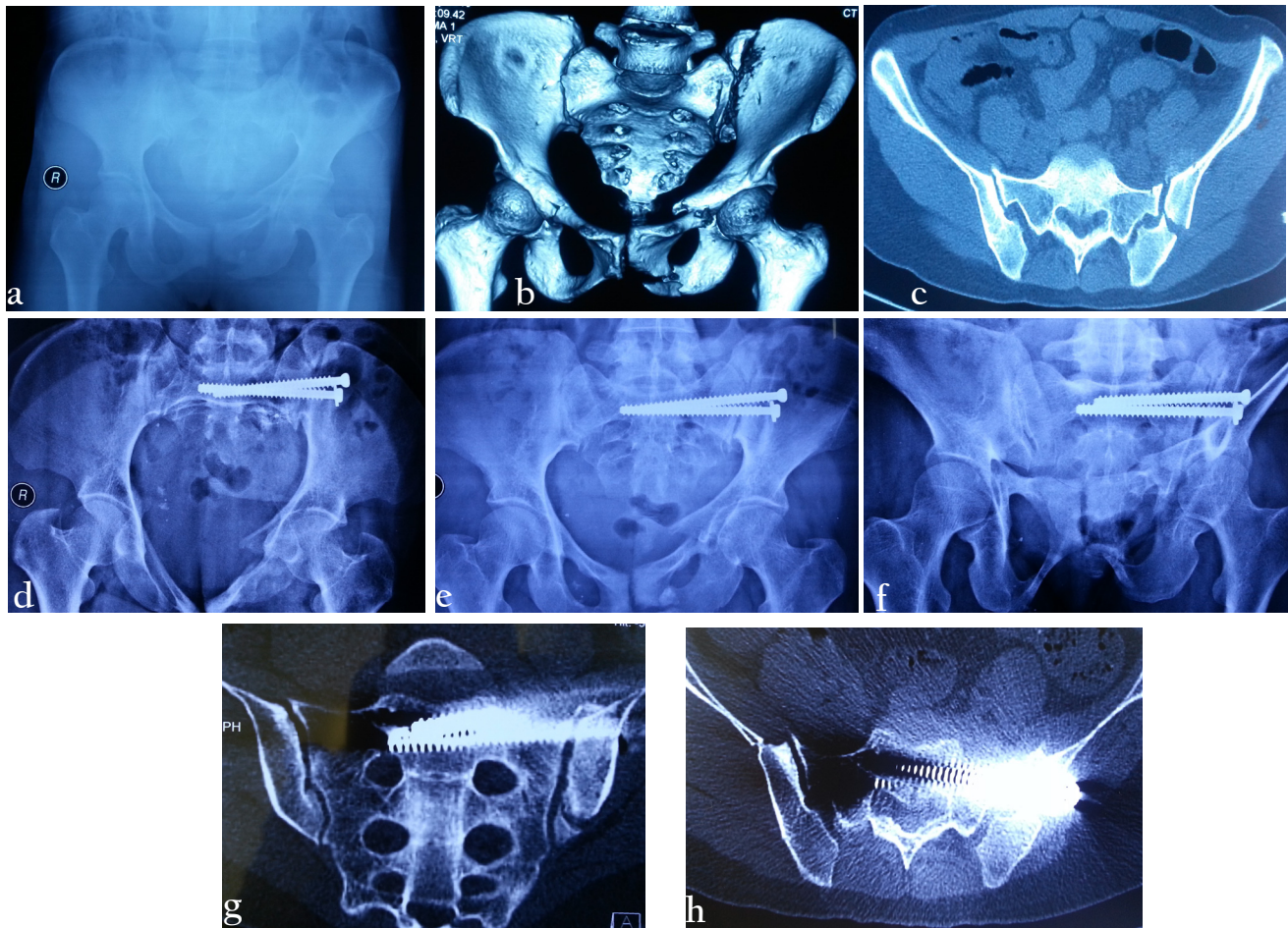


Figure 2. a,b,c: X-ray and CT scan of Tile's type C pelvis injury; d,e,f: fixation with percutaneous ilio-sacral screws (Note: compression was achieved with screw and washer); g,h: CT scan confirmed Intra-osseous placement of screws

Majeed functional scores and clinical grading was used for functional outcome taking in account of pain (30 points), return to work (20 points) sitting (10 points), sexual activity (4 points) and standing (walking aids; 12 points, gait ; 12 points and walking distance; 12 points). Score >85 was considered excellent, 70 to 84 good, 55 to 69 fair and <55 poor.⁵

RESULTS

Total 35 percutaneous ilio-sacral screws were placed in 21 patients (Male: 6, Female: 15; average age: 31.7 years, range: 15 to 54) for sacral fracture involving zone 2 according to Dennis classification (8 with sacrum fracture only and 5 with pelvis injury; Tile's type B in four and type C in one patient) and sacro-iliac joint injury (Tile's type B in three patients and type C in five patients) after closed reduction. Commonest mode of injury was motor vehicle accidents (10) followed by fall related injury (6), landslide injury (4) and physical assault (1). Six patients had concomitant injuries such as fracture humerus (1), distal radius fracture (3), bladder injury (1), and unstable spine fracture (1). Injury hospital interval was five hours to 13 days with

median time of 3 days. Similarly injury surgery interval was from 2 to 20 days. Patients who could not get closed reduction pre operatively with traction or per operatively with manipulation were not considered for percutaneous ilio-sacral fixation. We did not use chemical prophylaxis for deep vein thrombosis unless with concomitant acetabular surgery. One patient developed post-operative deep vein thrombosis and received anti-coagulant therapy. Another patient had post-operative haematoma which needed evacuation. No patient developed post operative infection and neural injury. Out of 35 sacro-ilac screws, two screws were found to be juxtra-foraminal and rest of screws was intra-osseous. A case with bilateral sacral fracture with Tile; C pelvis injury with bladder injury had one side juxtrafoaminal screw and other side intra-osseous. Since screw had not breached the S1 foramen, no revision was required.

Follow period ranged from 3 months to 6 years and during follow up X-rays were evaluated and functional outcome assessment was done. No screw related problems were encountered except few mm back up of one screw in one case. According to Majeed functional outcome, good to excellent were found in 16 patients, fair in four and poor in one patient.

DISCUSSION

Unstable pelvic fracture needs anatomical reduction and internal fixation. Though external fixation can be life saving measure in unstable pelvic fracture, biomechanically it is not rigid enough to produce stable fixation. Early anatomical reduction and stable fixation of unstable pelvis improved patient outcome. Letournel et al. found open reduction and internal fixation with ilio-sacral screw through posterior approach has better outcome for sacro-iliac joint disruption or sacral fracture.⁶ But open techniques are prone to more tissue injury, increased chance of haematoma and post-operative infection. Routt et al in 1993 described technique of ilio-sacral screw fixation which is safe and minimally invasive for soft tissue.⁷ The procedure is not affected by compromised soft tissues and pelvic haematoma and can be performed as early as possible once general condition of patient allows for anesthesia. But learning curve of percutaneous ilio-sacral joint fixation is steep and challenging for orthopedic surgeon. Detail evaluation of X-rays, CT scan and three dimensional understanding of pelvic anatomy and injury pattern is important for safe and secure placement of ilio-sacral screw. In dysmorphic sacrum, inadvertent placement of screw can lead to encroachment of vertebral canal and neurovascular injury.⁸ Finding an entry point, below and posterior to ICD and cranial and anterior to S1 nerve root tunnel on true lateral view of sacrum is important landmark to start per cutaneous sacro-iliac joint fixation besides routine AP, inlet and outlet views. In the present study, no screw malpositions were found because we started all screw placements with ensuring entry point in true lateral view. Juxtra-foraminal screws were found in two screws placement in the present study but they are considered safe if they have not encroached S1 foramen or spinal canal of L5-S1 disc space or sacral ala.

Rate of screw malpositioning with C arm guidance has been reported up to 2-15% and nerve injury up to 0.5-7.7%.^{2,9,10} Some authors have recommended using simultaneous two C arm machines for speedy procedure and less radiation exposure.¹¹ In the current study, we have used only one C arm machine with two monitors in which images can be saved and retrieved immediately. Similarly marking positioning of C arm on the floor in relation to patient bed and marking the angles on C arm to get proper inlet and outlet view are helpful to get accurate views during surgery.

Electrodiagnostic monitoring with somatosensory electric monitoring and motor evoked potential are useful to avoid neural complication but it needs extra arrangement, technical support and expertise.⁴ Even with electrodiagnostic monitoring, false positive alarm and complications have been reported. Ricci WM et al. have reported 4% neurological injury with electromyography monitoring.¹² The present study has not used any electrodiagnostic monitoring and found out that careful study of pre-operative images and adequate attention

to acquire clear fluoroscopic views are helpful to avoid malpositioning of screws. Similar results were reported by Gardner MJ et al. in 106 screws placement in 68 patients who underwent percutaneous sacro-iliac fixation under C arm control without electrodiagnostic monitoring.⁴ They reported 75 intra-osseous and 21 juxtra-foraminal screws. In patients with poorly prepared abdomen with bowel gas, contrast, obesity, electrodiagnostic monitoring is useful. Similarly some authors have recommended CT guided ilio-sacral screw fixation. But it is applicable when reduction has been already achieved and in relatively simple type of injury. But surgery in CT scan room can be difficult when one need to switch to alternative fixation methods such as open techniques or need manipulation for reduction or need other procedures for injuries like bladder or other visceral injury.

Complications in per-cutaneous sacro-iliac joint fixation are related with poor understanding of pelvic osseous anatomy and correlation of various radiographic images in relation to pelvic anatomy. In some case of altered pelvic anatomy and inaccurate reduction, inadvertent screw placement can occur. Injuries related to superior and inferior pubic gluteal vessels and fifth lumbar and first sacral nerve roots have been reported because of technical fault.¹³ No such complications were encountered in the present study.

When per-cutaneous ilio-sacral screw is used for sacro-iliac joint disruption, partially threaded CCS is used to produce lag effect at sacro-iliac joint but not for sacral fractures because it can compress at fracture site causing narrowing of sacral foramina and compression of sacral nerve roots. Fully threaded CCS is used for sacral fracture. To achieve adequate stability, screw can be crossed midline into sacral body.¹³

Accurate reduction of sacro-iliac joint is difficult when injuries are old because fracture haematoma already starts consolidation.¹⁴ Upper tibial or distal femoral skeletal traction or external fixator can be used to achieve reduction once reduction is achieved, ilio-sacral joint can be fixed. In the present study, some patients were operated late but reduction was achieved with skeletal traction within a week. In cases where reduction was not satisfactory with traction, per-operative measures such as traction under general anesthesia and direct manipulation of iliac blade with pelvis reduction clamp or Schanz pin was performed.

Number of one or two screw was decided by the purchase obtained with initial screw. When purchase was not sufficient, second screw was inserted in such a way that it threads lock with first screw.¹³ Percutaneous ilio-sacral screw can be placed both in patient in prone or supine position. In our study, all patients were operated in supine position. Advantages of supine position are better orientation of pelvic anatomy for surgeons. If patient require reduction measures like traction, manipulation with reduction clamp, patient in supine position is more

comfortable. If patient require assess to abdomen, it is not possible in prone position. Minimal invasive nature of this surgery is responsible for low rate of infection. Routt ML et al. reported no infection in 177 patients with percutaneous sacro-iliac joint fixation. Similarly we also have no patients with infection where as Keating et al. have reported 7.5% of infection in open technique of ilio-sacral screw fixation.¹⁵

CONCLUSION

REFERENCES

1. Shuler TE, Boone DC, Gruen GS, Peitzman AB. Percutaneous iliosacral screw fixation: Early treatment for unstable posterior pelvic ring disruptions. *J Trauma* 1995;38:453-8.
2. van den Bosch EW, van Zwiene CM, van Vugt AB. Fluoroscopic positioning of sacroiliac screws in 88 patients. *J Trauma*. 2002;53:44-8.
3. Routt ML Jr, Kregor PJ, Simonian PT, Mayo KA. Early results of percutaneous iliosacral screws placed with the patient in the supine position. *J Orthop Trauma*. 1995;9:207-14.
4. Gardner MJ, Farrell ED, Nork SE, Segina DN, Routt, ML. Percutaneous Placement of Iliosacral Screws Without Electrodiagnostic monitoring. *The Journal of Trauma: Injury, Infection, and Critical Care* 2009;66(5): 1411-5.
5. Majeed SA. Grading the outcome of pelvic fractures. *J Bone Joint Surg Br* 1989;71:304-6.
6. Letournel E. Pelvic fractures. *Injury*. 1978;10:145-8
7. Routt ML, Meier M, Kregor PK: Percutaneous iliosacral screws with the patient supine technique. *Op Tech Orthop* 1993;3:35-45.
8. Miller AN, Routt ML Jr. Variations in Sacral Morphology and Implications for Iliosacral Screw Fixation. *Journal of American Academy of Orthopaedic Surgeon* 2012;20(1): 8-16.
9. Hinsche AF, Giannoudis PV, Smith RM. Fluoroscopy-based multiplanar image guidance for insertion of sacroiliac screws. *Clin Orthop Relat Res*. 2002;395:135-44
10. Templeman D, Schmidt A, Freese J, Weisman I. Proximity of iliosacral screws to neurovascular structures after internal fixation. *Clin Orthop Relat Res*. 1996;329:194-8.
11. Peng KT, Huang KC, Chen MC, Li YY, Hsu RWW. Percutaneous Placement of Iliosacral Screws for Unstable Pelvic Ring Injuries: Comparison between One and Two C-arm Fluoroscopic Techniques. *The Journal of Trauma: Injury, Infection, and Critical Care*. 2006;60(3): 602-8.
12. Ricci WM, Padberg AM, Borrelli J. The significance of anode location for stimulus-evoked electromyography during iliosacral screw placement. *J Orthop Trauma*. 2003;17:95-9.
13. Routt ML Jr, Simonian PT, Mills WJ. Iliosacral screw fixation: early complications of the percutaneous technique. *J Orthop Trauma*. 1997;11:584-9
14. Routt ML Jr, Nork SE, Mills WJ. Percutaneous fixation of pelvic ring disruptions. *Clin Orthop Relat Res*. 2000;375:15-29
15. Keating J, Blachut P, O'Brien P, Meek R, Broekhuysen H. Vertically unstable pelvic fractures-the outcomes of iliosacral screw fixation of the posterior lesion. Paper presented at the Annual Meeting of the Orthopaedic Trauma Association, 1994.

Percutaneous ilio-sacral screw fixation for sacro-iliac joint injury and sacral fracture with C arm guidance is safe and minimally invasive technique. Clear images and accurate interpretation of X-rays, CT scans and per operative C arm images are important to avoid possible complications such as malpositioning of screws and iatrogenic neurovascular injuries.