

Esthetics in Removable Partial Denture - A Review

Shah R, Aras M

Department Prosthodontics

Goa Dental College and Hospital

Bambolim, Goa- India

Corresponding Author

Ronak Shah

Department Prosthodontics

Goa Dental College and Hospital

Bambolim, Goa, India

Email: rmshah1in@yahoo.co.in

ABSTRACT

Removable partial denture is a repulsive modality of treatment that we still must rely upon for certain cases and is a part of the practice. But these patients expect it to look as esthetic as any other contemporary modality of treatment. This article thus focuses on the esthetic aspects that a clinician must place emphasis upon during the designing and fabrication of prosthesis to provide the desirable outcome.

KEY WORDS

Clasps, connectors, designing of RPD, esthetics, flanges

Citation

Shah R, Aras M. Esthetics in Removable Partial Denture - A Review. *Kathmandu Univ Med J* 2013;44(4):344-348.

INTRODUCTION

Denture esthetics as defined by Glossary of prosthodontics terms is the effect produced by the prosthesis that affects the beauty and attractiveness of the person. When planning treatment for partially edentulous patients, both masticatory function and esthetics should be taken into consideration. An esthetic prosthesis will improve patient motivation and acceptance. It is very unrealistic to assume that because acceptable masticatory capability has been achieved, patients will tolerate a poor appearance of the prosthesis.¹

Recently, Implants have gained the attention over removable prosthesis as a treatment option in partially edentulous conditions too. However sometimes financial, anatomic, psychological, or medical considerations of the patients still require the dentist to treat them with removable prosthesis.

This article focuses on the esthetic considerations during various phases of removable partial denture planning and fabrication that should be kept in mind by the clinician and can aid him/her in achieving an excellent esthetic outcome

as far as the patient's realistic expectations are concerned. The various phases of providing an esthetic removable partial denture will include the following: diagnosis and treatment planning, surveying, mouth preparation, framework design, prosthetic teeth and denture base resin and flanges.

Diagnosis And Treatment Planning

Esthetic considerations and assessment should begin with the entry of the patient into the dental office. A good clinician should have excellent observation and listening skills so that he/she can interpret them well and arrive at an accurate diagnosis.

Decisions regarding types of retaining components, thickness of flange, placement of artificial teeth, etc. must be made with the final esthetic result in mind at this stage. Factors like undercuts, diastemas, reduced ridge space should also be paid attention to. The length and mobility of the patient's lips are also important. Patients with short lips or highly mobile lips pose problems as esthetics are

compromised because most clasp arms, denture borders and other components will show when the patient smiles or speaks.

Various factors including the attitude of patient, his perception of esthetics and the status he/she holds in the society must be kept in mind while planning a removable prosthesis. Quite often, a patient who is dissatisfied with the esthetic appeal of his prosthesis complains of inability to wear it although it is functionally good. A good esthetic result thus can motivate the patient to wear his new denture.

The patient's cosmetic index also can provide valuable information and thus should be evaluated to know patient's expectations towards the final results.

Surveying

It is essential to determine a path of insertion or dislodgment that is well consistent with the esthetic requirements. The dental surveyor is the fundamental instrument of RPD design and treatment planning and hence its use will optimize the desired esthetics of the final prosthesis. Surveying permits the location of clasp arms and arrangement of prosthetic artificial teeth to derive maximum esthetics.

Esthetic consideration does not ordinarily justify the alteration of the path of insertion at the expense of other fundamental factors. But, whenever given a choice between two paths of insertion with all other factors remaining unaffected, the path of insertion that enhances the esthetic outcome should be given a preference. In cases of anterior tooth replacement, esthetics must be given a primary consideration, even at the expense of altering the path of placement and making all other factors conform.²

To obtain optimum esthetics—firstly the metallic components must be concealed as much as possible by ensuring that the retentive clasp arm is placed in the gingival third of a clinical crown. And secondly, the artificial anterior teeth should be placed in the most natural position possible. Often large undercuts are present, adjacent to teeth bordering the anterior edentulous span. They can be eliminated or decreased in size by altering the tilt of the cast or by selective grinding of the proximal surfaces.³(Fig 1)

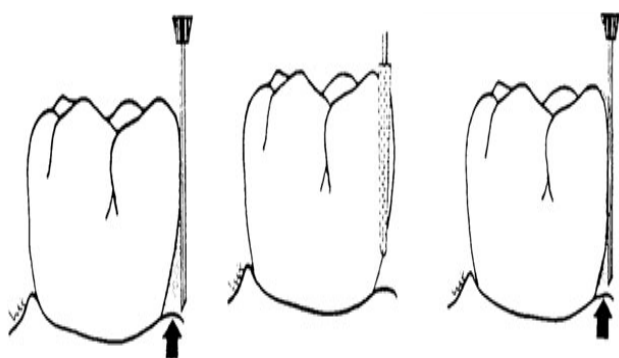


Figure 1. Making the Undercut Favourable for Retention.

Mouth Preparation

After surveying of the diagnostic cast and formulating appropriate treatment plan, the next important step is mouth preparation.

Alignments of the proximal tooth surfaces in anterior edentulous spaces often lack parallelism, are bell shaped, tipped, or rotated and may be marked for recontour with the dental surveyor.⁴ The height of contour of proximal tooth surface, that are to be used as the guiding planes may be lowered to permit the rigid portions of the clasp to be placed closer to the gingival margin of the tooth, resulting in a clasp design that is considerably less visible.

Surgical reduction of the frenum attached close to the ridge should be carried out to control the depth of notches in the denture flange to improve fit and esthetics of the prosthesis. So the clinician should wisely plan out all mouth preparations needed before heading for the further procedure.

Designing of RPD

Designing for an RPD should be such that all its components are as inconspicuous as possible to further enhance esthetics. Extra-coronal direct retainers are not pleasing for patients concerned about esthetics. Clasps are the only components which are placed on visible surfaces of the teeth. Following are the esthetic alternatives to conventional clasps to eliminate visible display of metal and improve esthetics.

Equipoise system: It is an esthetic retentive concept for distal extension situations. Rests are placed away from edentulous span. Vertical interproximal reduction of 1mm between abutment and adjacent tooth is carried out. It is a lingual back action clasp that is fully reciprocated and extremely esthetic with no facial clasp display⁵ (Fig2)

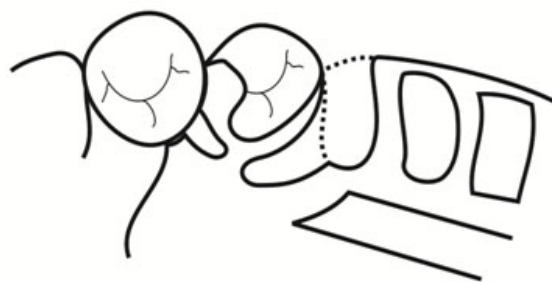


Figure 2. Equipoise clasp design.

Spring clasp/ twin clasp: It consists of a wire clasp soldered into a channel that is cast in the major connector. As this clasp is flexible, it does not generate as much torque when the distal extension denture base is under occlusal load. The ability to adjust this clasp and its conventional path of insertion provides an excellent design option for retention to an adjacent edentulous segment.⁶ (Fig3)

Saddle lock clasp: Also called as Hidden clasp. It uses the more pronounced mesial/ distal concave surfaces of the




Figure 3. Twin Flex Clasp Design.

abutment adjacent to the denture saddle. Clasp terminals are positioned at each end of the denture saddle, effectively locking the segment onto the ridge.⁷ (Fig 4)

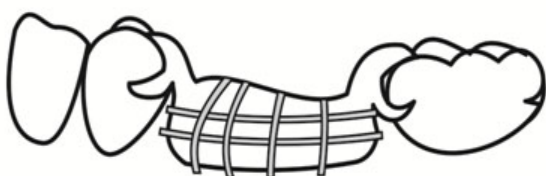

Figure 4. Saddle Lock Clasp Design.

Round-rest distal depression clasp: A round-rest, distal depression clasp is suggested as an esthetic alternative to a conventional clasp for maxillary anterior teeth serving as abutments for a removable partial denture. A lingual round rest provides support for the prosthesis, and a mesiolingual reciprocating plate is present. A split minor connector engages a distal depression for retention. The facial surface of the abutment displays no metal and provides an esthetic result.⁸ (Fig5)

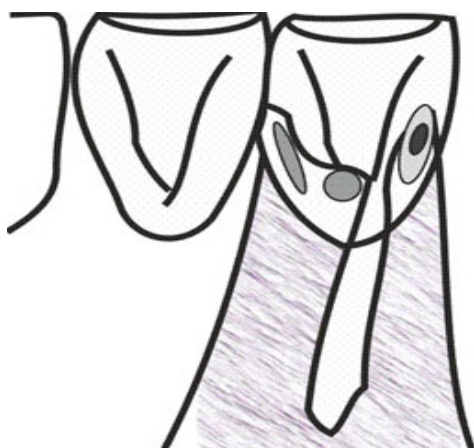


Figure 5. Round Rest Distal Depression Clasp Design.

Metal free clasps: The metal free materials available currently eg. Acetyl resin, flexible thermoplastic materials are ideal for flexibility and esthetics, thus allowing esthetic functional care in true sense. These may be combined with metal framework to provide esthetics. Masking of clasps with resins/composites by macro/micromechanical retention is another way of improving esthetics. (Fig 6)

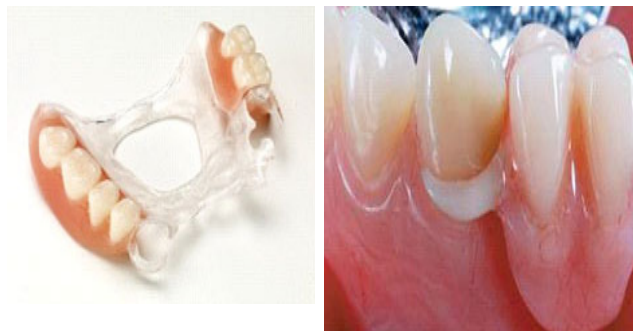

Figure 6. Metal Free Clasps. (E.g. DurAcetal clasps, ClearFrame Clasps)

Rests

Use of inconspicuous rests further improves the esthetics of the removable partial denture. The clinician should try to restore the anatomy of the tooth as it existed before the rest seat preparation and minute anatomical observations should be inculcated in the framework design.

The cingulum or lingual rest provides the best combination of function and esthetics. They are more acceptable than incisal rests because they can be hidden from view, create less leverage on the abutment teeth by loading at a more apical level and are less bothersome to the tongue.^{9,10} In cases where incisal rests are to be used, the patient should be made very well aware of its esthetic impact. Occlusal rests on posterior teeth are quite inconspicuous and hence poses no major problem. Occlusal surface of a rest should be concave rather than convex so that its shape follows the normal occlusal contour of the abutment tooth.¹¹ (Fig 7)

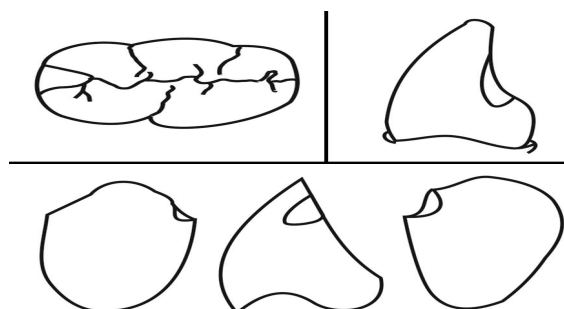


Figure 7. Types of Rests.

Major Connector

An appropriate major connector design also aids in esthetic RPD especially in the mandibular arch when there are abnormally large interproximal spaces present between the teeth. The lingual bar is a suitable major connector in the presence of diastemas, but only if the distance from free gingival margin to the floor of the mouth permits its use. In cases where the distance is insufficient, interrupted linguoplate major connector (with step back design) should be used in the presence of diastemas to avoid the display of metal. (Fig 8)

Minor Connector

Proper location and contour of minor connectors can contribute to the appearance of the removable partial

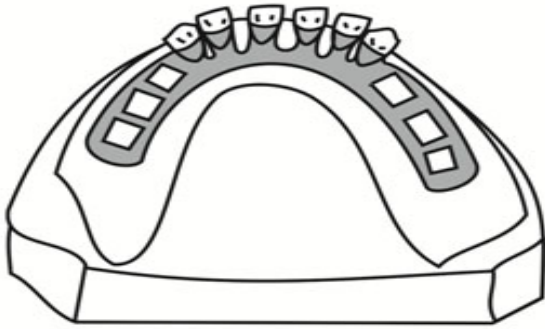


Figure 8. Step back design in case of spacing.

denture as well. Minor connectors should be kept thin mesiodistally to avoid interference with placement of the prosthetic teeth, adapted closely to the clasp to maximize esthetics and should be placed as far lingually as possible to minimize the show of metal in the finished prosthesis.^{12,13}

Prosthetic Teeth

The prosthetic teeth are an important component of the removable partial denture from a stand point of esthetics, function and phonetics.¹⁴ Matching the anterior denture teeth with natural teeth requires proper attention to shade control, characterization and contours of the denture teeth to harmonize them with the natural teeth and correct denture teeth positioning.¹⁵ The patient's natural teeth or current/old prosthesis acts as a valuable guide for selection and arrangement of teeth in the new prosthesis.

Anterior edentulous spaces usually become smaller than the combined widths of the natural teeth being replaced.¹⁶ Esthetics in such case may be accommodated - by making the prosthetic teeth slightly smaller or by grinding the adjoining natural teeth to create additional space or by subtle rotation of prosthetic tooth contacts to the facial or lingual.¹⁷ It is also essential to evaluate the patient's smile line and the amount of tooth-papilla display during a smile in order to determine the tooth mold selection and positioning.

Gingival configuration is another important factor that should be kept in mind while fabricating the prosthesis. The location and contour of the gingival margins created on the denture teeth and length of interdental papillae should carefully match those of the adjacent natural teeth. McGivney et al suggested that prosthetic teeth be uncovered fully to expose the entire anatomic crown and beyond when gingival recession is to be simulated, using adjacent or contralateral tooth gingival relationship as a guide.¹⁸

Further, shade selection plays a vital role in the esthetic enhancement of the prosthesis. The dental clinic should have definite shade guides according to Hue, Value and Chroma gradations that will assist the clinician in selecting the appropriate tooth mold. This problem is very unique in removable partial prosthodontics compared to that in complete denture or fixed partial prosthodontics. This is

because a slight change in the translucency and colour of the shade guide and complete denture teeth is not easily discernible either to the dentist or the patient while fixed prosthodontics offers the advantage of custom staining of porcelain teeth to the harmony of the adjacent natural teeth.

Shade selection for the posterior teeth presents an additional challenge to overcome. No manufacturer provides the dental office with a posterior shade guide; moreover the majority of posterior acrylic resin teeth are not being manufactured with the gingival and occlusal blending as is done for the anterior teeth. The easiest way out of this dilemma for the dentist is to make a custom posterior shade guide.¹⁹

Denture Base Resin And Flanges

The component quite often overlooked in the RPD design is the denture base portion of a partial denture. The labial flange is a significant part, most important when restoring missing anterior teeth. This decision whether or not to incorporate it into the denture should be evaluated carefully. When considerable bone loss is evident, it is wise to incorporate a labial flange to restore the lost tissue contour and at the same time acquire proper lip support thereby also avoiding the placement of teeth more palatally to contact the ridge.

Flange design: Anterior flanges ideally should extend to the reflection of the mucosa in the labial sulcus to avoid the horizontal edge of the flange being visible. Since the flange should replace the lost alveolar tissue, it should be no thicker than is necessary. The lateral border of the flange can be extended onto the adjacent root eminence, tapering the flange at that point almost to a knife's edge. The thin resin is almost transparent and allows the color of the mucosa to show through. In addition, the coverage of the papilla immediately mesial to the abutment tooth avoids the dark shadow often created by a vertical edge of a flange in this region.²⁰

CONCLUSION

In the current scenario the removable partial denture not only aims towards the restoration of function and phonetics but should also have special emphasis on esthetics with long term benefits which requires meticulous attention during fabrication. This article discusses several simple tips and techniques for providing a highly esthetic removable partial denture that a clinician can use and prescribe it to the laboratory while designing and fabricating it.

REFERENCES

1. Andiará De Rossi, Rubens Ferreira Albuquerque Junior, Osvaldo Luiz Bezzon. Esthetic options for the fabrication of removable partial dentures: A clinical report. *J Prosthet Dent.* 2001; 86:465-467.

2. Beaumont AJ Jr. An overview of esthetics with removable partial dentures. *Quintessence Int.* 2002 Nov-Dec; 33(10):747-755.
3. Kenneth L. Stewart, Kenneth D. Rudd, William A. Kuebker. Clinical removable partial prosthodontics. 2nd ed. St Louis: Mosby; 1983. Pg 237.
4. Grasso JE, Miller EL. Removable Partial Prosthodontics. 2nd ed. Baltimore: Williams and Wilkins; 1981. Pg 110.
5. Reagen SE, Rold TM. Practical esthetic options for retention of removable partial dentures: a case report. *Quintessence Int.* 1996; 27(5):333-340.
6. Belles DM. The twin flex clasp: an esthetic alternative. *J Prosthet dent.* 1997; 77: 450-452.
7. M. A. Aras, V. Chitre. Direct retainers: aesthetic solutions in smile zone. *J Indian Prosthodont Soc.* 2005 Mar; 5 (1): 4-9.
8. Chi Tran, Eugene LaBarre, Howard M.Landesman. A removable partial denture using an esthetically designed round-rest distal clasp on maxillary anterior abutment teeth: A clinical report. *J Prosthet Dent* 2009; 102:286-289.
9. McGivney GP, Carr AB, McCracken WL. McCracken's Removable Partial Prosthodontics, 10th ed. St. Louis: Elsevier Mosby; 2000. Pg 88.
10. Stratton RJ, Wiebelt FJ. An atlas of removable partial denture design. Chicago, Illinois: Quintessence Publishing Co; 1988. Pg 88.
11. Renner RP, Boucher LJ. Removable Partial Dentures. Chicago, Quintessence Publishing Co; 1987. Pg 59.
12. Grasso JE, Miller EL. Removable Partial Prosthodontics. 2nd ed. Baltimore: Williams and Wilkins; 1981. Pg 195.
13. Stratton RJ, Wiebelt FJ. An atlas of removable partial denture design. Chicago, Illinois: Quintessence Publishing Co;1988. Pg 27.
14. Grasso JE, Miller EL. Removable Partial Prosthodontics, 2nd ed, Baltimore: Williams and Wilkins; 1981. Pg 235.
15. Renner RP, Boucher LJ. Removable Partial Dentures. Chicago, Quintessence Publishing Co; 1987. Pg 335.
16. Applegate O.C. Essentials of Removable Partial Denture. Prosthesis. 3rd ed. Philadelphia: Saunders; 1965. Pg 249.
17. Grasso JE, Miller EL. Removable Partial Prosthodontics. 2nd ed. Baltimore: Williams and Wilkins; 1981. Pg 240.
18. McGivney GP, Carr AB, McCracken WL. McCracken's Removable Partial Prosthodontics. 10th ed. St. Louis: Elsevier Mosby; 2000. Pg 412.
19. Sykora O. Fabrication of a posterior shade guide for removable partial denture. *J Prosthet Dent* 1983; 50 287-288.
20. Smith BJ. Esthetic factors in removable partial prosthodontics. *Dent Clin North Am.* 1979 Jan; 23(1):53-63.