

Incontinentia Pigmenti

BS G,¹ Pai GS,¹ Pai AH,¹ Vinekar AS,² Pai HS,³ Noronha T,¹ Fernandes MS¹

¹Department of Dermatology

K.S.Hegde Medical Academy

Deralakatte, Mangalore

²Pediatric Vitreoretina service

Narayana Nethralaya, Bangalore

³Alpha Eye centre, Mangalore

India

Corresponding Author

Girisha B.S

Department of Dermatology

K.S.Hegde Medical Academy

Deralakatte, Mangalore

India

Email: drgirishbs@gmail.com

Citation

BS G, Pai GS, Pai AH, Vinekar AS, Pai HS, Noronha T et.al. Incontinentia Pigmenti. *Kathmandu Univ Med J* 2013;41(1):91-93.

INTRODUCTION

Incontinentia Pigmenti(IP) also called Bloch-Sulzberger syndrome is a rare X-linked dominant genodermatosis affecting mostly female patients and is usually lethal to male fetus in utero. The gene affected is NEMO or IKK gamma gene located on Xq28. It is a multisystem disorder which can affect skin, teeth, eyes and central nervous system. The skin lesions can be accompanied by ocular, dental and neurological manifestations.^{1,2}

CASE REPORT

A 30-day-old baby girl delivered at term of a non consanguineous marriage by a caesarian section was brought to our hospital with skin eruptions all over the body since birth. The indication for caesarian section was a previous caesarian section. The weight of the baby at birth was 3200gms. She had fluid filled lesions on the left arm at birth, which progressed to involve the left forearm, right

arm, right forearm, trunk, lower legs and back subsequently within a few days as noted by her mother. These fluid filled lesions would flatten after a few days without rupturing and would crust. She had also noticed hyperpigmented linear streaks over the abdomen from birth. There were no history of any episodes of seizures, feeding difficulties or delay in milestones. Family history is unremarkable. Her four year old sibling was not affected. Mother had regular antenatal checkups. There was no history of any miscarriage. On examination of skin, hyperpigmented verrucous plaques were arranged linearly over the upper and lower extremities (Fig1 and 2). A few vesicles were present over the upper limb and back. Reticulate hyperpigmentation was present over bilateral thighs. A few tense bullae were present over the soles (Fig 2). Face was spared. Whorled pattern of hyperpigmentation was present over the abdomen (Fig 3). Scalp, hair, nails and oral mucosa were normal. Systemic examination was within

ABSTRACT

Incontinentia pigmenti is an X- linked dominant condition characterized by cutaneous lesions associated with developmental defects of the eye, skeletal system and central nervous system. We report a case of incontinentia pigmenti in a 30 day old female infant who presented to us with skin eruptions over bilateral upper limbs, lower limbs and trunk since birth. She had linear verrucous plaques and vesicles distributed along the Blaschko's lines in addition to macular hyperpigmentation in a linear and whorled pattern involving the concerned areas. On ophthalmological examination, proliferative retinopathy in the right eye was noted.

KEY WORDS

Incontinentia pigmenti, proliferative vitreoretinopathy

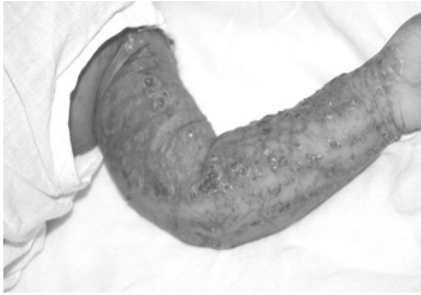


Figure 1. Multiple vesicles, crusted erosions and streaks of hyperpigmentation seen over the left arm and forearm.

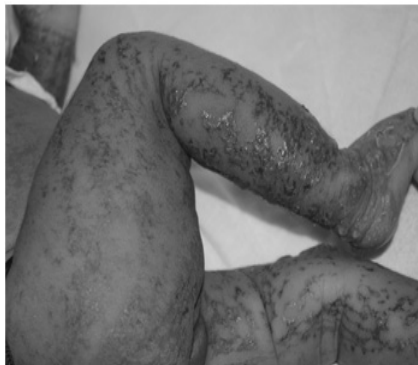

Figure 2. Multiple vesicles, a few pustules and areas of reticulate and linear hyperpigmentation over bilateral lower limbs.

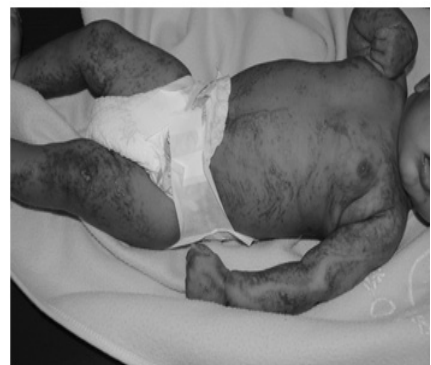

Figure 3. Whorls of hyperpigmentation along the lines of Blaschko on the abdomen and verrucous papules over the thighs.

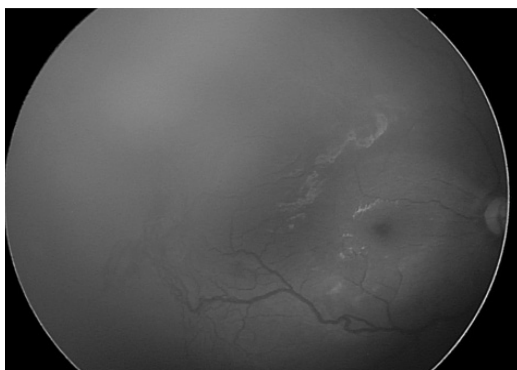


Figure 4. Fundus examination reveals neovascularization at the retinal periphery.

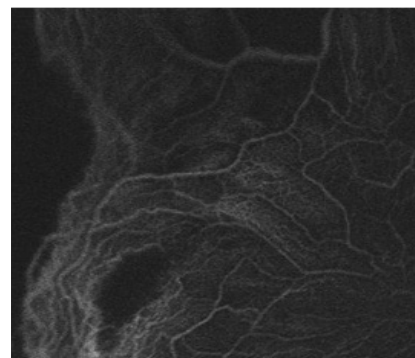


Figure 5. On fundus fluorescein angiography of the same reveals avascular retina with neovascularization at the retinal periphery.

normal limits: central nervous, respiratory, per abdomen and cardiovascular systems were normal. Ophthalmological examination showed proliferative vitreoretinopathy of the right eye (Fig 4 and 5). Routine blood investigations were within normal limits. Biopsy of a vesicle showed spongiosis with numerous eosinophils in the epidermis with a few dyskeratotic cells. Patient was referred to higher centre for further evaluation and treatment of her retinal problem, where she underwent laser photo coagulation.

DISCUSSION

Incontinentia pigmenti is a genodermatosis that can affect skin, teeth, eyes and central nervous system. It has an X-linked dominant inheritance. Clinical manifestations vary from subtle dental and cutaneous findings to severe ophthalmological and neurological involvement. Cutaneous involvement is present in nearly all the cases and is often the first sign.¹ Cutaneous features are divided in to four stages. They are vesiculobullous stage, verrucous stage, stage of pigmentation and stage of atrophy. These stages can classically evolve in succession or may occur concurrently.^{1,3}

Our patient had overlapping features of vesiculobullous stage, verrucous stage and stage of pigmentation when presenting to us. She did not have any family history of any skin and dental disorders. On her routine ocular

examination proliferative vitreous retinopathy was detected. No neurological deficits were observed.

Ocular manifestations are seen in 25-77% patients with IP.¹ They account for severe manifestations of IP and are often associated with neurological deficits. Ocular anomalies in IP can be subdivided into retinal and nonretinal manifestations. The characteristic retinal manifestation of IP is proliferative retinopathy that consists of peripheral retinal vascular nonperfusion, preretinal neovascularisation, preretinal or vitreous hemorrhage and infantile tractional retinal detachment.^{1,4} Demonstrable retinal lesions may occur from neonatal period up to one year of age. The nonretinal manifestations include strabismus, crossed eyes, optic nerve atrophy, conjunctival pigmentation, iris hypoplasia, nystagmus and uveitis.¹

Prognosis for normal vision is considered good if there is no evidence of retinal lesions in first year of life. However the course of established lesions is unpredictable. It ranges from slow progression over many years to rapid deterioration and blindness.¹ Hence ophthalmic examination should form an integral part of routine examination of patients with IP. Abnormalities if detected in the neonatal period can be promptly treated and blindness can be prevented. In our patient the proliferative vitreoretinopathy of the right eye was detected at a very early stage and was referred to a tertiary eye care centre where it was treated

by laser photocoagulation. She is also on regular follow up to recognise progression of her retinal lesions as well as neurological deficits. Early detection and treatment of retinal lesions in incontinentia pigmenti can preserve vision.

REFERENCES

1. Berlin AL, Paller AS, Chan LS .Incontinentia pigmenti: A review and update on the molecular basis of pathophysiology. *J Am Acad Dermatol* 2002;47:169-87.
2. Rabia HS, Rimella A, Smahi A, Fraitag S, Teillac DH, Bonnefont JP et al. Clinical and histologic features of incontinentia pigmenti in adults with nuclear factor-kB essential modulator gene mutations. *J Am Acad Dermatol* 2011;64:508-15.
3. Basarab T, Dunnill M.G.S, Munn S.E, Russel-Jones R. Incontinenti pigmenti: variable disease expression within the affected family. *JEADV* 1998;11:173-176.
4. Sanghi G, Dogra MR, Ray M, Gupta A. Predominant exudative retinopathy in incontinentia pigmenti and clinical course after peripheral laser photocoagulation. *Indian J Ophthalmol* 2011;59(3):255-6.