

Anterior Neck Lipoma with Anterior Mediastinal Extention – A Rare Case Report

Sharma BK,¹ Khanna SK,¹ Bharati M,¹ Gupta A²

¹Department Of Radiodiagnosis

²Department Of Pathology

Sikkim Manipal Institute of Medical sciences

Central Referral Hospital (CRH), Medical council of India affiliated

5th Mile, Tadong, Gangtok

Sikkim, India

Corresponding Author

Barun Kumar Sharma

Department Of Radiodiagnosis

Sikkim Manipal Institute of Medical sciences

Central Referral Hospital (CRH), Medical council of India affiliated

5th Mile, Tadong, Gangtok

Sikkim, India

Email: drbarun2003@yahoo.com

Citation

Sharma BK, Khanna SK, Bharati M, Gupta A. Anterior Neck Lipoma with Anterior Mediastinal Extention – A Rare Case Report. *Kathmandu Univ Med J* 2013;41(1):88-90.

INTRODUCTION

Lipomas are the most common benign mesenchymal tumour. Thirteen percent of lipomas are seen in head and neck region. Anterior neck lipoma is a rare one. Anterior neck lipoma with mediastinal extension is extremely rare. Ultrasonography acts as the initial imaging modality in diagnosis of head and neck lipoma. Sonographic appearance of head and neck lipomas are characteristic. Fine needle aspiration cytology (FNAC) or computed tomography (CT) is indicated for confirmation of diagnosis. Surgical intervention is challenging and should be reserved for patients with cosmetics and pressure effects. We reported a case of 52 years old male patient with left anterior neck lipoma extending in to the anterior mediastinum.

ABSTRACT

Lipomas are the most common benign mesenchymal tumour. Thirteen percent of lipomas are seen in head and neck region. Anterior neck lipoma is a rare one. Anterior neck lipoma with mediastinal extension is extremely rare. We are presenting a case of 52 years old male reported to Central Referral Hospital, Sikkim Manipal Institute of Medical Sciences, Gangtok, Sikkim with complains of swelling in left side of neck for last 18 months along with occasional history of dyspnoea. Physical examination, ultrasound, computed tomography and fine needle aspiration cytology are in favor of lipoma. Due to its location up to the anterior mediastinum, the surgery could not be done in this hospital and patient was referred to higher center having cardio-thoracic surgical back up.

KEY WORDS

Anterior neck lipoma, anterior neck swelling, lipoma

CASE REPORT

Fifty two years old male reported to Central Referral Hospital, Sikkim Manipal Institute of Medical Sciences, Gangtok, Sikkim with complains of swelling in left side of neck for last 18 months along with occasional history of dyspnoea. After taking consent, physical examination was carried out which showed soft compressible mass in left anterior lower neck region, adjacent to thyroid gland. Though swelling appeared like goiter but found to be soft and compressible. Ultrasound was done which showed a well defined echogenic elliptical shaped mass lesion measuring 3.2cm in AP dimension, having multiple internal linear echoes with surrounding hypoechoic outline (Fig 1A). On colour doppler study, no internal vascularity noted within the mass (Fig 1B). The mass is causing compression on the left lobe of thyroid gland. The lower pole of the mass

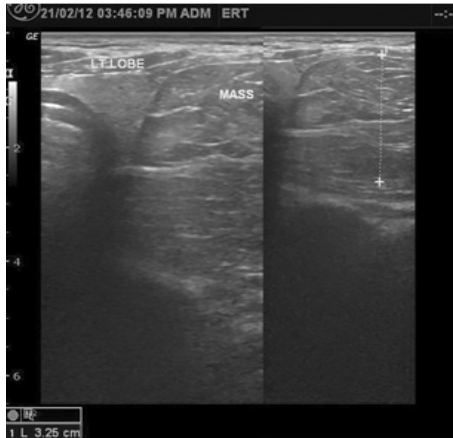


Figure 1A. Ultrasound image showing lipoma causing compression on left lobe of thyroid gland.

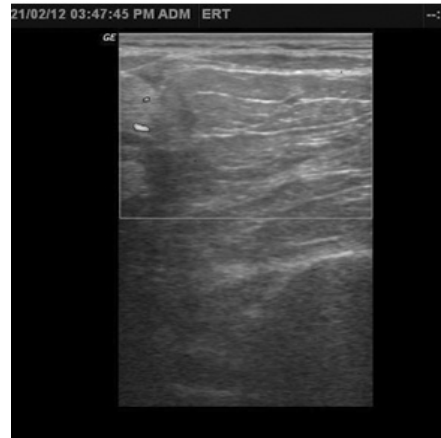

Figure 1B. Color doppler image of lipoma showing no internal vascularity. Vascularity is seen in left lobe of thyroid gland.

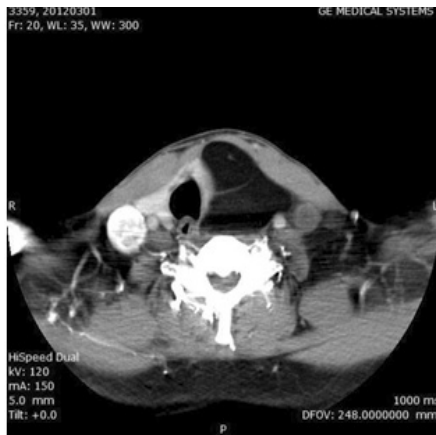

Figure 2A. CECT neck showing left anterior neck lipoma.

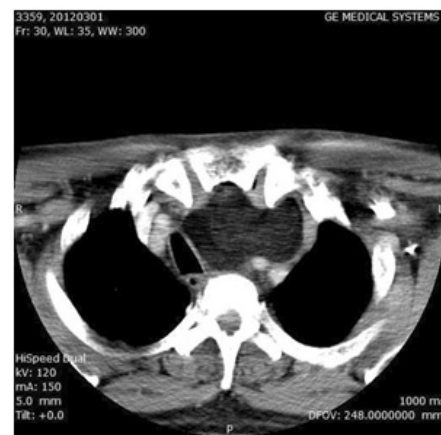

Figure 2B. CECT mediastinum showing extension in retro-sternal space.

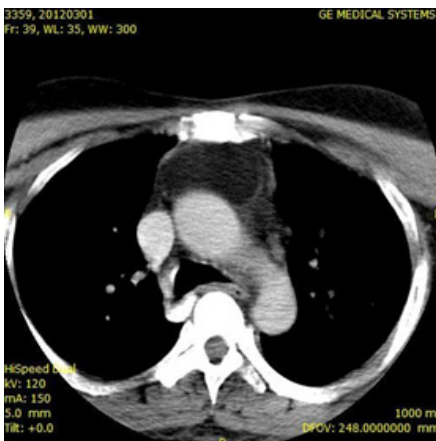


Figure 2C. CECT mediastinum showing lower extension up to the anterior mediastinum.

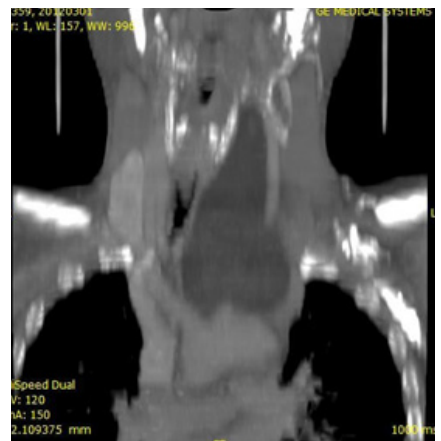


Figure 2D. Coronal reconstruction of CT showing left anterior neck lipoma extending up to the mediastinum.

could not be defined as it is extending into the thoracic inlet. Sonographic features of the mass lesion were consistent with lipoma. On contrast enhanced computed tomography (CECT), a well defined non-enhancing fat density (-85 to -95 hounsfield units) mass measuring 16cmx7.3cmx5.5cm with few internal fibrous septations suggesting lipoma noted in left anterior triangle compressing the left lobe of thyroid (Fig 2A). The trachea is compressed and displaced towards right side along with the esophagus (Fig 2B). Lipoma is displacing adjacent neck vessels and showing lower extension up to the anterior mediastinum (Fig 2C).

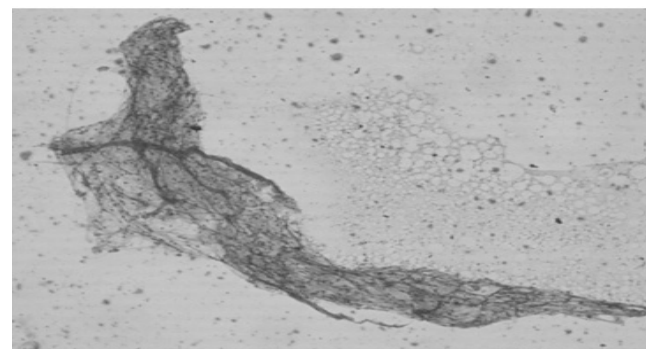


Figure 3. Fine needle aspiration cytology showing lipoma.

Fine needle aspiration cytology showed clusters of mature adipocytes and fibrous stromal fragments suggestive of lipoma (Fig 3). Surgical intervention is challenging in this case because of complicated neck anatomy and because of anterior mediastinal extension of lipoma. As the recurrence rate is high if the complete removal is not carried out. The case was referred to the higher center having cardiothoracic surgical back-up so that complete removal of the lipoma could be possible.

DISCUSSION

Lipoma is a most common benign mesenchymal tumour.^{1,2} It constitutes five percent of all benign tumour of body and can be found anywhere in the body.³ Lipoma in head and neck region is a rarely encountered.^{4,5} Thirteen percent of lipomas are seen in head and neck region.⁶ Amongst the head and neck lipoma, commonest location is posterior neck. Anterior neck is a rare location for head and neck lipoma.⁷ Lipoma of anterior neck with mediastinal extension is extremely rare. Histologically, lipoma is composed of mature adipose tissue surrounded by fibrous capsule.⁸ Lipoma is seen in all age group though mostly seen in fifth and sixth decade.⁹ Solitary lipoma is common in female whereas multiple lipomas are common in male. Clinically, lipoma presents as painless, mobile, non-fluctuant swelling having rubbery consistency. Most of the patients are asymptomatic.

Patient with neck lipoma extending to mediastinum may present with complaint of dyspnoea. Ultrasonography acts as the initial imaging modality in diagnosis of head and neck lipoma.¹⁰ Sonographic appearance of head and neck lipomas are characteristic.^{10,11} In most cases, they are well defined, elliptical masses parallel to the skin surface and hyperechoic relative to the adjacent muscle. They typically have linear echoes at right angle to ultrasound beam and display no distal enhancement or attenuation.¹² Computed tomography is modality of choice to confirm lipoma. Lipomas appear as homogenous low density areas with a CT value of -60 to -120 HU with no contrast enhancement.¹³ Few septations can be seen within lipoma in CT scan in some cases. Fine needle aspiration cytology or CT is indicated if the diagnosis is doubtful with the clinical impression or if the entire extent or outline of the lipoma is not delineated on the sonogram.¹⁰ On CT scans capsule of lipoma is barely visible or adjacent mass effect may be only clue to its presence.¹⁴ Consecutive follow up might be a valid option for asymptomatic patients with anterior neck lipomas. Surgical intervention is challenging and should be reserved for patients with cosmetics and pressure effects. Possible postoperative complications such as vascular injury, vagus nerve dysfunction, scar and asymmetric contour must be clearly explained to the patient before operation is undertaken. Surgery should be done by experienced surgeon in meticulous way and complete removal is advocated to avoid recurrence.

REFERENCES

1. Kransdorf MJ. Benign soft-tissue tumors in a large referral population: distribution of specific diagnoses by age, sex, and location. *AJR Am J Roentgenol* 1995;164:395-402.
2. El-Monem MH, Gaafar AH, Magdy EA. Lipomas of the head and neck: presentation variability and diagnostic work-up. *J Laryngol Otol* 2006;120:47-55.
3. Enzinger FM, Weiss SW. Benign lipomatous tumors. In: Enzinger FM, Weiss SW, eds. *Soft Tissue Tumors*. 2nd edn. St Louis: Mosby; 1988.p.301-45.
4. Som PM, Scherl MP, Rao VM, Biller HF. Rare presentations of ordinary lipomas of the head and neck: a review. *AJNR Am J Neuroradiol* 1986;7:657-664.
5. Barnes L, Ferlito A. Soft tissue neoplasms. In: Ferlito A, ed. *Neoplasms of the Larynx*. 1st edn. London: Churchill-Livingstone; 1993.p.265-304.
6. Barnes L. Tumors and tumor-like lesions of the head and neck. In: Barnes L, ed. *Surgical Pathology of the Head and Neck*. New York: Marcel Decker Inc; 1985.p.747-758.
7. Medina CR, Schneider S, Mitra A, Spears J and Mitra A. Giant submental lipoma: Case report and review of the literature. *Can J Plast Surg* 2007; 15(4):219-222.
8. Kim YH, Reiner L. Ultrastructure of lipoma. *Cancer* 1982;50:102-106.
9. Salam G. Lipoma excision. *Am Fam Physician* 2002; 65:901-905.
10. Ahuja AT, King AD, Kew J, King W, Metreweli C. Head and neck lipomas: sonographic appearance. *AJNR Am J Neuroradiol* 1998;19:505-508.
11. Gritzman N, Schratler M, Traxler M. Sonography and computed tomography in deep cervical lipomas and lipomatosis of the neck. *J Ultrasound Med* 1988; 7:451-456.
12. Ahuja AT, King AD, King W. Thyroglossal duct cysts: sonographic appearances in adults. *AJNR* 1999(20):579-582.
13. Doooms GC, Hricak H, Sollitto RA. Lipomatous tumours and tumours with fatty components: MR imaging potential and comparisons between MR and CT results. *Radiology* 1985; 157:479-83.
14. Weissman JL. Nonnodal masses of the neck. In: Som PM, Curtin HD, eds. *Head and Neck Imaging*. 3rd ed. St Louis, MO: Mosby Year Book; 1996:794-822.