

Comparison of Ultrasound Guided Transversus Abdominis Plane Block Versus Local Wound Infiltration for Post Operative Analgesia in Patients Undergoing Gynaecological Surgery Under General Anaesthesia

Ranjit S, Shrestha SK

Department of Anaesthesiology

Dhulikhel Hospital - Kathmandu University Hospital

Kathmandu University School Of Medical Sciences

Dhulikhel, Kavre, Nepal

Corresponding Author

Sangina Ranjit

Department of Anaesthesiology

Dhulikhel Hospital - Kathmandu University Hospital

Kathmandu University School Of Medical Sciences

Dhulikhel, Kavre, Nepal

Email: sanginaranjit15@gmail.com

Citation

Ranjit S, Shrestha SK. Comparison of Ultrasound Guided Transversus Abdominis Plane Block Versus Local Wound infiltration for post Operative Analgesia in Patients Undergoing Gynaecological Surgery Under General Anaesthesia. *Kathmandu Univ Med J* 2014;46(2):93-6.

ABSTRACT

Background

Transversus abdominis plane block has been recently developed as a part of multimodal post operative analgesic techniques. We compared the analgesic efficacy of this technique with local bupivacaine infiltration in patients undergoing gynaecological surgeries with pfannenstiel incision and lower midline incision under general anaesthesia.

Objectives

To evaluate the efficacy of ultrasound guided transversus abdominis plane block for postoperative analgesia.

Methods

Patients were randomly allocated to three groups: control group (n=15), transversus abdominis plane block group (n=15), who received bilateral transversus abdominis plane block with 0.25% bupivacaine, and local infiltration group (n=15), who received local wound infiltration with 0.25% bupivacaine at the end of surgery. All patients received intramuscular diclofenac 12 hourly and intravenous tramadol SOS in the postoperative period. Visual analogue scores for pain were assessed at 1,2,4,8,12 and 24 hours postoperatively and these were compared between the three groups. Average tramadol consumption in 24 hours were also compared among the three groups. Data were subjected to univariate ANOVA test and chi-square test. Level of significance was set at 0.05.

Results

Visual analogue scores were significantly less in transversus abdominis plane block group and effect lasted up to 12 hours at rest postoperatively and 8 hours during cough and movement.

Conclusion

Bilateral Transversus abdominis plane block was effective in reducing postoperative pain scores for 8 to 12 hours postoperatively. This block was also successful in reducing postoperative opioid requirement.

KEY WORDS

Postoperative analgesia, transversus abdominis plane block, ultrasound guidance, visual analogue score.

INTRODUCTION

Traditionally, pain relief is provided by systemic medications such as opioids, non-steroidal anti-inflammatory drugs (NSAIDs), administering local anaesthetic into the skin around the surgical wound, or by providing epidural or spinal analgesia technique. Regional anaesthetic techniques and nerve blocks have been used for effective pain management in the perioperative period, either sole or in combination with systemic analgesics. Its use has been shown to decrease post operative complications, stress response, nausea, vomiting and other complications associated with use of opioids and to enhance recovery.¹ Transversus abdominis plane (TAP) block is a newly described easy and safe regional analgesic technique. The technique was first introduced by Rafi in 2001 and was further developed by Mc. Donnell.² This technique involves instillation of local anaesthetic agent into a fascial plane between the internal oblique muscle and transversus abdominis muscle, either by landmark technique, or under ultrasound guidance. Ultrasound guided block has been recently described as a technique that promises better localization and drug deposition.³

Pain experienced after abdominal surgery is primarily contributed by the incision made in the abdominal wall.⁴ TAP block anaesthetises somatic supply of the anterior abdominal wall, which arises from the anterior rami of spinal nerves and runs along the plane between internal oblique muscle and transversus abdominis muscle. Local infiltration around the wound site has also been widely used, but its efficacy as a potent and useful adjunct in multimodal analgesia has been controversial.⁵

In this study, we intended to compare between transversus abdominis plane block, local wound infiltration and conventional systemic analgesia alone in providing post operative analgesia to patients undergoing gynaecological surgeries with Pfannenstiel or infraumbilical abdominal incision under general anaesthesia.

METHODS

This randomized single blinded prospective study was undertaken at Kathmandu University School of Medical Sciences from July 2012 to February 2013.

After approval of Institutional Review Committee, 45 patients between the age of 25 years to 75 years undergoing gynaecological operations with Pfannenstiel incision or infraumbilical midline incision under general anaesthesia were enrolled in the study. Patients with ASA grade III and above, patients with coagulopathies, patients under analgesics preoperatively or those who are unable to express pain independently were excluded from the study. Included patients were randomized in one of the three groups with sealed envelope; Group T (TAP), Group L (local infiltration) and Group C (control).

Preoperative evaluation was done and written informed consent taken a day prior to surgery. All patients were premedicated with Lorazepam 1 mg and Pantoprazole 40 mg orally night prior and morning of surgery. On arrival to the operating room, intravenous access was obtained, monitor was connected and baseline non-invasive blood pressure (NBP), heart rate (HR), electrocardiography (ECG) and pulse oximetry (SpO₂) were noted. All patients were induced with inj. Midazolam 0.02 mg/kg and inj. Propofol 2 mg/kg. Analgesia was provided with inj. Fentanyl 3 µg/kg intravenous (IV). Patients were intubated with 7.5 mm ID endotracheal tube after relaxation provided by inj. vecuronium 0.1 mg/kg IV. Anaesthesia was maintained with 50:50 oxygen mixed with air, and isoflurane 1-1.5%. Intraoperative monitors: ECG, HR, NBP at 5 minutes interval, SpO₂, capnograph, nasopharyngeal temperature urine output and spirometer were continued throughout the operation. At the end of operation, Group T (n=15) were administered bilateral TAP block with 20 ml of 0.25% bupivacaine on each side by midaxillary approach. The procedure was performed under ultrasound guidance with Mindrey® portable ultrasound machine with 7.5 MHz linear probe. The patient in supine position, under aseptic conditions, the probe was placed transversely between the iliac crest and costal margin. A long peripheral nerve stimulating needle, 22G, 8 cm, was advanced in-plane. After visualization of the tip of the needle reaching the plane, 2ml of anaesthetic solution was instilled to view the hydrodissection, confirming the correct placement. Following this, the total volume of drug was instilled, creating a meniscus between the planes. Group L (n=15) received local wound infiltration with 0.25% bupivacaine 20 ml at the end of operation. All patients received diclofenac 75 mg intramuscularly (IM) 12 hourly and tramadol 50 mg IV SOS. Group C (n=15) received only systemic analgesics as mentioned above. Visual analogue score (VAS), 1-10 was recorded by a blinded investigator at 1,2,4,8,12 and 24 hours for different categories: at rest, during cough, and during mobilization. The blinded investigator was an intern from gynaecology department who was not participating in the operation. Patients with VAS score or > 4 received tramadol supplement. Secondary outcome was measured in terms of average dose of tramadol by each group in 24 hours.

Data were entered and analyzed using SPSS 17.0. Demographic data of patients were analyzed using ANOVA and baseline data, namely ASA physical status and types of operation were analysed using chi-square test. VAS scores and average tramadol consumption were compared between groups using univariate ANOVA test. P-value of less than 0.05 was considered to be statistically significant.

RESULTS

The demographic profile and baseline characteristics of the patients are shown in Table 1. The groups were comparable

in terms of age (p=0.712) and weight (p=0.317). Similarly, ASA physical status and type of operation were comparable among the three groups (p>0.05).

Table 1. Baseline data of enrolled patients

Patient data	TAP block	Local infiltration	Control	p-value
Age (years)	41.73±11.27	38.2±10.36	39±11.8	0.712
Weight (kg)	53.33±6.8	52.07±6.3	50.4±8.3	0.317
ASA physical status				
I	13	12	11	0.65
II	2	3	4	
Operation				
Total abdominal hysterectomy	12	11	11	0.35
Cystectomy	2	4	4	
Laparotomy	2	0	0	

VAS were significantly lower in the TAP group at rest, during cough and on flexion movement of lower limbs.

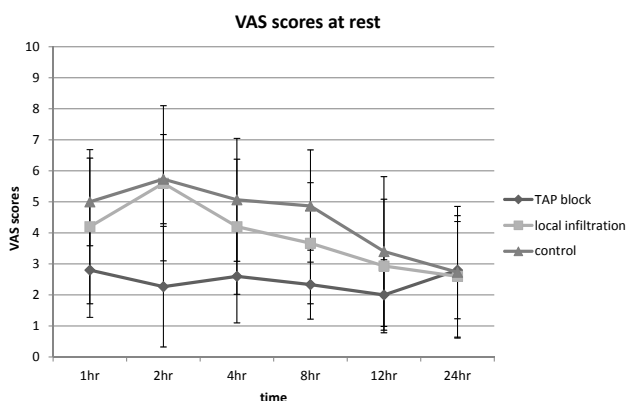


Figure 1. Post operative VAS scores at rest

Fig 1 shows mean VAS scores of the three groups at rest. It was significantly less in the TAP group at one hour (p=0.009), two hours (p<0.001), four hours (p=0.004) and eight hours (p=0.001) postoperatively. During cough, VAS scores were significantly less in TAP group at one hour (p<0.001), two hours (p<0.001), four hours (p<0.001) and eight hours (p=0.009) postoperatively (Fig 2).

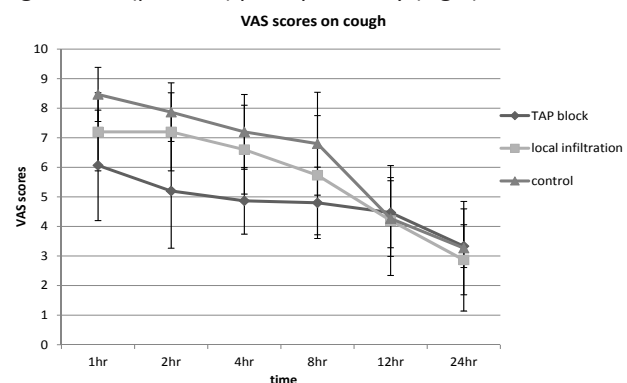


Figure 2. Postoperative VAS scores during cough

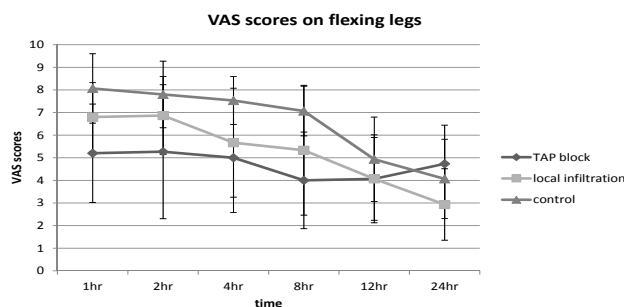


Figure 3. Postoperative VAS scores on movement

Fig. 3 shows mean VAS scores of the three groups on flexion movement of legs with similar findings. They were significantly less at one hour (p<0.001), two hours (p=0.009), four hours (p=0.005) and 8hrs (p=0.002), postoperatively.

Although VAS score was less at 12 hours postoperatively, there was no statistical difference at 12 and 24 hours for all the three categories of pain.

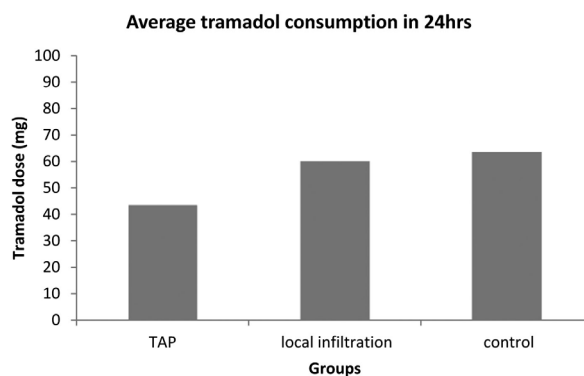


Figure 4. Average tramadol consumption

Fig. 4 shows average tramadol consumption in 24 hours. Local infiltration and control groups had similar tramadol consumption, whereas TAP group had less. However, there was no statistical significance (p=0.42)

There were no complications related to the procedure noted in either TAP block or local infiltration in any of the study subjects during the study period.

DISCUSSION

TAP block has been shown to provide effective postoperative analgesia for different types of lower abdominal surgeries.⁶ We performed the TAP block under ultrasound guidance because it is easy, reliable and safe.⁷ Complications of TAP block like liver injury, bowel hematoma, though possible, are less likely with ultrasound guidance.⁸

Many studies showing favorable results for TAP block claims to have effective analgesia period lasting 24 hours postoperatively and some even 48 hours.^{7,9} Our study revealed that there is reduction in postoperative pain for 12 hours at rest and 8 hours at cough and on movement. Mc Donnell et al reported similar findings. Reduction of pain score by at least 1.3 points on VAS score is considered significant in with acute pain.^{9,10} Our study showed clinically significant reduction of pain score with the use of TAP block

and not with local wound infiltration at rest, cough and on movement. Decreased pain perception on movement and cough can help in early mobilization, improvement in pulmonary function and better recovery of these patients. Thus TAP block can be considered to be superior to local wound infiltration.

Different approaches to TAP block has been mentioned in the literature. In our study we used midaxillary approach. This approach has been shown to block T12 to L2 dermatomes.¹¹ This would cover pfannenstiel and infraumbilical midline incision.¹¹⁻¹³ For higher incisions above umbilicus, a subcostal approach to the TAP plane would have been required. A more posterior approach using both landmark and ultrasound guide could block T5-L1.

Single shot injection of TAP is not comparable with neuraxial blocks like epidural analgesia, but Niraj G et al demonstrated comparable VAS scores when catheter was placed in transverses abdominis plane and continuous

infusion used.¹⁴ Harish et al used surgically placed unilateral continuous catheter technique in TAP block in patients undergoing open nephrectomy.¹⁵ No analgesic supplement was required for three days.

Systemic analgesia was provided in interval bolus doses. The time of assessment of pain might not correlate exactly with the effect of the drug.

CONCLUSION

Bilateral TAP block was effective in reducing postoperative pain scores at rest and movement for 8 hours after lower abdominal gynaecological surgeries under general anaesthesia. Use of adjuncts or use of continuous catheters might be used for prolonging the duration of the block. The block was superior to local wound infiltration. This technique can be a promising mode of postoperative analgesia where epidural catheter insertion is contraindicated.

REFERENCES

- Henrik Kehlet, Jørgen B Dahl. Anaesthesia, surgery, and challenges in postoperative recovery. *Lancet* 2003; 362: 1921–28
- Mc Donnell JG, O'Donnell BD, Farrell T, et al. Transversus abdominis plane block: a cadaveric and radiological evaluation. *Reg Anesth Pain Med* 2007; 32: 399–404.
- Hebbard P, Fujiwara Y, Shibata Y, Royse C. Ultrasound-guided transversus abdominis plane (TAP) block. *Anaesthesia and Intensive Care* 2007; 35: 616-7
- Wall PD, Melzack R. Pain measurements in persons in pain. Textbook of Pain. 4th Edition. Wall Edinburgh: Churchill Livingstone; 1999.
- Dahl J.B, Møiniche S. relief of postoperative pain by local anaesthetic infiltration: Efficacy for major abdominal and orthopedic surgery. *Pain* 2009; 143:7-11.
- Carney J, McDonnell JG, Ochana A, Bhinder R, Laffey JG. The transversus abdominis plane block provides effective postoperative analgesia in patients undergoing total abdominal hysterectomy. *Anesth Analg* 2008;107:2056–60.
- G. McDermott, E. Korba, U. Mata et al. Should We Stop Doing Blind Transversus Abdominis Plane Blocks? *Br J Anesth* 2012; 108(3):499-502
- Karim Mukhtar. Transversus Abdominis Plane Block. *The Journal of NYSORA* 2009; 12:28-33
- Mc Donnell JG, O'Donnell BD, Curley G, The Analgesic Efficacy of Transversus Abdominis Plane Block After Abdominal Surgery: A Prospective Randomized Controlled Trial. *Anesth. Analg* 2007;104:193–7
- Cepeda M.S, Juan M. A, Polo R, et al. What decline in pain intensity is meaningful to patients with acute pain? *Pain* 2003;105:151-7
- J. Carney, O. Finnerty, J. Rauf, et al. Studies on the spread of local anaesthetic solution in transversus abdominis plane blocks. *Anaesthesia* 2011; 66: 1023–30
- TH Lee, MJ Barrington, TM Tran, et al. Comparison of extent of sensory block following posterior and subcostal approaches to ultrasound-guided transversus abdominis plane block. *Anaesth Intensive Care* 2010;38(3):452-60.
- TMN Tran, JJ Ivanusic, P Hebbard and MJ Barrington. Determination of spread of injectate after ultrasound-guided transversus abdominis plane block: a cadaveric study. *British Journal of Anaesthesia* 2009; 102 (1): 123–7.
- G. Niraj, A. Kelkar, I. Jeyapalan. Comparison of analgesic efficacy of subcostal transverses abdominis plane blocks with epidural analgesia following upper abdominal surgery. *Anaesthesia* 2011; 66: 465–71
- Harish R. Low dose infusion with “surgical transverses abdominis plane (TAP) block “ in open nephrectomy. *Br J Anaesth* 2009; 102(6):889-90