

**Case Report****A Case Study on Hemorrhage Due to Cerebrovascular Disease**Araya Gautam\* <sup>1</sup>, Araju Gautam <sup>2</sup>, Saravanan Sabanantham <sup>3</sup>

<sup>1</sup>Teesside University, Middlesbrough, Department of Nursing and Midwifery, Tees Valley, TS1 3BX, United Kingdom, <sup>2</sup> Basildon University Hospital, Department of Emergency Medicine Nethermayne, Basildon, Essex, United Kingdom, <sup>3</sup> ESIC PGIMSR Medical College and Hospital, Joka, Kolkata, India

DOI: <https://doi.org/10.3126/jonmc.v13i1.68205>**Abstract**

Cerebrovascular disease includes some of the most common and devastating disorders: ischemic and hemorrhagic stroke. Stroke is the second leading cause of death worldwide, with 6.2 million dying from stroke in 2015, an increase of 830,000 since 2000. Stroke remains the most common disabling disease worldwide and in many forms is preventable. A stroke, or cerebrovascular accident, is defined as an abrupt onset of a neurologic deficit that is attributable to the focal vascular cause. Thus, the definition of stroke is clinical, and laboratory studies including brain imaging are used to support the diagnosis.

**Keywords:** *Cerebrovascular disease, Ischemic and haemorrhagic stroke, Neurologic deficit, Brain imaging***Case Report**

This is a case of 63 years old, male, from Dalupanon, Pasacao, Camarines Sur, Filipino, Roman Catholic, working as a businessman, admitted at our hospital for the third time.

**Chief complaint:** Dizziness (Dysequilibrium)**History of present illness**

3 hours before admission, the patient experienced a sudden onset of headache accompanied by right-sided weakness, slurring of speech, and 2x vomiting. No loss of consciousness and chest pain were noted. This prompted a consult at the Emergency room hence, admitted.

**Past medical illness**

Hypertension stage II (2012) – non-compliant with maintenance medication (Losartan 100mg


tab, 1 tab OD), Cerebrovascular disease (2012, 2017), 2012 - Infarct, left basal ganglia - non compliant to medications, lost to follow-up, no residual weakness, 2017–Haemorrhage, left thalamus–non compliant to medications, lost to follow-up, minimal right-sided residual weakness (Modified Rankin score: 2), (-) Diabetes Mellitus, (-) Bronchial Asthma, (-) Heart disease, Family history (+) Hypertension–maternal and paternal side.

**Personal and Social history**

The patient lives with his extended family of 10 members in a household; the patient is a known 10-pack-year smoker, occasional alcoholic drinker, and non-illicit drug user.

**Review of Systems**

Constitutional: no chills or loss of appetite  
Skin: No rash, No pruritus, no pallor

	<p>©Authors retain copyright and grant the journal right of first publication. Licensed under Creative Commons Attribution License CC - BY 4.0 which permits others to use, distribute and reproduce in any medium, provided the original work is properly cited.</p>	<p><b>*Corresponding Author:</b> Dr. Araya Gautam Research Scholar Email: <a href="mailto:araya.cu@gmail.com">araya.cu@gmail.com</a> ORCID: <a href="https://orcid.org/0000-0002-3715-5028">https://orcid.org/0000-0002-3715-5028</a></p>
---	---	---

**Citation**

Gautam A, Gautam A, Sabanantham S, A Case Study on Hemorrhage Due to Cerebrovascular Disease, JoNMC. 13:1 (2024) 108-112. DOI: <https://doi.org/10.3126/jonmc.v13i1.68205>.



Eyes: No eye redness, no doubling, no blurring of vision

Ear: No ear discharge, no tinnitus, no ear pain

Nose and Sinuses: No nasal discharge, no anosmia, no epistaxis

Throat: No sore throat, no hoarseness, no mass

Respiratory: No shortness of breath, No cough/colds

CVS: No chest pain, no palpitations

GI: No abdominal pain, (+) nausea or vomiting, no diarrhoea, no haematemesis, no melena, no haematochezia, no change of bowel movement, no constipation

GUT: no dysuria, no urinary frequency, no urinary dribbling, no hesitancy, no urethral discharge

Musculoskeletal: No myalgia, no arthralgia, no numbness

Neurologic: No behavioural changes, no loss of consciousness, no paraesthesia, no paralysis, no muscle weakness

Hematologic: No easy bruising, no history of transfusion reaction

Endocrine: No heat/cold intolerance, no polyuria, no polyphagia, no polydipsia

On physical examination, patient is the following vital signs: BP: 180/100mmHg, HR: 76 bpm RR: 21 cpm, Temp: 36.9 degrees Celsius, O2 saturation: 99%, Skin: Brown complexion, no bruises, no skin lesions. Head and Face: Hair is black, evenly distributed, normocephalic, no mass or tenderness, no swelling or deformities. Face is asymmetrical, no lesions, no mass, no involuntary movements. EENT: Anicteric sclera, pink palpebral conjunctiva, no nasosaural discharge, buccal mucosa and gums are pink and moist, smooth no signs of swelling or bleeding, no tonsilopharyngeal congestion, neck is symmetrical, trachea is at midline, no neck vein engorgement, no cervical lymphadenopathy, no palpable neck mass. Chest: Chest is symmetrical, without deformities, no lesions. No visible superficial blood vessels. Symmetrical chest lung expansion. No retractions or chest lagging no tenderness, or masses on palpation. With equal, vesicular breath sounds on both lungs. No adventitious sounds. Percussion of the lungs was resonant and equal. Cardiovascular: No chest wall deformities and no scars. A dynamic precordium. No parasternal heave or thrills. Apex beat at the fifth intercostal space in the left mid-clavicular line, with normal rate, irregularly irregular rhythm. No extra heart sounds or murmurs. Jugular vein not distended. Carotid artery pulsations are strong regular and equal.

Abdomen: Flabby abdomen, umbilicus midline, no superficial blood vessels, no visible mass.

Normoactive bowel sounds. Tympanitic on percussion. No masses or organomegaly on light and deep palpation.

Extremities: No gross deformity. No lesions. There were no bruises, skin discoloration, macular haemorrhages noted on the skin, palms or soles. No finger clubbing, no splinter haemorrhages.

### Neurologic Examination

Fully awake, with regard, follows commands, oriented to person, place, and time, with spontaneous and purposeful movement of all extremities.

Cranial Nerves

CN I: Can identify test substance - bilateral

CN II: No visual field cuts - OU

CN II, III: Pupils 2-3mm, equal and briskly reactive to light

CN III, IV, VI: Primary gaze at the midline; Full EOM; No ptosis

V: V1-V3 - No sensory deficit – bilateral; good masseter and temporalis tone VII: (+) Right central facial palsy

VIII: Intact gross hearing

IX, X: Intact gag reflex - bilateral, uvula at the midline, equal soft palatal elevation

XI: Good and equal shoulder shrug, good SCM tone -bilateral

XII: Tongue at the midline

Motor

Upper Right 3/5 Left 5/5

Lower Right 3/5 Left 5/5

Sensory: 100% on all extremities on light touch and pin prick

### Admitting diagnosis

1. Acute Cerebrovascular Disease, Infarct, Left middle cerebral artery territory probably cardioembolic in origin, National Institute of Health Stroke Scale 5
2. Chronic Cerebrovascular disease infarct, Left Basal Ganglia
3. Cardiac dysrhythmia, atrial fibrillation in Controlled ventricular response
4. Hypertension stage II

### Course in the ward

The patient was received at the ward with the vital sign of BP: 150/100, Hr: 89, Rr: 19, T: 36.7, O2 sat: 98%, GCS 11(E3V2M6), still with headache. Laboratories revealed leucocytosis of 12.70, hemoglobin of 162, hematocrit of 0.495, and platelet of 160. Elevated creatinine of 113 and insignificant electrolyte of Na: 138, K: 3.50, BUN: 3.80, ALT: 15, AST: 23. Pro-time control of 11.7, %



of 79.74, and INR of 1.10, ECG was taken and shows: Atrial fibrillation in Controlled ventricular response. The patient was for a cranial CT scan however awaiting funds for the requested imaging. Medications were continued from ER such as Atorvastatin 40mg tab OD HS, Losartan 100mg tab OD, Omeprazole 40mg IV OD, Citicoline 1gm IV BID, Paracetamol 600mg IV q6 RTC for headache. The patient was referred to the Cardiology subspecialty for the carotid duplex scan. The patient was monitored every 4 hours with Neurological vital signs monitoring. On the 1<sup>st</sup> & 2<sup>nd</sup> hospital days, the patient experienced persistent headaches still with slurring of speech. The patient was GCS 15, awake, coherent, afebrile, and not in distress with vital signs of 140-150/80-90, HR range of 75-90, Rr range of 15-20s, and O2 saturation of 95-100%. The patient was still for a cranial CT scan and still waiting for funds for imaging. The patient was referred to Cardio for 2DED and Rehab department for early rehabilitation.

On hospital day 3, the patient had a persistent headache with a noted elevation of BP at 210/170, A Nicardipine drip was started. The patient was noted with a decrease in sensorium of GCS 14 (E3V5M6). Cranial CT scan showed acute haemorrhage cerebellar vermis (measuring 2.5x2.6x3.0cm) with mass effect and mild hydrocephalus; vascular infarcts of both thalami and basal ganglia; bleeding of approximately 10ml.

On hospital day 4, 5, 6 & 7, patient still has persistence of headache with uncontrollable BP range of 170-190/90-110, with febrile episodes, however with maintained GCS of 14 (E3V5M6). Nicardipine drip continued and oral anti-hypertensive medications started. Neurosurgery referral followed up. On hospital day 8, noted to have decreased in the sensorium of GCS 11 (E4V1M6). Mannitol was started at 400ml as loading dose then 200ml q6, Acetazolamide 250mg/tab TID was started. Repeat CT scan was done and shows: Cerebellar haemorrhage (measuring 3x2.8cm) with mild hydrocephalus; Lacunar infarcts, both thalamoganglionic region; White matter chronic small vessel ischemic changes.

On hospital day 9, the patient had a persistence of decreased in sensorium to GCS 8 (E3V1M4), in respiratory distress and decreased in motor strength of left extremity: 4/5 and right extremity of 1/5. The patient was intubated, and the family was prognosticated. The patient was seen by neurosurgery and was scheduled for stat suboccipital craniectomy with the evacuation of

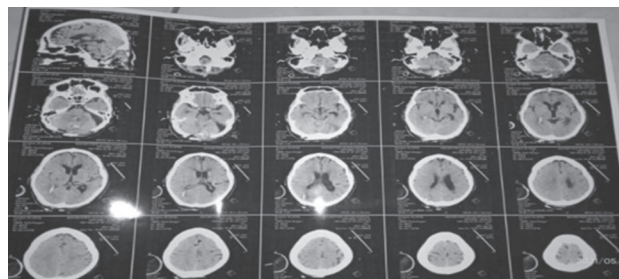
hematoma. On hospital day 10, the patient underwent craniectomy with evacuation of hematoma and was subsequently transferred to MICU with GCS 11 (E4V5M6). Following medications were continued at the MICU: Nicardipine drip was continued due to uncontrolled BP range of 160-180/90-100, Omeprazole 40mg IV OD, Tramadol 50mg IV q6 PRN, Totilac 100ml q8, Mannitol 150ml q6, Carvedilol 6.25mg tab ½ tab BID, Citicholine 1g IV q12, Irbesartan 300mg tab OD, Amlodipine 10mg tab OD, Acetazolamide 200mg tab TID, Lactulose 30ml OD HS.

On hospital day 11 to 15, the patient continued to have improved in sensorium to GCS 11 (E4V1M6) and seemed to be able to talk. The patient self-extubated on hospital day 12 and was continued to be monitored for any desaturations and decreased in sensorium. BP however was still uncontrolled, with BP range of 160-170/90-100 despite Nicardipine drip and oral anti-hypertensive medications. On hospital day 16, Mannitol and Totilac started to taper down. 2DED was done before trans out to the regular ward. 2DED showed: Concentric left ventricular hypertrophy with segmental wall motion abnormality with preserved global resting systolic function; Dilated left atrium without visible thrombus; Mitral and aortic sclerosis.

2DED showed:

- Ejection fraction: 55%
  - dilated left atrium with no visible thrombus
  - normal tricuspid valve and pulmonic valve - thickened mitral valve leaflets without restriction of motion.
- On hospital day 17, the JP drain and ventriculostomy were removed, with a total drain of 700cc serosanguinous on ventriculostomy and a total of 420cc serosanguinous drain on JP drain. BP was controlled with a BP range of 140-150/100. A repeat cranial CT scan was done and showed:

Minimal cerebellar bleed; slightly dilated lateral ventricles; 4<sup>th</sup> ventricle not dilated with minimal bleed; midline structures are in place.



On hospital day 18, the patient was for 24 hours of observation post-removal of JP drain and ventriculostomy, no untoward decrease in sensorium, and BP was maintained at a con-



trolled range of 130-140/90-100. The patient was GCS 15, with no noted headache and dizziness. With tolerable pain on the craniectomy site. The patient was discharged on hospital day 19 with the vital signs of BP: 130/100, Hr: 92, Rr: 19, T: 36.2, O<sub>2</sub> sat: 99%, GCS 15, conscious, coherent, afebrile, no noted headache, still with right-sided weakness and motor strength of 3/5 both in the right upper and lower extremity, left upper and lower extremity of 5/5. Taken-home medications included: Citicholine 500mcg tab BID, Omeprazole 40mg tab OD, Tramadol + Paracetamol tab PRN for pain, lactulose 30cc OD HS, Irbesartan 300mg tab 1 tab OD, Amlodipine 10mg tab OD, Digoxin 0.25mg tab 1 tab OD, Carvedilol 25mg tab ½ tab BID, Atorvastatin 40mg tab OD HS, Rivaroxaban 10mg tab OD.

### Final diagnosis

1. Acute Cerebrovascular disease haemorrhage, Cerebellar area
2. Cardiac dysrhythmia, Atrial fibrillation in Controlled ventricular response
3. Status post suboccipital craniectomy with evacuation of intracranial hematoma (4/21/21)
4. Hypertension stage II

### Discussion

The causes of stroke injuries as observed in our patient included: uncontrolled systolic and diastolic blood pressure, alcohol use, excessive salt intake, and lack of follow-up. Improving primary stroke prevention requires health education on hypertension-related consequences and lifestyle choices at every follow-up visit [1]. Both modifiable and non-modifiable risk variables are major contributors to the high incidence of stroke among hypertension people [2]. In addition to encouraging patients to live a healthy lifestyle early blood pressure screening, medication adherence, education, and behavioural risk assessment could greatly help patients reduce their chances of having a stroke.

Uncontrolled and untreated hypertension raises the risk of stroke by a large margin. Managing it effectively reduces the risk of having another stroke [3]. Lowering blood pressure can support better recovery outcomes by reducing the strain on the heart and blood vessels, promoting healing and rehabilitation. The increasing incidence of stroke may be lowered by focused initiatives involving local communities, health-care professionals, and legislators that address gaps in hypertension prevention and treatment. A substantial stroke burden is indicated by the high

prevalence of uncontrolled hypertension and advanced-stage blood pressure in patients who had previously experienced a haemorrhagic stroke [4]. Thus, it should be a top focus to effectively treat hypertension over the long term in stroke survivors [5].

### Conclusion

Several interventions can be used to reduce the effects of stroke, including regular physical examinations, blood pressure assessments, patient education about risky behaviours like drinking or smoking, and patient counselling about the significance of medication compliance. Strokes frequently result from uncontrolled or untreated high blood pressure. We must address the gaps in the prevention and treatment of high blood pressure if we hope to reduce the rising number of strokes. Health policymakers, physicians, and local communities should all be involved in these endeavours. Even after a previous haemorrhagic stroke, many patients may still have uncontrolled hypertension. This suggests that untreated hypertension is a major concern as it poses serious life-threatening problems since patients with refractory hypertension are significantly more likely to develop cardiovascular and cerebrovascular complications than patients with controlled hypertension. Therefore, it's critical to concentrate on the long-term management of hypertension in stroke survivors as it can reduce the need for hospitalizations, medical interventions, and medications, leading to lower healthcare costs.

To protect stroke patients from repeated vascular events, this case study emphasizes the unaddressed difficulties in optimizing hypertension diagnosis and treatment.

### References

- [1] Denisova, A. R., Solntseva, T. D., Zarmanbetova, A. S., Tkacheva, A. A., Sivakova, O. A., & Chazova, I. ?. (2022), The incidence of cardiovascular and cerebrovascular complications in patients with uncontrolled hypertension. *Terapevticheskii Arkhiv*, 94:1 (2022) 94-99. DOI: <https://doi.org/10.26442/00403660.2022.01.201395>.
- [2] Liu W, Huang X, Liu X, Ortega D, Chen L, Chen Z et al, Uncontrolled hypertension associates with subclinical cerebrovascular health globally: a multimodal imaging study, *Eur Radiol*. 31:4 (2021) 2233-2241. DOI: 10.1007/s00330-020-07218-5. PMID: 32929643.
- [3] Upoyo, A.S., Setyopranoto, I. and Pangastuti, H.S. (2021), The Modifiable Risk Factors of Uncontrolled Hypertension in Stroke: A Systematic Review and Meta-Analysis. *Stroke Research and Treatment*. (2021) 1-11. DOI: <https://doi.org/10.1155/2021/6683256>.
- [4] Oftedal, Å., Gerds, E., Waje-Andreassen, U., Fromm,



A., Naess, H., Linde, A et al, Prevalence and covariates of uncontrolled hypertension in ischemic stroke survivors: the Norwegian stroke in the young study, Blood Pressure. 27:3 (2018)173-180. DOI: <https://doi.org/10.1080/08037051.2018.1425827>.

[5] Tomek, A., The impact of uncontrolled hypertension on the CNS, Vnitri Lekarstvi. 69:2 (2023)105-108. DOI: <https://doi.org/10.36290/vnl.2023.017>.

