

Original Article**Outcome of Corrective Dome Osteotomy for Cubitus Varus Deformity****Ranjib Kumar Jha*, Santosh Thapa and Dhiraj Singh**

Department of Orthopaedics, Nobel Medical College Teaching Hospital, Biratnagar, Nepal

Article Received: 26th September, 2019; Accepted: 30th November, 2019; Published: 31st December, 2019**DOI: <http://dx.doi.org/10.3126/jonmc.v8i2.26760>****Abstract****Background**

The cubitus varus deformity is one of the most common late complications of fracture supracondylar area of humerus in children. Various corrective osteotomies are used of which lateral closed wedge osteotomy is commonly done which has its own disadvantages like lateral condylar prominence, difficulty in achieving correction and limitation of movement. Dome osteotomy is a versatile technique to achieve correction of deformity in all planes and to overcome these above complications. The aim of this study was to evaluate the results of dome osteotomy for correction of post-traumatic cubitus varus deformity of elbow in children.

Materials and Methods

The study included 18 children between 6-13 years of age of both sex with malunited supracondylar fracture of distal humerus having cubitus varus deformity. After appropriate pre-operative assessment, dome osteotomy was done by posterior approach. In pre and post operative x-ray carrying angle and lateral condylar prominence Index (LCPI) were calculated. Patients were re-assessed at complete union and results were calculated.

Results

In this study of 18 patients, 12 were males and 6 were females. The age ranged from 6-13 yrs with average of 8.4yrs. The average correction of carrying angle was from -22.4 degree to +10 degree. LCPI changed post operatively ranging from -8.6% to +3.25%, average -2.9%. There were no significant complications. Fifteen patients had excellent outcome and 3 had good outcome.

Conclusion

The results in our study concluded that dome osteotomy for cubitus varus is safe and effective method and give cosmetically more acceptable elbow.

Key words: *Deformity, Elbow, Osteotomy*

Licensed under CC BY 4.0 International License which permits use, distribution and reproduction in any medium, provided the original work is properly cited.

***Corresponding author**

Dr. Ranjib Kumar Jha
Assistant Professor
Email: ranjib.k30@gmail.com
ORCID: <https://orcid.org/0000-0002-4708-3347>

Citation

Jha RK, Thapa S, Singh D, Outcome of Corrective Dome Osteotomy for Cubitus Varus Deformity, JoNMC. 8:2 (2019) 42-46.



Introduction

Malunion of supracondylar fracture of humerus in children leading to cubitus varus deformity is the most common late complication, incidence ranging from 4% to 58% [1, 2]. The residual coronal tilt of a distal humeral fracture is the cause of the deformity. The published literature shows that growth abnormalities and osteonecrosis are rare but important cause of deformity [3, 4]. There is no spontaneous remodeling of cubitus varus deformity, so surgery is the only method to correct the deformity.

There are different surgical procedure to correct cubitus varus deformity with its own merits and demerits. They are as follows; Medial open wedge osteotomy, which can cause stretching of ulnar nerve due to lengthening of medial column of humerus [5], Lateral wedge closing osteotomy also called French osteotomy [6,7], Step cut osteotomy, Arch osteotomy [8], Pentalateral osteotomy [9], Oblique osteotomy with derotation, Dome osteotomy [10]. The different osteotomies performed can be stabilized by using plates and screws, screws, different wires and staples. Inadequate fixation of osteotomy can lead to recurrence of deformity [11]. The dome osteotomy itself provides stability of osteotomy, rotation and angulation can be corrected simultaneously and it also avoids lateral condylar prominence to increase [12].

The aim of the study was to evaluate the outcome of dome osteotomy for correction of post-traumatic cubitus varus deformity of elbow in children.

Materials and Methods

This is a prospective study, which was conducted in department of orthopaedics of Nobel Medical College Teaching Hospital of a period between June 2016 to July 2018. A written informed consent was taken from parents before inclusion in this study. The inclusion criteria were age of children less than 15yrs, cubitus varus deformity due to malunited supracondylar fracture of humerus and the parent's concern for cosmetic appearance of elbow. Those patients who were more than 15yrs of age, refused for surgery, fracture of less than three weeks duration and having neurovascular compromise were excluded from the study. The present study consisted of total 18 cases of either sex with malunited supracondylar fracture with cubitus varus deformity.

The study considers 95% CI and 80% power to estimate the sample size. In this regard, the study considered the angle correction was approximately 32 degree among children with malunited supracondylar fracture. Now using this formula $n =$

Z^2pq/L^2 , Where $Z = 1.96$, $p = 32$, $q = 68$, L (20% of p) = 6.4. Calculated sample size would be 204. According to our record of last two year, total 15 patients were treated (estimated population). Now using corrected sample size formula for finite population, $n = \text{calculated sample size} / 1 + \text{calculated sample size} / \text{estimated population}$. Corrected sample size would be 14. But the study sample size considered all cases who met the study criteria during our study period.

After clinical evaluation by taking history, general physical examination and local examination, antero-posterior (AP) and lateral radiographs of both elbows were taken with elbow in full extension and forearm in full supination. The humerus-elbow-wrist angle was measured on both sides using Oppenheim method and the angle of correction was calculated. The preoperative plan also included tracing of the AP radiographs of both injured and uninjured elbow. The former was reversed 180 degree and superimposed on the latter so that the desired correction angle (α) could be calculated. The lateral condylar prominence index (LCPI) was calculated on the affected side as described by Wong HK [13], using formula $\{LCPI = AB - BC / AC \times 100\}$, where B is the crosslink between a line connecting the lateral prominence A, the medial prominence C and the longitudinal mid-humeral axis as shown in figure .1. Range of motion of both elbow, complaints of cosmesis, pain and loss of motor power and sensation in affected side was recorded.

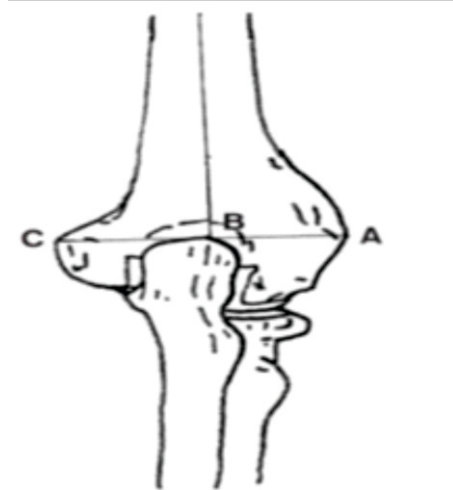


Figure 1: Calculating the lateral condylar prominence index (LCPI) [7]



Preoperative Plan for Osteotomy:

The mid-humeral axis was drawn in the antero-posterior (AP) radiograph of affected elbow. This axis cuts the olecranon fossa which was marked as point (point O), another point at the junction of lateral condylar epiphysis and humerus was marked as (point A). Now point O and A were connected. Angle correction was drawn considering line OA as a base. Another point (point B) was marked where this angle cuts the distal humerus. Now point O becomes centre and line OB the radius of dome. With radius OB, an arc of dome was drawn. This arc becomes the proposed site of osteotomy as shown in fig 2A,B.

Surgical Technique

Under general anesthesia, the surgery was done via posterior approach. The distal humerus was exposed by splitting triceps muscle. Along the arc of proposed dome osteotomy, interrupted holes were made by 1.8mm kirschner wire. Then osteotomy was completed with a $\frac{1}{4}$ inch osteotome. The distal fragment was rotated along the arc until point A meets point the point B of proximal fragment. At the same time, saggital and rotational deformity were also corrected by manipulating distal fragment. In this way the elbow was realigned as planned(fig.2B). In lower age children, only percutaneous cross pin fixation for the osteotomy was performed (Fig.3A). However, in larger children more rigid fixation devices (such as single or dual plates or lateral plate and medial wire) were applied (Fig 3B). Postoperatively, the elbow was immobilized by a long-arm posterior splint with 90 degree elbow flexion for 3 weeks, after which active ROM exercises were started. The pins were removed at the end of the fourth week in an outpatient clinic.

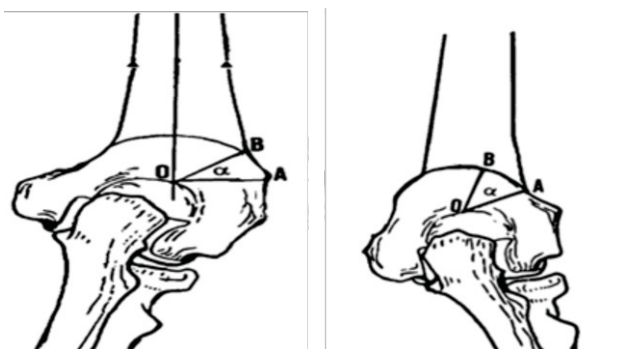


Fig 2 A, B .The intersection of the mid-humeral line and upper margin of the olecranon fossa (Point O) was designated as the center of the

dome. With the OA line as the base, a second line was drawn from O to B to form an angle (α) that was equal to the planned correction angle. Based on these parameters the arc of dome osteotomy was defined [7].

In post-operative X-ray, carrying angle and LCPI were calculated. Follow up was done every four weeks with X-ray till complete radiological union of osteotomy and complte expected results were obtained. At final follow up carrying angle, LCPI and range of motion of elbow were recorded. Parents and patients were asked about the cosmetic satisfaction with results.

Carrying angle, ROM and change of lateral condylar prominence index were used as main criteria to categorize the results. A result was considered excellent when the correction of the varus deformity was within 5 degree of the contralateral elbow, motion was within 5 degree of the preoperative flexion and extension arcs, and the lateral condylar prominence index was not increased. A good result was recorded when the corrected elbow was in a valgus position, motion was within 10 degree of the preoperative motion arcs, and the increase of lateral condylar prominence index was within 25%. A poor result was assigned to any case with a residual varus deformity, loss of more than 10 degree of preoperative motion arcs, or increase of lateral prominence index more than 25%.

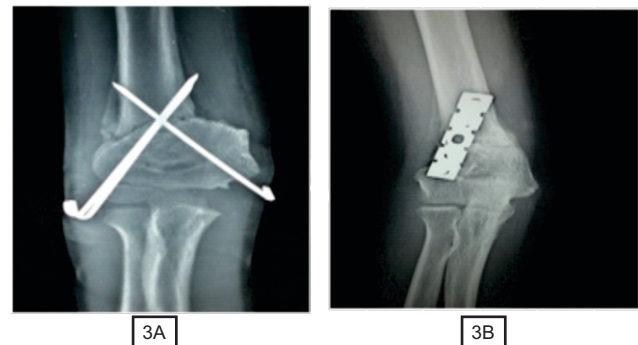


Figure 3 (A, B): The osteotomy was fixed with cross k-wires and and plate and screws.

Results

Out of total 18 patients there were 12male and 6 female. The age of the children were ranged from 6-13 years with average age of 8.4 years. The patients presented with cubitus varus, eleven had right sided and 7 had left sided deformity. Before operation the average carrying angle was -22.4 degree, whereas after corrective dome osteotomy



average carrying angle was 10 degree and the average carrying angle in normal side was 11 degree. The follow up period ranged between 6 to 12 months with average of 7.5months.

The ROM of the involved elbow was normal in 12 patients. Five patients had 8 degree hyperextension of the elbow and two of them had lost 7 degree of flexion. One patient had flexion and extension lag of 15 and 10 degrees, respectively.

In all 18 patients, correction of the deformity was maintained well through the healing stage. No loosening of fixation or loss of obtained correction had occurred, and no revision surgery was needed.

The post-operative lateral condylar prominence index ranged from -6.4% to +9.3, with an average of +1.6%. Post operative LCPI decreased, ranging from -8.6% to +3.25%, average being -2.9%. Change in LCPI ranged from +5.45% to -9.7%, with an average of -2.64%. When compared with the preoperative lateral prominence index, the postoperative lateral condyle did not become prominent and the index actually was improved. The patients were satisfied with the cosmetic outcome and none complained about the operative scar. Categorizing these results, 15 were excellent, two good, and one poor result. No patient reported pain, stiffness, weakness, or functional limitation of motion.

Table 1: Data on patients

Patient no.	Age (yrs)	Gender	Side of limb	Duration of follow up in months	preoperative	Carrying angle in degree Final follow up	Normal side
1	10	M	Left	6	-25	10	10
2	6	M	Left	8	-30	7	10
3	7	M	Left	6	-15	12	11
4	8	Fe	Right	8	-28	10	12
5	6	M	Left	10	-26	10	12
6	7	Fe	Right	8	-24	14	13
7	9	M	Right	6	-22	9	10
8	13	Fe	Left	12	-20	10	12
9	10	M	Right	7	-15	9	10
10	8	M	Left	8	-22	10	10
11	9	Fe	Left	6	-23	12	10
12	11	M	Left	8	-24	10	12
13	8	Fe	Left	6	-20	11	12
14	7	M	Right	7	-25	9	10
15	6	M	Right	8	-20	8	8
16	8	M	Right	9	-15	10	11
17	9	M	Left	6	-30	9	10
18	10	Fe	Left	7	-20	13	13
Average	8.4yrs			7.5months	-22.4 degree	10 degree	10.9degree

Discussion

The most common complications of the lateral closing wedge osteotomy are inability to achieve desired degree of correction and loss of correction due to inadequate fixation. Therefore, to avoid this complication, numerous modifications of technique have been recommended, including orientation of



Figure 4: clinical photograph of pre and post dome osteotomy done in 9 years child with post-traumatic cubitus varus deformity of right elbow.

the angle of the osteotomy, critical fixation pin angle, preserving the medial cortex,[6]and fixation of the osteotomy by using a two-hole lateral plate plus a medial percutaneous pin[14].

The center of rotation of the distal humeral fragment is located at the medial cortex in the lateral closing wedge osteotomy whereas in dome osteotomy center of rotation is in midline of distal humerus. So only half of rotation arc is necessary to correct the deformity. In this condition, a much smaller varus moment will be acting at dome osteotomy site and the round shaped distal fragment usually is contained well in the dome of proximal fragment. Therefore, with a dome osteotomy, mechanical stability is increased. The posterior approach for fixation provides optimal site and orientation for pin and plate and screws fixation. So dome osteotomy can be rigidly fixed to maintain the correction. In our series there was no loss of angle of correction, no loosening of fixation and no revision of surgery was required. Lateral condylar prominence is troublesome cosmetic deformity which occurs in different osteotomies [15].

The center of rotation is located in midline in dome osteotomy; therefore, the lateral condyle will not shift away from midline. As shown in our result, the LCPI before and after surgery of our study did not increase. According to wilkins, [10] the domed osteotomy is often difficult to rotate in coronal plane because of tight medial soft tissue, especially in the intermuscular septum. In experience of Tien et al, [12] the tightest soft tissue resisting at the osteotomy site was thick anterior periosteum. They recommended some modifications like complete division of anterior periosteum and curving of the AB segment of lateral cortex to facilitate the rotation [12]. In our series by dividing anterior thick periosteum distal fragment was easily rotated along the arc of dome. We did not curve the AB segment of lateral cortex of distal fragment. The limitation of our study is small sample size. So we could not use statistical tool to compare with other technique of correction and fixation.



Conclusion

Dome osteotomy for correction of cubitus varus is safe, effective and gives cosmetically more acceptable elbow.

References

- [1] Hayer A, Treatment of supracondylar fracture of the humerus by skeletal traction in abduction splint, *J Bone Joint Surg Am.* 54 (1952) 623-37. PMID: 14946214.
- [2] Piggot J, Graham MK, McCoy GF, Supracondylar fracture of the humerus in children: Treatment by straight lateral contraction, *J Bone Joint Surg.* 68 (1986) 577-83. PMID: 3733834
- [3] Piggot J: Supracondylar fracture of the humerus in children. Analysis at maturity of fifty-three patients treated conservatively, *J Bone Joint Surg.* 68A:1304 (1986). Letter
- [4] Noonan KJ, Jones JW, Recurrent supracondylar humerus fracture following prior malunion, *Lowa Orthop J.* 21 (2001) 8-12. PMID: 11813957.
- [5] King D, Sector C. Bow elbow (cubitusvarus), *J Bone Joint Surg Am.* 33(1951) 572- 76. PMID: 14850495.
- [6] Oppenheim WL, Clader TJ, Smith C, Bayer M, Supracondylar humeral osteotomy for traumatic childhood cubitusvarus deformity, *Clin Orthop Relat Res.* 188 (1984) 34-39. PMID: 6467726.
- [7] Devnani AS, Lateral closing wedge osteotomy of humerus for post traumatic cubitusvarus in children, *Injury.* 28 (1997) 643-47. PMID: 9624344.
- [8] Matsushita T, Nagano A, Arc osteotomy of the humerus to correct cubitusvarus, *Clin Orthop.* 336 (1997) 111-15. PMID: 9060493.
- [9] Laupatlarakasem W, Mahaisavariya B, Kowsuwon W, Pentalateral osteotomy for cubitus varus: clinical experience of new technique, *J Bone Surg Br.* 71 (1989) 667-70. PMID: 2768319.
- [10] Tachdjian MR, Osteotomy of distal humerus for correction of cubitus varus : Smith AB, ed., *Pediatric Orthopaedics*, Philadelphia. WB Saunders, 1972:158891.
- [11] Roach JW, Hernandez MA, Corrective osteotomy for cubitusvarus deformity, *J Paediatric Orthop.* 14 (1994) 487. PMID: 8077432.
- [12] Tien YC, Chin HW, Lin GT, Dome corrective osteotomy for cubitus varus deformity, *Clin Orthop Rel Res.* 380 (2000) 158-66. PMID: 11064986.
- [13] Wong HK, Lee EH, Balasubramaniam P, The lateral condylar prominence. A complication of supracondylar osteotomy for cubitus varus, *J Bone Joint Surg Br.* 72:5 (1990) 859–61. PMID: 2211772.
- [14] Hernandez III MA, Roach JW: Corrective osteotomy for cubitus varus deformity, *J Pediatric Orthop.* 14 (1994) 487–491. PMID: 8077432.
- [15] Matsushita T, Nagano A, Arcosteotomy of the humerus to correct cubitus varus. *Clinical Orthop Relat Res.* 336 (1997) 111-15. doi:10.1097/00003086-199703000-00015.
- [16] Wilkins KE: Fractures and Dislocations of the Elbow Region, In Rockwood CA, Wilkins KE, King RE (eds), *Fractures in Children.* Ed 4. Philadelphia, JB Lippincott Company 604–605, 1990.

