

# CORTICOTOMY ASSISTED ORTHODONTIC TREATMENT

## A REVIEW

Thakur Amresh\*  
Halwai Hemant Kr \*\*  
Jayaram Arpitha\*\*\*

\*\*Dr Hemant Kumar Halwai  
Associate Professor  
\* JR 2<sup>nd</sup> Year  
\*\*\*Assistant Professor  
Department of Orthodontics  
UCMS College of Dental Surgery  
Bhairahawa, NEPAL.

## INTRODUCTION

Dentoalveolar surgeries such as corticotomies and osteotomies can alter the bone biology of tooth movement. Bone turnover is well known to be accelerated after bone fracture, osteotomy, or bone grafting. This could be explained by a regional acceleratory phenomenon (RAP); i.e., osteoclasts and osteoblasts increase by local multicellular mediator mechanisms containing precursors, supporting cells, blood capillaries, and lymph. RAP also occurs in the mandible. Similarly, bone turnover is increased by RAP after a corticotomy. The velocity of orthodontic tooth movement is influenced by bone turnover, bone density, and hyalinization of the PDL. Wilcko et al<sup>1</sup> mentioned, in cases of rapid orthodontics with corticotomies, that corticotomies could increase tooth movement by increasing

bone turnover and decreasing bone density.

There is increased number of adult patients seeking orthodontic treatment. In adults growth is almost compared to children, cell mobilization and conversion of collagen fibers is much slower than in children and they are more prone to periodontal complications since their teeth are confined in non-flexible alveolar bone. This makes orthodontic treatment of adults different and challenging. Corticotomy assisted orthodontics provides solution to many of the problems in adult orthodontic treatment. It reduces treatment time, enhances expansion, differential tooth movement, and increased traction of impacted teeth and, finally, more post-orthodontic stability.

## HISTORICAL BACKGROUND

In 1892<sup>1</sup>, it was first defined as a linear cutting technique in the cortical plates surrounding the teeth to produce mobilization of the teeth for immediate movement. Kole<sup>2</sup> introduced a surgical procedure involving both osteotomy and corticotomy to accelerate orthodontic tooth movement when the resistance exerted by the surrounding cortical bone is reduced via a surgical procedure. Kole called it enblock tooth movement because entire alveolar cortical segment, which is connected by softer medullary bone, including the confined teeth, moves when exposed to orthodontic forces. Other researches

showed that it is not the enbloc movement because the cut part of the cortex joins after some time and only localized high remodeling was seen in the corticotomised site. Frost<sup>3</sup> in 1981 introduced the term “Regional Acceleratory Phenomenon” (RAP). RAP was explained as a temporary stage of localized soft and hard-tissue remodeling that resulted in rebuilding of the injured sites to a normal state through recruitment of osteoclasts and osteoblasts via local intercellular mediator mechanisms involving precursors, supporting cells, blood capillaries and lymph.

Wilcko<sup>4</sup> developed a patented technique called Accelerated Osteogenic Orthodontics (AOO) or Periodontally Accelerated Osteogenic Orthodontics (PAOO). This technique is similar to conventional corticotomy except that selective decortication in the form of lines and points is performed over all of the teeth that are to be moved. In addition, a resorbable bone graft is placed over the surgical sites to augment the confining bone during tooth movement. After a healing period of one or two weeks, orthodontic tooth movement is started and then followed up using a faster rate of activation at two week intervals (fig 1). The reason for placing graft is in maxillary expansion cases or in lower incisor labial segment he found fenestrations or dehiscence, grafts would prevent this complications. Orthodontic therapy facilitated with corticotomy surgery and grafting

improved alveolar bony support and resulted in permanent alveolar process width increase.

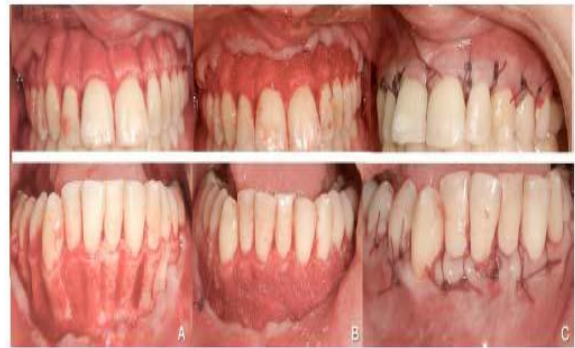

Figure 1. A full thickness mucoperiosteal flap reflected and corticotomy in the form of lines given in the interdental cortex. B. bone grafts ( decalcified freeze dried bone graft placed over corticotomy site. C. flap repositioned and sutured

### Procedure of CAOT

Full thickness mucoperiosteal flap is reflected by sulcular incision in buccal or labial and palatal side, the cut in the cortex is given in the interdental region in the form of lines or points. Cut should reach to the medullary bone, we can know that we have reach the medullary one when we see bleeding from bone during cutting. The width of the cut is 0.5 to 1mm (Fig 2). in PAOO technique graft is placed over the corticotomy site if the labial cortical plate is thin to prevent from dehiscence or fenestration. Orthodontic force can be applied after 2 weeks.

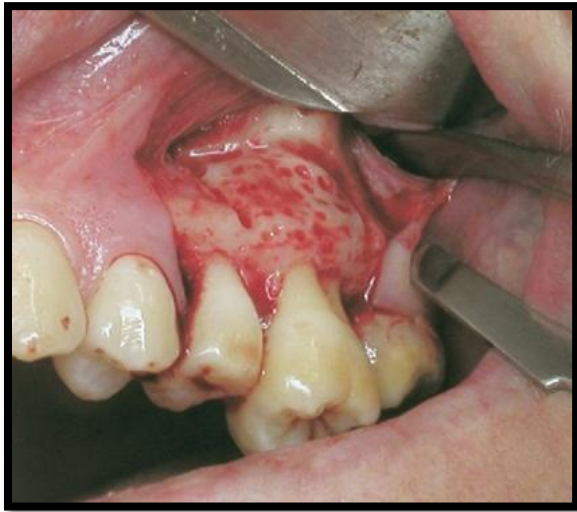

Figure 2. Corticotomy in the form of lines and points

### Advantages of CAOT

1. **Bone remodeling-** J.-D. Sebaoun<sup>5</sup> found that Selective alveolar decortication in the rat resulted in approximately a 50% increase in catabolic modeling of alveolar trabecular bone adjacent to the surgery. D.J. Ferguson et al<sup>6</sup> found that anabolic modeling of alveolar trabecular bone adjacent to the decortication site increases by about 1.5 times this increase represented a 2.6 to 3.4 fold greater anabolic modeling activity. This means that not only catabolic activity but also anabolic activity increases with corticotomy.

2. **Tooth movement-** Payam et al<sup>7</sup> found almost 2 fold amount of tooth

movement compared to cases without corticotomy. (Fig 3). They also found that velocity of tooth movement also increases with corticotomy. (Fig 4). Corticotomy decreases the lag phase of tooth movement so the velocity as well as amount of tooth movement is faster.

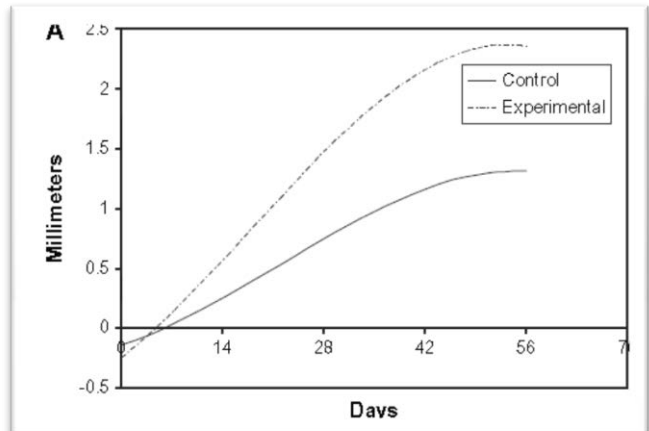


Figure 3. Average horizontal tooth movement on the control (no corticotomy) and experimental (buccal and lingual corticotomies) sides

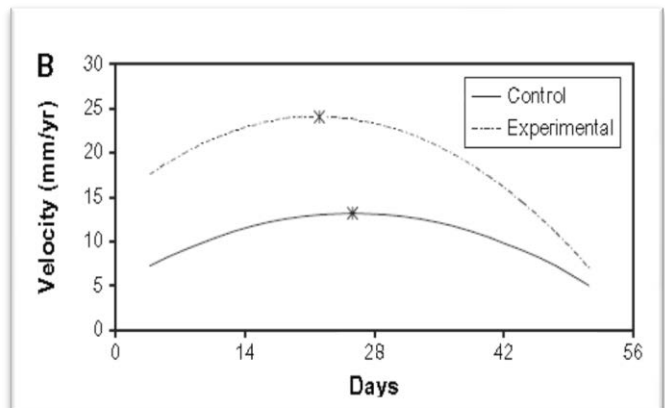


Figure 4. Average velocities of tooth movement on the control (no corticotomy) and

Experiments in dogs shows that the amount of tooth movement decreases after 6 weeks of corticotomy in dogs. Second corticotomy after 6 weeks

shows the tooth movement doesn't decrease after 6 weeks but the amount is not significant and the risks of secondsurgery it is not recommended.

### 3. Root Resorption.

Machado et al<sup>8</sup> found that Corticotomy facilitated non-extraction orthodontic therapy resulted in half as much root resorption at debanding and at long term retention than in conventional non-extraction orthodontics at debanding. The reduced treatment duration of CAOT may reduce the risk of root resorption. Renet al.<sup>9</sup> reported rapid tooth movement after corticotomy in beagles without any associated root resorption or irreversible pulp injury. Moon et al<sup>10</sup>. reported safe and sufficient maxillary molar intrusion (3.0 mm intrusion in two months) using corticotomy combined with a skeletal anchorage system with no root resorption .

### 4. Treatment time

H.S. Skountrianos<sup>11</sup> found that Corticotomy-facilitated orthodontic treatment was 66% more rapid than without surgery .Corticotomy-facilitated,non-extraction orthodontic treatment resulted in nearly the same post treatment outcome in 1/3rd the treatment time, and the outcome was more stable during retention. Hajji<sup>1</sup>found that the active orthodontic treatment periods in patients with corticotomies were 3 to 4 times more

rapid compared with patients without corticotomies.

### 5. Retention and Relapse

A.D. Nazarov<sup>12</sup>found that alveolar corticotomy-facilitated orthodontic treatment resulted in significantly greater improvements during the orthodontic retention period and a better retention outcome as judged using the ABO Objective Grading System.

### 6. Envelope of discrepancy

According to Ferguson<sup>6</sup> the envelope of discrepancy increases with corticotomy figure5.

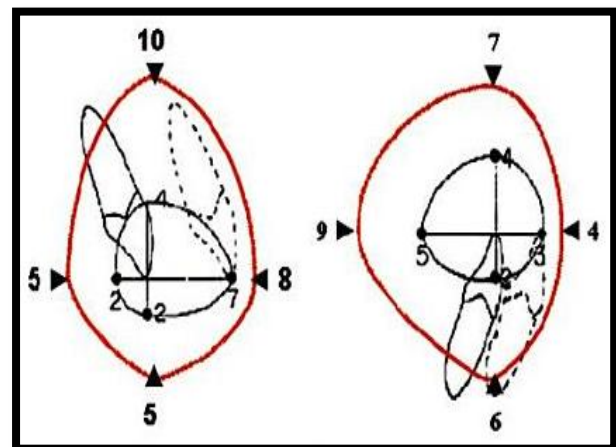


Figure 5. Inner envelope shows treatment with orthodontic treatment alone and outer envelope shows treatment after corticotomy. First figure is in sagittal and second figure in vertical plane.

## Clinical Implications

### 1. Resolve Crowding and Shorten Treatment Time

Corticomy resolves crowding in a shorter period of time, reducing the treatment time to as little as one fourth the time usually required for conventional orthodontics Wilcko<sup>1</sup> also reported a case of an adult female who was treated in only 4.5 months.

### 2. Facilitate Eruption of Impacted Teeth

According to T. J. Fischer<sup>13</sup> Corticotomy assisted impacted canines moves at a rate of 1.06 mm/month vs. 0.75 mm/month for the conventional canines. The reduction in treatment time ranged from 28% to 33%.

### 3. Molar Intrusion

Molar intrusion by 4mm was done only in in the 2.5 months with corticomomy. Yao et al<sup>10</sup> used skeletal anchorage to obtain an average of 3 to 4 mm of intrusion in 7.6 months. Sherwood et al obtained 4 mm of intrusion in 6.5 months using mini-titanium plates. Enacaret al<sup>10</sup> registered approximately 4 mm of intrusion in 8.5 months using a modified transpalatal arch.

### 4. Molar Distalisation

John V Mershon<sup>14</sup> has done molar distalisation in just 2weeks with corticomomy.

## 5. Manipulation of Anchorage

John V Merson<sup>14</sup> has shown molar distalization with segmental corticotomy around the molars, the anchorage value and resistance of the molars to distal movement is effectively reduced no any extra anterior anchorage devices required. Because corticomomy increases remodeling at the localized site only this may be the reason for increase in anchorage because anchorage also depends upon the bone density.

### Contraindications and Limitations

Patients with active periodontal disease or gingival recession and medically compromised patients are the contraindication of corticotomy.

### Complications and Side Effects

Wilcko et al<sup>1</sup> side effects and complications are, adverse effects to the periodontium after corticotomy, ranging from no problems to slight interdental bone loss and loss of attached gingival, periodontal defects, some post-operative swelling and pain is expected for several days and hematoma and facial edema in some patients

## CONCLUSION

CAOT is a promising technique that has many applications in the orthodontic treatment of adults because it helps to overcome many of the current limitations of this treatment, including lengthy duration, potential for periodontal complications, lack of

growth and the limited envelope of tooth movement.

## REFERENCES

1. *Practical advanced periodontal surgery*, Serge Dibart
2. Gantes B, Rathbun E, Anholm M. Effects on the periodontium following corticotomy-facilitated orthodontics: case reports. *J Periodontol* 1990; 61: 234-8.
3. Yaffe A, Fine N, Binderman I. Regional accelerated phenomenon in the mandible following mucoperiosteal flap surgery. *J Periodontol* 1994; 65: 79-83.
4. Wilcko MT, Wilcko WM, and Nabil F. Bissada . An evidence based analysis of periodontally accelerated orthodontic and osteogenic techniques: a synthesis of scientific perspectives. *SeminOrthod* 2008; 14: 305-16.
5. Sebaoun JD, Ferguson DJ, Kantarci A, Carvalho RS, Van Dyke TE: Catabolic modeling of trabecular bone following selective alveolar decortication. *J Dent Res* 2006.
6. Ferguson, D.J., W.M. Wilcko, and M.T. Wilcko. 2006. Selective alveolar decortication for rapid surgical-orthodontic resolution of skeletal malocclusion. In W.E. Bell and C. Guerrero, editors. *Distraction Osteogenesis of the Facial Skeleton*. BC Decker, Hamilton, Ontario, Canada.
7. Mostafa YA, Fayed MM, Mehanni S, ElBokle NN, Heider AM. Comparison of corticotomy-facilitated vs standard tooth-movement techniques in dogs with miniscrews as anchor units. *Am J OrthodDentofacialOrthop* 2009; 136: 570-7.
8. I. MACHADO, D.J. FERGUSON, M.T. WILCKO, W.M. WILCKO, and T. ALKAHADRA, *RootResorption Following Orthodontics With and Without Alveolar Corticotomy*, *Journal of Dental Research* 80:301, 2002
9. Ren A, Lv T, Zhao B, Chen Y, Bai D. Rapid orthodontic tooth movement aided by alveolar surgery in beagles. *Am J OrthodDentofacialOrthop* 2007; 131: 160.e1-10.
10. . Moon CH, Wee JU, Lee HS. Intrusion of overerupted molars by corticotomy and orthodontic skeletal anchorage. *Angle Orthod* 2007; 77: 1119-25
11. Skountrianos HS, Ferguson DJ, Wilcko WM, Wilcko MT: Maxillary arch decrowding and stability with and without corticotomy-facilitated orthodontics. *J Dent Res* 83:2643, 2004.
12. A.D. NAZAROV, D.J. FERGUSON, W.M. WILCKO, and M.T. WILCKO, *Improved Orthodontic Retention Following Corticotomy Using ABO Objective Grading System*, *Journal of Dental Research* 83:2644, 2004
13. Fischer TJ. Orthodontic treatment acceleration with corticotomy assisted exposure of palatally impacted canines. *Angle Orthod* 2007; 77: 417-20.
14. Graber vandarshall, *Current principles and technique* 5th ed.