

CONE-BEAM COMPUTED TOMOGRAPHY STUDY OF ROOT AND CANAL MORPHOLOGY OF MANDIBULAR FIRST AND SECOND PREMOLARS IN NEPALESE POPULATION

Snigdha Shubham,¹ Kriti Shrestha,¹ Sageer Ahmad,¹ Vanita Gautam,¹ Vaibhav Rai²

ABSTRACT

INTRODUCTION

Mandibular premolars are challenging to treat endodontically due to their varied root and canal morphology, impacting treatment prognosis. This study aimed to assess the root and canal morphology of mandibular premolars in a Nepali subpopulation using Cone Beam Computed Tomography (CBCT) images.

MATERIAL AND METHODS

A descriptive cross-sectional study was conducted on 348 untreated mandibular first and second premolars teeth of both right and left side having completely developed roots from 87 CBCT images of patients from September 2021-April 2024. The study assessed the number of roots, root canals, their configurations and the tooth length.

RESULTS

Significant variations in root morphology were observed in mandibular premolars, with most having one root (91.40% in first premolars, 100% in second premolars) and one canal (50% in first premolars, 70.69% in second premolars). Type I configurations were most common (50% in first premolars, 70.69% in second premolars), followed by Type V (21.26% in first premolars, 13.79% in second premolars). C-shaped canals were more frequent in first premolars (2.3%) than second premolars (1.15%).

CONCLUSION

This study provides valuable insights into root canal morphology variations of mandibular premolars in Nepalese subpopulation. The findings can help clinicians better understand importance CBCT's in anatomical variations and improve endodontic diagnosis and treatment planning for better outcomes.

KEYWORDS

Cone beam computed tomography, Configurations, Mandibular premolars, Nepalese sub-population, Root canal

1. Department of Conservative Dentistry and Endodontics, Universal College of Medical Sciences, Bhairahawa, Nepal
2. Department of Oral Medicine Diagnosis and Radiology, Universal College of Medical Sciences, Bhairahawa, Nepal

<https://doi.org/10.3126/jucms.v12i02.69493>

For Correspondence

Dr. Snigdha Shubham
Department of Conservative Dentistry and Endodontics
Universal College of Medical Sciences
Bhairahawa, Nepal.
Email: drsnigdhashubham15@gmail.com

INTRODUCTION

Dental morphology, a subject of intense scrutiny and research for over a century, has evolved into a comprehensive discipline that amalgamates genetics, embryology, and environmental factors. Mandibular premolars, often regarded as chameleons of dental anatomy, have historically presented challenges due to their unpredictable and intricate canal configurations.¹ Global research showcases vast heterogeneity in mandibular premolar root canal morphology across various ethnic and geographic groups.

The inherent complexity of mandibular premolars is not merely an academic curiosity; it holds profound clinical implications. Successful endodontic treatment relies heavily on accurate understanding of internal anatomy of the tooth. Misinterpretation of presence of extra canal, bifurcations, or other anatomical variations can lead to incomplete treatment, persistent infections, and eventually, treatment failure.²

Historically, dental professionals relied on periapical radiographs. While beneficial, 2-dimensional images often fell short in providing comprehensive view, especially for teeth with complex root and canal configurations.³

In recent years, CBCT technology has been instrumental in enhancing our understanding of dental anatomy, particularly root canal morphology, contributing significantly to advances in endodontic practice.^{4,5}

One of the critical areas of interest in endodontics is intricate anatomy of mandibular premolars, which often pose challenges during endodontic procedures due to their anatomical variations. Nepal, with its diverse population and unique genetic makeup, presents an intriguing opportunity to investigate the root and canal morphology of mandibular first and second premolars. Nepalese population's distinct genetic and environmental factors may lead to variations in dental anatomy that could have implications for endodontic treatment outcomes. Hence, comprehensive study exploring the root and canal morphology of mandibular premolars in Nepalese population through CBCT imaging is essential to better understand these anatomical variations.

This study aims to bridge the gap in existing literature by providing valuable insights into the root canal morphology of mandibular first and second premolars in Nepalese individuals. By utilizing advanced CBCT technology, this research endeavors to delineate the various anatomical configurations that may be encountered, such as number of roots, canals and other intricate details. Such knowledge is crucial for endodontists to tailor their treatment strategies, improve procedural success rates, and ultimately enhance patient care.

In addition, this study holds academic significance by contributing to global body of knowledge regarding dental anatomy and endodontic practices. The findings may serve as a foundation for future research endeavors aimed at unraveling the genetic and environmental factors influencing dental variations in different populations.

Through this study, we anticipate shedding light on the intricate root and canal morphology that characterizes this specific demograph leading to advance our understanding of dental anatomy, refine endodontic procedures, and pave the way for improved dental care tailored to the unique needs of the Nepalese population.

MATERIAL AND METHODS

A descriptive, cross-sectional study was conducted in the Department of Conservative Dentistry and Endodontics, Universal College of Medical Sciences. The CBCT images of mandibular premolars from patients who were referred from for diagnostic and treatment planning purposes, and attending the Radiology unit at the Department of Oral Medicine and Radiology were collected by convenient sampling method for a duration of 2 years (September 2021-April 2024). The study was conducted after getting the ethical clearance from the Institutional Review Committee of Universal College of Medical Sciences (UCMS/IRC/078/21).

The CBCT images were obtained using Clear rainbow™ CT (Dentium Co. Ltd, Korea) at 94 kVp, 9 mA and an exposure time of 19 sec and 5×5 FOV. The voxel size of the images was 76×76×76; and the slice thickness was 200 μm with 16 bits grayscale. An experienced radiologist performed the acquisition process according to the manufacturer's recommended protocol with the minimum exposure necessary for adequate image quality. According to human ethics procedures, all methods were carried out in accordance with relevant guidelines and regulations. All the images of mandibular premolars were evaluated with a 3D Imaging Software 3.3.9.0 (Dentium Co.Ltd, Korea).

Two endodontists independently evaluated the images twice, with a week interval between the assessments. In case of disagreement, a radiologist with endodontic experience were asked to perform a third evaluation and then reach a final consensus. All the evaluators were calibrated by analyzing 20 random cases of mandibular premolars based on the same criteria and variants. The Cohen's Kappa was used to analyze presence of anatomical variation and variation type, and the intraclass correlation coefficient (ICC) was used to analyze the roots and root canals number.

The CBCT images taken were as part of their routine examination, diagnosis and treatment planning. To obtain clear images of the mandibular premolar teeth, those teeth with physiological and/or pathological defects were excluded. Teeth were selected according to the following criteria: (i) mandibular permanent premolars with no periapical lesions; (ii) no root canal treatment; (iii) no root canals with open apices, resorption or calcification and (iv) the CBCT images of good quality. Informed consent was obtained from all participants, adhering to the principles outlined in the Declaration of Helsinki. Patient anonymity and confidentiality were strictly maintained throughout the study.

The sample size was calculated using a formula $n = Z^2pq/e^2$, where, n = sample size, z =standard deviation set at 1.96 (95% confidence level), p =prevalence of condition (87.1% prevalence of type-I configuration of first premolar according to Xuan Yu et al)⁶, $q=100-p$, e =permissible error=5%.

Hence, 87 CBCT images were taken to evaluate 348 first and second premolars. The following parameters were assessed for each mandibular premolar:

- Number of roots
- Number of canals
- Canal configuration: Classified according to the Vertucci classification system and C-shaped configuration
- Root length: Measurement from apex to coronal reference point.

The tooth length in the mesiodistal plane (maximum crown-apex distance) was measured with the linear measurement tool. A number of canals were observed by moving the coronal plane, checking them in the axial plane (Figure 1), and covering the tooth from the pulp chamber to the apex in order to confirm the observed configuration.

Vertucci's Classification⁷ was used to determine the type of root canal configuration. Vertucci's classification is as follows: type I (1), type II (2-1), type III (1-2-1), type IV (2), type V (1-2), type VI (2-1-2), type VII (1-2-1-2), and type VIII (3).

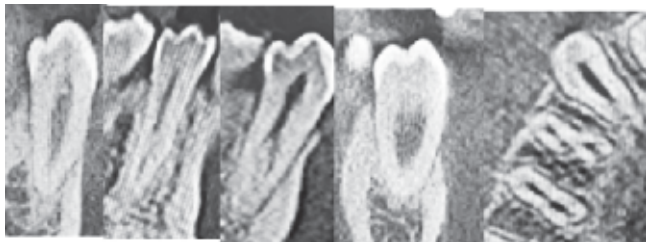


Figure 1. Root of mandibular premolars showing Vertucci's canal configuration Type II, III, V and C-shaped canal

Data were tabulated and analyzed using descriptive statistics.

RESULTS

The study cohort consisted sample size of 87 patients representing diverse population within the age groups of 18-65 years old. The gender distribution comprised 58 (66.67%) males and 29 (33.33%) females. The number of roots and canal configurations of 348 mandibular premolars (174 first premolars and 174 second premolars) were evaluated.

Number of roots and canals

Out of 174 mandibular first premolar 159 (91.40%) had one root and 15 (8.60%) had two roots; 87 (50%) had one canal, 79 (45.40%) had two canals, 4 (2.3%) had three canals and the prevalence of C-shaped canals was 2.3%. All mandibular second premolars had one root. Of these, 123 (70.69%) had one canal and 49 (28.16%) had two canals. The prevalence of C shaped canals was 2 (1.15%) (Table 1).

Root length

The mean length of the first premolars was 20.46 mm and that of second premolars was 20.31 mm.

Root canal configuration

The canal morphology of mandibular first premolars according to Vertucci's classification⁷ was as follows:

Type I = 87 (50%), Type II = 37 (21.26%), Type III = 4 (2.3%), Type IV = 16 (9.2), Type V = 16 (9.2%), Type VIII = 3 (1.72%) (Figure 1), while four teeth had C-shaped configuration (2.3%) (Table 2). All 174 mandibular second premolars were single-rooted and the canal configurations of these teeth were Type I (123 teeth, 70.69%), Type II (3 teeth, 1.72%) Type IV (24 teeth, 13.79%) and Type V (22 teeth, 12.65%); two teeth had a C-shaped configuration (1.15%) (Table 3, Figure 1).

In both first and second mandibular premolar teeth exhibiting Type V or Type VIII morphology, the canal bifurcation occurred at the middle-apical part of the roots.

Table 2. Number and percentage of canal system types in 174 single-rooted mandibular first premolars

	Root canal configuration (Vertucci classification)								
	Type I	Type II	Type III	Type IV	Type V	Type VI	Type VII	Type VIII	C Shaped
Number	87	16	4	16	37	4	3	3	4
Percentage	50%	9.2%	2.3%	9.2%	21.26%	2.3%	1.72%	1.72%	2.3%

Table 3. Number and percentage of canal system types in 174 single-rooted mandibular second premolars

	Root canal configuration (Vertucci classification)								
	Type I	Type II	Type III	Type IV	Type V	Type VI	Type VII	Type VIII	C Shaped
Number	123	3	0	22	24	0	0	0	2
Percentage	70.69%	1.72%		12.65%	13.79%				1.15%

DISCUSSION

Cone-Beam Computed Tomography (CBCT) has emerged as a revolutionary imaging modality in the field of dentistry, enabling three-dimensional visualization of dental structures with remarkable precision and detail.⁴ This technology has contributed significantly in our understanding of intricate anatomy of mandibular premolars particularly root and canal morphology, which often pose challenges during endodontic procedures due to their anatomical variations.¹

Hence, comprehensive study exploring the root and canal morphology of mandibular premolars in the Nepalese population through CBCT imaging is essential to better understand these anatomical variations.⁸⁻¹⁰ The American Association of Endodontists (AAE) and the American Academy of Oral and Maxillofacial Radiology (AAOMR) recommend using Cone Beam Computed Tomography (CBCT) in endodontics to detect abnormalities or variations when complex morphology is suspected from conventional radiographs.¹¹

The present study demonstrated mandibular significant variation of first premolars in the root canal morphologies compared to second premolar. The prevalence of single-rooted premolars was higher, with 91.40% in first premolars and 100% in second premolars, compared to double roots, which were found in 8.60% of first premolars. Similar findings have been reported in other literature as well.^{12,13} In contrast to other studies^{14,15} this research found a greater incidence of two roots in mandibular first premolars. This variation might be attributed to the differences in racial

Table 1. Numbers and percentage of roots and canals in 348 mandibular premolars according to location

	No. of roots				No. of canal							
	One rooted		Two rooted		One canal		Two canal		Three canal		C shaped	
	Right	Left	Right	Left	Right	Left	Right	Left	Right	Left	Right	Left
First Premolar	76 (87.36%)	83 (95.40%)	11 (12.64%)	4 (4.60%)	54 (62.07%)	33 (37.93%)	25 (28.73%)	54 (62.07%)	4 (4.6%)	0%	4 (4.6%)	0%
Total	159 (91.40%)		15 (8.60%)		87 (50%)		79 (45.40%)		4 (2.3%)		4 (2.3%)	
Second Premolar	87 (100%)		0	0	65 (74.70%)	58 (66.66%)	20 (23%)	29 (33.33%)	0	0	2 (2.3)	0
Total	174 (100%)	87 (100%)	0		123 (70.69%)		49 (28.16%)		0		2 (1.15%)	

backgrounds, study design and smaller sample size of this study.

This study also found a significant variation in the number of root canals between the two premolars. The mandibular first premolar exhibited a single canal in 50% of cases, consistent with findings from other studies.^{16,17} Additionally, 45.40% of samples displayed two canals, aligning with results reported in other studies.^{18,19} This suggests a possible influence of genetic and developmental factors on root and canal morphology.

The analysis based on Vertucci's classification showed Type I configurations as the most common in both first (50%) and second (70.69%) mandibular premolars which was similar to the findings of another research.^{12,20} In this study, the mandibular first premolar most commonly exhibited a type V configuration as the second most frequent (21.26%), similar to findings of another studies,²⁰ followed by type II and IV (9.2%). In the mandibular second premolar, type V was also the second most common (13.79%) consistent with the findings of previous studies,^{6,20} followed by type IV (12.65%). The result was in contrast to the study on Iranian subpopulation which showed type III configuration (11%) as the second most prevalent canal configuration.²¹ These variations can be attributed to differences in ethnicity, study methods, sample sizes, gender, and geographic distribution, which can all affect root canal configuration. Type III, VI, VII and VIII configurations were not identified in this study, consistent with findings from other similar study.²¹

In Vertucci's classification, type I and IV are relatively simple with distinct orifices and apices, while types II, III, V, VI, VII, and VIII are more complex and challenging to treat, often leading to higher failure rates.^{12,22} Clinicians should be aware of these complexities and possess the skills necessary to achieve successful outcomes.

C-shaped canal is a unique and complex root canal configuration primarily found in mandibular second molars; second most prevalent teeth for C-shaped canal is mandibular premolars.^{6,17}

In the present study, a C-shaped configuration was identified in 2.3% of first premolars, consistent with previous findings.⁶ However, it was found in 1.15% of second premolars, which is similar than reported in other studies.²³ This variation could stem from differences in racial demographics and sample sizes.

The mean root length of first and second premolars were almost identical (20.46 mm and 20.31 mm respectively) which was similar to the study⁸ but the lengths were comparatively shorter than the data available from other population like Indian, Jordan and Spanish population.^{20,24-25} This might be due to genetic factors, environmental factors and evolutionary adaptations to Nepalese diet and chewing habits over generations.

The cross-sectional design limits the study to a single time point. In addition, the study's focus is on anatomical parameters; clinical implications were not considered. The sample size may impact generalizability to the entire Nepalese population. Hence, multicentric study design with larger sample size is recommended.

CONCLUSION

The meticulous CBCT analysis, has unveiled a panorama of root and canal morphology variations within Nepalese mandibular premolars. These comprehensive findings serve as a robust foundation for the forthcoming discussions, delving into the clinical implications and broader significance within the dental realm.

CONFLICT OF INTEREST

None

REFERENCES

1. Slowey RR. Root canal anatomy. Road map to successful endodontics. Dent Clin North Am. 1979; 23:555–73.
2. Torabinejad M, Walton RE, Fouad AF. Endodontics: Principles and Practice. 5th ed. St. Louis: Elsevier; 2014.
3. Patel S. New dimensions in endodontic imaging: part 2. Cone beam computed tomography. Int Endod J 2009; 42: 463-75.
4. Scarfe WC, Levin MD, Gane D, Farman AG. Use of cone beam computed tomography in endodontics. Int J Dent. 2009; 2009:634567.

5. Matherne RP, Angelopoulos C, Kulild JC, Tira D. Use of cone-beam computed tomography to identify root canal systems in vitro. *Journal of endodontics*. 2008 Jan 1;34(1):87-9.
6. Yu X, Guo B, Li KZ, Zhang R, Tian YY, Wang H. Cone-beam computed tomography study of root and canal morphology of mandibular premolars in a western Chinese population. *BMC medical imaging*. 2012 Dec; 12:1-5.
7. Vertucci F.J. Root canal anatomy of the human permanent teeth. *Oral Surgery, Oral Medicine, Oral Pathology, Oral Radiology, and Endodontology*.1984;58(5): 589–99.
8. Shrestha R, Srii R, Shrestha D. Diversity of Root Canal Morphology in Mandibular First Premolar. *Kathmandu Univ Med J*. 2019;67(3):223-8.
9. Neelakantan P, Subbarao C, Subbarao CV. Comparative evaluation of modified canal staining and clearing technique, cone-beam computed tomography, peripheral quantitative computed tomography, spiral computed tomography, and plain and contrast medium-enhanced digital radiography in studying root canal morphology. *J Endod*. 2010;36(9):1547-51.
10. da Silva Ramos LM, Rice D, Ordinola-Zapata R, Capelozza AL, Bramante CM, Jaramillo D, Christensen H. Detection of various anatomic patterns of root canals in mandibular incisors using digital periapical radiography, 3 cone-beam computed tomographic scanners, and micro-computed tomographic imaging. *Journal of endodontics*. 2014 Jan 1;40(1):42-5.
11. Jaju PP, Jaju SP. Clinical utility of dental cone-beam computed tomography: current perspectives. *Clinical, cosmetic and investigational dentistry*. 2014 Apr 2:29-43.
12. Bantawa S, Niraula D, Dahal S, Pradhan RJ, Thapa A, Shrestha R, Agrawal SK. Assessment of root and root canal morphology of mandibular premolars using cone beam computed tomography in a tertiary center of Nepal. *Journal of Gandaki Medical College-Nepal*. 2022 Dec 31;15(2):162-7.
13. Alenezi DJ, Al Nazhan SA, Al Maflehi N, Soman C. Root and canal morphology of mandibular premolar teeth in a Kuwaiti subpopulation: A CBCT clinical study. *Eur Endod J*. 2020;5(3):248-56.
14. Alfawaz H, Alqedairi A, Al-Dahman YH, Al-Jebaly AS, Alnassar FA, Alsubait S, Allahem Z. Evaluation of root canal morphology of mandibular premolars in a Saudi population using cone beam computed tomography: A retrospective study. *The Saudi Dental Journal*. 2019 Jan 1;31(1):137-42.
15. Caliskan MK, Pehlivan Y, Sepetcioglu F, Turkun M, Tuncer SS. Root canal morphology of human permanent teeth in a Turkish population. *J Endod*. 1995;21(4):200–04.
16. Cleghorn B, Christie W, Dong C. The root and root canal morphology of the human mandibular first premolar: a literature review. *J Endod*. 2007; 33:509–16.
17. Brea, G., Gomez, F. & Gomez-Sosa, J.F. Cone-beam computed tomography evaluation of C-shaped root and canal morphology of mandibular premolars. *BMC Oral Health* 21, 236 2021.
18. Huang YD, Wu J, Sheu RJ, Chen MH, Chien DL, Huang YT, Huang CC, Chen YJ. Evaluation of the root and root canal systems of mandibular first premolars in northern Taiwanese patients using cone-beam computed tomography. *Journal of the Formosan Medical Association*. 2015 Nov 1;114(11):1129-34.
19. Yang H, Tian C, Li G, Yang L, Han X, Wang Y. A cone-beam computed tomography study of the root canal morphology of mandibular first premolars and the location of root canal orifices and apical foramina in a Chinese subpopulation. *J Endod*. 2013; 39:435–8.
20. Shetty A, Hegde MN, Tahiliani D, Shetty H, Bhat GT, Shetty S. A three-dimensional study of variations in root canal morphology using cone-beam computed tomography of mandibular premolars in a south Indian population. *J Clin Diagn Res*. 2014;8(8): ZC22–ZC24.
21. Hajihassani N, Roohi N, Madadi K, Bakhshi M, Tofanghiha M. Evaluation of root canal morphology of mandibular first and second premolars using cone beam computed tomography in a defined group of dental patients in Iran. *Scientifica*. 2017;2017(1):1504341.
22. Cleghorn B, Christie W, Dong C. The root and root canal morphology of the human mandibular first premolar: a literature review. *J Endod*. 2007; 33:509–16.
23. Kim Y, Lee SJ, Woo J. Morphology of mandibular premolars analyzed by cone-beam computed tomography in a Korean population: Variations in number of roots and canals and the incidence of C-shaped canals. *BMC Oral Health*. 2013;14(1):1-8.
24. Llena C, Fernandez J, Ortolani PS, Forner L. Cone-beam computed tomography analysis of root and canal morphology of mandibular premolars in a Spanish population. *Imaging Science in Dentistry*. 2014 Sep 1;44(3):221-7.
25. Awawdeh LA, Al-Qudah AA. Root form and canal morphology of mandibular premolars in a Jordanian population. *International endodontic journal*. 2008 Mar;41(3):240-8.